This is a digital copy of a book that was preserved for generations on library shelves before it was carefully scanned by Google as part of a project to make the world's books discoverable online.

It has survived long enough for the copyright to expire and the book to enter the public domain. A public domain book is one that was never subject to copyright or whose legal copyright term has expired. Whether a book is in the public domain may vary country to country. Public domain books are our gateways to the past, representing a wealth of history, culture and knowledge that's often difficult to discover.

Marks, notations and other marginalia present in the original volume will appear in this file - a reminder of this book's long journey from the publisher to a library and finally to you.

Usage guidelines

Google is proud to partner with libraries to digitize public domain materials and make them widely accessible. Public domain books belong to the public and we are merely their custodians. Nevertheless, this work is expensive, so in order to keep providing this resource, we have taken steps to prevent abuse by commercial parties, including placing technical restrictions on automated querying.

We also ask that you:

+ *Make non-commercial use of the files* We designed Google Book Search for use by individuals, and we request that you use these files for personal, non-commercial purposes.

+ *Refrain from automated querying* Do not send automated queries of any sort to Google's system: If you are conducting research on machine translation, optical character recognition or other areas where access to a large amount of text is helpful, please contact us. We encourage the use of public domain materials for these purposes and may be able to help.

+ *Maintain attribution* The Google "watermark" you see on each file is essential for informing people about this project and helping them find additional materials through Google Book Search. Please do not remove it.

+ *Keep it legal* Whatever your use, remember that you are responsible for ensuring that what you are doing is legal. Do not assume that just because we believe a book is in the public domain for users in the United States, that the work is also in the public domain for users in other countries. Whether a book is still in copyright varies from country to country, and we can't offer guidance on whether any specific use of any specific book is allowed. Please do not assume that a book's appearance in Google Book Search means it can be used in any manner anywhere in the world. Copyright infringement liability can be quite severe.

About Google Book Search

Google's mission is to organize the world's information and to make it universally accessible and useful. Google Book Search helps readers discover the world's books while helping authors and publishers reach new audiences. You can search through the full text of this book on the web at `http://books.google.com/`

A 3 9015 00380 096 1
University of Michigan – BUHR

ARTES
SCIENTIA
VERITAS
LIBRARY OF THE
UNIVERSITY OF MICHIGAN
E PLURIBUS UNUM
SI QUAERIS PENINSULAM AMOENAM
CIRCUMSPICE

610.5
C64
S6

1837
ARTES
SCIENTIA
VERITAS
LIBRARY OF THE
UNIVERSITY OF MICHIGAN
E PLURIBUS UNUM
SI QUAERIS PENINSULAM AMOENAM
CIRCUMSPICE

C6
S6

TRANSACTIONS

OF

THE CLINICAL SOCIETY.

VOL. XXXIX.

TRANSACTIONS

OF

THE CLINICAL SOCIETY

OF

LONDON.

VOLUME THE THIRTY-NINTH.

LONDON:
LONGMANS, GREEN, AND CO.
1906.

PRINTED BY ADLARD AND SON, LONDON AND DORKING.

NOTICE.

THE present Volume comprises the Proceedings of the Society during its Thirty-ninth Session, October, 1905, to May, 1906.

The Council think it proper to state that the authors of the several communications are alone responsible for the statements, reasonings, and opinions contained in their respective papers.

20, HANOVER SQUARE, W.;
October 12th, 1906.

228208

CONTENTS.

PAGE

NOTICE FROM THE COUNCIL v

LIST OF ILLUSTRATIONS xvii

LIST OF OFFICERS AND MEMBERS OF THE COUNCIL DURING 1906–7 xix

LIST OF PRESIDENTS OF THE SOCIETY FROM ITS FORMATION . xx

LIST OF HONORARY MEMBERS OF THE SOCIETY . . . xxi

LIST OF MEMBERS OF THE SOCIETY xxiii

REPORT OF THE COUNCIL li

TREASURER'S STATEMENT OF RECEIPTS AND PAYMENTS . lii

PAPERS READ:

I. THE CYSTOSCOPE IN DIAGNOSES OF DISEASES OF THE BLADDER AND KIDNEYS. LESIONS ILLUSTRATED BY AN OPAQUE PROJECTOR. By DAVID NEWMAN, M.D., F.F.P.S.G.Glasgow . . 1

II. A CASE OF TUBERCULOSIS IN A DIVERTICULUM OF THE BLADDER FOUND IN AN INGUINAL HERNIA. By EDRED M. CORNER, M.B., B.C., F.R.C.S., and CECIL W. ROWNTREE, M.B., B.S., F.R.C.S. 21

PAGE

III. The After-History and Post-Mortem Record of a Case of Cardiac Syphiloma with Bradycardia and Obstruction of the Inferior Vena Cava. By Charles W. Chapman, M.D. 26

IV. Case of Suppurative Pylephlebitis associated with Suppurating Mesenteric Gland. By Francis H. Hawkins, M.D. . 30

V. A Successful Case of Splenectomy for Rupture of the Spleen, with Remarks on the Diagnosis and Treatment of this Accident. By Graham Simpson, F.R.C.S. . . . 33

VI. A Case in which the Pleura contained several Pints of Calcareous, Mortar-like Fluid. By Samuel West, M.D. . . . 42

VII. Periodic Respiration. By Samuel West, M.D. 46

VIII. On a Case of Relapsing Tetany associated with Dilatation of the Sigmoid Flexure. By F. Langmead, M.D. 48

IX. The Present Position of the Treatment of Congenital Dislocation of the Hip-Joint, illustrated by an Account of the Results in two Series, each of ten Consecutive Cases. By J. Jackson Clarke, M.B.Lond. . 53

X. A Case of Typhoid Fever, with Peritonitis but no Perforation, in which Laparotomy was Performed. By E. W. Goodall, M.D. . 55

PAGE

XI. Septic Peritonitis occurring early in the Course of Typhoid Fever apart from Perforation (with a Temperature Chart). By W. G. Spencer, M.S. 59

XII. A Case of Traumatic Pancreatic Pseudo-Cyst. By Thos. H. Kellock, F.R.C.S. . . 63

XIII. Transverse *versus* Iliac Colotomy, with Notes of Three Cases. By Lawrie McGavin, F.R.C.S.Eng. 69

XIV. Further Cases of Torsion of the Omentum. By H. Irving Pinches, M.A., M.B., B.C. (Cantab.), and Edred M. Corner, M.B., F.R.C.S., etc. 79

XV. A Review of 59 Cases of Cancer of the Stomach treated by Operation. By B. G. A. Moynihan, M.S., F.R.C.S. 84

XVI. Stricture of the Small Intestine causing Acute Intestinal Obstruction. By James Sherren, F.R.C.S. 96

XVII. A Case of Strangulated Left Duodenal Hernia. By James Sherren, F.R.C.S. . 98

XVIII. A Case of Volvulus of the Cæcum. By James Sherren, F.R.C.S. 100

XIX. Two Cases of Appendicitis due to Oxyuris Vermicularis. By H. W. Carson, F.R.C.S. 102

XX. A Case of Appendix Abscess with Profuse Hæmorrhages; Recovery. By John D. Malcolm, F.R.C.S. 108

PAGE

XXI. A Note upon the Relation of Traumatic Diabetes Insipidus to Glycosuria. By Herbert French, M.D., and C. B. Ticehurst, B.A. 117

XXII. A Case of Post-Traumatic Hæmorrhage from the Superior Longitudinal Sinus without Fracture of the Skull; Operation and Recovery. By E. Farquhar Buzzard, M.D., and Joseph Cunning, F.R.C.S. . . . 123

XXIII. An Unusual Case of Dilatation of the Stomach following Hour-Glass Contraction. By John Evan Spicer, M.B. . . 127

XXIV. A Case of Associated Congenital Malformations, including Transposition of Viscera. By A. E. Garrod, M.D., and F. Langmead, M.D. 131

XXV. Treitz's Hernia complicating Gastro-Enterostomy. By Arthur E. Barker, F.R.C.S. 136

XXVI. A Case of Right Duodenal Hernia in which the Hernia was reduced but Death followed in Seven Days, due apparently to Gut re-entering the Sac. By E. Percy Paton, M.S., F.R.C.S. 139

XXVII. Large Cyst of Common Bile-Duct. By Frederic Eve, F.R.C.S. 144

XXVIII. Three Cases of Gastro-Jejunostomy. By F. C. Wallis, M.B., B.C., F.R.C.S. . . 151

PAGE

XXIX. A Case of Cystic Tumour of the Spermatic Cord. By Cuthbert Wallace, M.B., B.S., F.R.C.S. 157

XXX. Carcinoma of the Thyroid Gland. By A. C. Hudson, M.D., F.R.C.S. 164

XXXI. A Case of Perforated Gastric Ulcer treated by Evisceration and Irrigation. Recovery. By E. W. Roughton, M.D., B.S., F.R.C.S. . 173

XXXII. A Case of Complete Removal of a Multilocular Cystic Tumour of the Pancreas; Colo-colic Anastomosis sixteen days later; Recovery. By John D. Malcolm, F.R.C.S. Edin. 175

XXXIII. Case of Thrombosis of the Abdominal Aorta. By Francis H. Hawkins, M.D. . . . 185

XXXIV. A Series of Cases in which Pulmonary Embolism appeared to be due to the Displacement of a Thrombus in the Main Trunk of the Pulmonary Artery. By Charles R. Box, M.D. 189

XXXV. Acute Dilatation (Acute Atony) of the Stomach and Intestines connected with Pneumonia and Pleuro-pericarditis. By F. Parkes Weber, M.D., F.R.C.P. . . . 205

Clinical Cases Exhibited:

I. Case of Mediastinal Dermoid. By G. E. O. Williams 210

PAGE

II. Three Cases of Submucous Excision of Deviations and Spurs in the Nasal Septum. By StClair Thomson, M.D. 211

III. Cases of Recovery, without Spinal Symptoms, after Severe Injury to the Neck. By Edred M. Corner, B.C. 212

IV. Stokes-Adams Disease. By R. O. Moon, M.D. 214

V. A Japanese Infant, showing the Congenital Pigmentation of Mongolians. By G. A. Sutherland, M.D. 214

VI. Cases of Lupus becoming Epithelioma after repeated Surgical and prolonged X-ray Treatment. By W. G. Spencer, M.S. . . 215

VII. Peculiar Pigmentation of the Skin in an Infant. By A. E. Garrod, M.D. . . . 216

VIII. Epithelioma of the Lip in a Man of Forty-four Years of Age. By Lawrie McGavin . 216

IX. Rodent Ulcer of the Scalp, Face, and Inner Canthus of the Eyelid; treated by the application of X Rays. By Lawrie McGavin 217

X. Multiple Lipomas. By H. D. Rolleston, M.D. 218

XI. A Case of General Paralysis of the Insane in a boy æt. 16 (?). By John R. Lunn . 219

XII. A Case of Myasthenia Gravis (?). By John R. Lunn 219

PAGE

XIII. A Case of Molluscum Fibrosum. By John R. Lunn 220

XIV. A Case of Laminectomy for Traumatic Paraplegia. By Lawrie McGavin . . . 221

XV. Congenital Aperture in the Centre of the Palate. By James Berry, B.S. . . . 222

XVI. Case of Shaking Head or Spasmus Nutans. By C. H. Thompson, M.D. 223

XVII. A Case of Amyotrophic Lateral Sclerosis. By J. Walter Carr, M.D. 224

XVIII. A Case of Transverse Myelitis, with Loss of Knee-jerks; Recovery. By W. P. Herringham, M.D. 225

XIX. Charcot's Disease of the Thumb. By P. Maynard Heath, B.S. 225

XX. Case of Sudden Paralysis of the third Cranial Nerve. By Bertram Abrahams, M.B. 227

XXI. A Case of Bilateral Deformity of the Neck of the Femur. By Rupert Bucknall, M.S. 228

XXII. Case of Osteo-sarcoma of Frontal Bone. By Thomas H. Kellock, B.C. . . . 228

XXIII. Tetany of seven months' duration associated with Gastro-intestinal Disorder in a girl æt. 9 years, apparently cured by the use of Thyroid Substance. By H. T. Mant, M.B., and H. Batty Shaw, M.D. . 229

PAGE

XXIV. Plexiform Angioma of the Hand and Arm. By Hugh M. Rigby, M.S. 230

XXV. Cavernous Nævus of the Tongue. By Hugh M. Rigby, M.S. 230

XXVI. Perforating Ulcers and Joint Changes with only slight Sensory Changes. By C. E. Beevor, M.D. 231

XXVII. Mediastinal Sarcoma which disappeared after treatment by the Röntgen Rays. By J. P. zum Busch, M.D. 232

XXVIII. Bony Tumour of Skull. By H. G. Turney, M.D. 235

XXIX. Case of Sudden Paralysis of the Third Cranial Nerve. By Bertram Abrahams, M.B. 236

XXX. Case of Adiposis Dolorosa. By Bertram Abrahams, M.B. 237

XXXI. Dislocation of Metatarsus. By Cyril A. R. Nitch, M.S. 237

XXXII. Dislocation of the Metatarsus. By John J. Douglas, M.D. 238

XXXIII. Case four Years after Fixation of Omentum for Ascites. By W. G. Spencer, M.S. . 239

XXXIV. Sporadic Case of Friedreich's Disease. By J. G. Gibb. 239

PAGE

XXXV. Spleno-Medullary Leukæmia (Myelæmia) in a Boy æt. 10½. By Arthur Voelcker, M.D. 240

XXXVI. Functional Hemiplegia (? Disseminated Sclerosis) in a Boy æt. $9\frac{8}{12}$. By Arthur Voelcker, M.D. 241

XXXVII. A Case of Congenital Absence of the Fibula and Malformation of the Head of the Femur (Congenital Coxa Vara) simulating Congenital Dislocation of the Hip. By T. H. Openshaw, C.M.G. 241

XXXVIII. A Case of Double Coxa Vara (Ricketic) in a Boy æt. 12. By T. H. Openshaw, C.M.G. . 243

XXXIX. A Case of Left Traumatic Coxa Vara due to an Extra-capsular Fracture of the Neck of the Femur in a Boy æt. 12. By T. H. Openshaw, C.M.G. 244

XL. Case of (?) von Recklinghausen's Disease. By G. A. Sutherland, M.D. 245

XLI. "Spontaneous" Fracture in the Tarsus in a Woman with Argyll-Robertson Pupils. By F. Parkes Weber, M.D. 246

XLII. Case of Ringworm cured by the Exposure of X Rays. By G. Pernet 247

XLIII. Lymphangiectodes. By G. Pernet . . . 247

XLIV. A Case of Post-Auricular Fistula. By W. H. Battle 248

PAGE

XLV. Extensive Ulceration invading the Upper Jaw on both sides, with Partial Destruction of Alveolar Margin, and without Involvement of the Cheek. By William Hy. Battle 249

XLVI. A Patient after Operation for Perforation of a Second Simple Ulcer of the Jejunum into the General Peritoneal Cavity. By William Hy. Battle 250

XLVII. Deformity of the Ulna, with Dislocation of the Head of the Radius associated with Multiple Osteomata. By William Hy. Battle 252

XLVIII. Extreme Obesity with Precocious Puberty in a Girl æt. 3. By Leonard Guthrie, M.D. 252

XLIX. Muscular Atrophy in a Child (case for Diagnosis). By A. E. Garrod, M.D. . . 254

L. A Case of Angeio-Neurotic Œdema. By A. E. Garrod, M.D. 255

LI. Paralysis of Left Sixth and Paresis of Left Seventh Nerves. By Leonard Guthrie, M.D. 256

LII. Fracture of the Neck of the Femur. By C. J. Symonds, M.S. 257

LIST OF ILLUSTRATIONS.

PLATES.

TO FACE PAGE

PLATES I—III. ILLUSTRATING DR. DAVID NEWMAN'S PAPER ON THE CYSTOSCOPE IN DIAGNOSES OF DISEASES OF THE BLADDER AND KIDNEYS 8, 12, 14

PLATE IV. ILLUSTRATING DR. LANGMEAD'S CASE OF RELAPSING TETANY ASSOCIATED WITH DILATATION OF THE SIGMOID FLEXURE 48

PLATES V, VI. ILLUSTRATING MR. J. JACKSON CLARKE'S PAPER ON THE PRESENT POSITION OF THE TREATMENT OF CONGENITAL DISLOCATION OF THE HIP-JOINT . 53, 54

PLATE VII. ILLUSTRATING MR. FREDERIC EVE'S CASE OF LARGE CYST OF COMMON BILE-DUCT 146

PLATE VIII. ILLUSTRATING DR. GARROD'S CASE OF PECULIAR PIGMENTATION OF THE SKIN IN AN INFANT . . . 216

PLATE IX. ILLUSTRATING MR. NITCH'S CASE OF DISLOCATION OF THE METATARSUS 238

PLATE X. ILLUSTRATING MR. OPENSHAW'S CASE OF CONGENITAL ABSENCE OF THE FIBULA AND MALFORMATION OF THE HEAD OF THE FEMUR (CONGENITAL COXA VARA), SIMULATING CONGENITAL DISLOCATION OF THE HIP . 242

PLATE XI. ILLUSTRATING MR. OPENSHAW'S CASE OF DOUBLE COXA VARA (RICKETIC) IN A BOY ÆT. 12 . . . 243

PLATE XII. ILLUSTRATING DR. PARKES WEBER'S CASE OF "SPONTANEOUS" FRACTURE IN THE TARSUS IN A WOMAN WITH ARGYLL-ROBERTSON PUPILS 246

ILLUSTRATIONS IN TEXT.

PAGE

FIGS. 1–5. ILLUSTRATING DR. DAVID NEWMAN'S PAPER ON THE CYSTOSCOPE IN DIAGNOSES OF DISEASES OF THE BLADDER AND KIDNEY 2–6

FIG. 6. ILLUSTRATING DR. SAMUEL WEST'S COMMUNICATION ON PERIODIC RESPIRATION 47

FIG. 7. ILLUSTRATING DR. F. LANGMEAD'S CASE OF RELAPSING TETANY ASSOCIATED WITH DILATATION OF THE SIGMOID FLEXURE 49

CHART ILLUSTRATING MR. WALTER SPENCER'S PAPER ON SEPTIC PERITONITIS EARLY IN TYPHOID FEVER . . 61

FIG. 8. ILLUSTRATING MR. H. IRVING PINCHES AND MR. EDRED M. CORNER'S CASES OF TORSION OF THE OMENTUM 80

FIGS. 9, 10. ILLUSTRATING MR. JOHN EVAN SPICER'S CASE OF DILATATION OF THE STOMACH FOLLOWING HOUR-GLASS CONTRACTION 128, 129

FIG. 11. ILLUSTRATING DR. A. E. GARROD'S AND DR. F. LANGMEAD'S CASE OF ASSOCIATED CONGENITAL MALFORMATIONS, INCLUDING TRANSPOSITION OF VISCERA . 132

FIG. 12. ILLUSTRATING MR. A. E. BARKER'S PAPER ON TREITZ'S HERNIA COMPLICATING GASTRO-ENTEROSTOMY 137

FIGS. 13, 14. ILLUSTRATING MR. E. PERCY PATON'S CASE OF RIGHT DUODENAL HERNIA 140, 142

FIG. 15. ILLUSTRATING MR. FREDERIC EVE'S CASE OF LARGE CYST OF COMMON BILE DUCT 147

FIGS. 16–20. ILLUSTRATING MR. F. C. WALLIS'S CASES OF GASTRO-JEJUNOSTOMY 152–155

FIG. 21. ILLUSTRATING MR. A. C. HUDSON'S CASE OF CARCINOMA OF THE THYROID GLAND 167

FIG. 22. ILLUSTRATING MR. J. D. MALCOLM'S CASE OF REMOVAL OF A CYSTIC TUMOUR OF THE PANCREAS . 177

CHART ILLUSTRATING DR. F. PARKES WEBER'S CASE OF ACUTE DILATATION (ACUTE ATONY) OF THE STOMACH AND INTESTINES CONNECTED WITH PNEUMONIA AND PERICARDITIS 205

FIG. 23. ILLUSTRATING MR. JAMES BERRY'S CASE OF CONGENITAL APERTURE IN THE CENTRE OF THE PALATE . 222

FIG. 24. ILLUSTRATING MR. P. MAYNARD HEATH'S CASE OF CHARCOT'S DISEASE OF THE THUMB 226

FIG. 25. ILLUSTRATING DR. G. A. SUTHERLAND'S CASE OF (?) VON RECKLINGHAUSEN'S DISEASE 245

FIG. 26. ILLUSTRATING DR. LEONARD GUTHRIE'S CASE OF EXTREME OBESITY WITH PRECOCIOUS PUBERTY IN A GIRL 253

CLINICAL SOCIETY OF LONDON.

OFFICERS AND COUNCIL

ELECTED AT

THE GENERAL MEETING, MAY 25, 1906.

PRESIDENT.

HENRY HUGH CLUTTON, M.C.

VICE-PRESIDENTS.

CLINTON T. DENT, M.C.
WILLIAM EWART, M.D.
JOHN R. LUNN.
G. H. MAKINS, C.B.
WILLIAM PASTEUR, M.D.
C. J. SYMONDS, M.S.
WILLIAM HALE WHITE, M.D.

TREASURER.

G. H. MAKINS, C.B.

COUNCIL.

ANTHONY A. BOWLBY, C.M.G.
W. H. B. BROOK, M.D.
HARRY CAMPBELL, M.D.
ALBERT CARLESS, M.S.
NORMAN DALTON, M.D.
H. MORLEY FLETCHER, M.D.
SIR ALFRED FRIPP, C.B., M.V.O., M.S.
E. W. GOODALL, M.D.
L. G. GUTHRIE, M.D.
J. ERNEST LANE.
B. G. A. MOYNIHAN, M.S.
T. H. OPENSHAW, C.M.G., M.S.
F. J. SMITH, M.D.
F. J. STEWARD, M.S.
G. A. SUTHERLAND, M.D.
H. H. TOOTH, C.M.G., M.D.
A. H. TUBBY, M.S.
H. G. TURNEY, M.D.
H. F. WATERHOUSE, C.M.
CLAUDE WILSON, M.D.

HONORARY SECRETARIES.

W. G. SPENCER, M.S., M.B.
ARCHIBALD E. GARROD, M.D.

TRUSTEES.

JOHN HAMMOND MORGAN, C.V.O.
CHARTERS JAMES SYMONDS, M.S.
J. K. FOWLER, M.D.

PRESIDENTS OF THE SOCIETY

(*From its Formation*).

ELECTED

1867 SIR THOMAS WATSON, BART., M.D., D.C.L., LL.D., F.R.S.

1869 SIR JAMES PAGET, BART., D.C.L., LL.D., F.R.S.

1871 SIR WILLIAM WITHEY GULL, BART., M.D., D.C.L., F.R.S.

1873 SIR PRESCOTT GARDNER HEWETT, BART., F.R.S.

1875 SIR WILLIAM JENNER, BART., M.D., K.G.C.B., D.C.L., F.R.S.

1877 GEORGE WILLIAM CALLENDER, F.R.S.

1879 EDWARD HEADLAM GREENHOW, M.D., F.R.S.

1881 SIR JOSEPH LISTER, BART. D.C.L., LL.D., F.R.S. [RIGHT HON. LORD LISTER].

1883 SIR ANDREW CLARK, BART., M.D., LL.D., F.R.S.

1885 THOMAS BRYANT.

1887 SIR WILLIAM HENRY BROADBENT, BART., M.D., F.R.S.

1889 CHRISTOPHER HEATH.

1891 SIR DYCE DUCKWORTH, M.D., LL.D.

1893 JOHN WHITAKER HULKE, F.R.S.

1895 THOMAS BUZZARD, M.D.

1897 JOHN LANGTON.

1899 SIR RICHARD DOUGLAS POWELL, BART., K.C.V.O., M.D.

1901 HOWARD MARSH.

1903 FREDERICK TAYLOR, M.D.

1905 HENRY HUGH CLUTTON, M.C.

HONORARY MEMBERS.

ELECTED

1889 GAIRDNER, SIR WILLIAM TENNANT, K.C.B., M.D., LL.D., F.R.S., 32, George Square, Edinburgh.

1902 HOLMES, TIMOTHY, M.A.Cantab., F.R.C.S., Treasurer of, and Consulting Surgeon to, St. George's Hospital, 6, Sussex Place, Hyde Park, W. (C. 1867-9. V.-P. 1873-5.) *Trans.* 16.

1889 LISTER, The Right Hon. LORD, P.C., O.M., D.C.L., LL.D., F.R.S., 12, Park Crescent, W. (P. 1881–2.)

1902 OSLER, WILLIAM, M.D., F.R.C.P., F.R.S., Regius Professor of Medicine, University of Oxford, 7, Norham Gardens, Oxford.

1904 SMITH, SIR THOMAS, Bart., K.C.V.O., 5, Stratford Place, W. (C. 1869–71. V.-P. 1880-82.) *Trans.* 14.

1895 WILKS, SIR SAMUEL, Bart., M.D., LL.D., F.R.S., F.R.C.P., Consulting Physician to Guy's Hospital, 8, Prince Arthur Road, Hampstead, N.W.

FOREIGN HONORARY MEMBERS.

ELECTED

1881 BILLINGS, JOHN S., M.D., D.C.L.Oxon., Brevet Lieut.-Col. and Surgeon U.S. Army; Director of the Public Libraries of New York, New York City, U.S.A.

1902 ERB, WILHELM HEINRICH, M.D., Director of the Medical Clinic, Heidelberg.

1881 VON ESMARCH, FRIEDRICH, M.D., Professor of Surgery and Director of the Surgical Clinic in the University of Kiel.

1902 KEEN, WILLIAM WILLIAMS, A.M., M.D., LL.D., F.R.C.S.Eng.(Hon.), 1729, Chestnut Street, Philadelphia, U.S.A.

1895 KOCHER, Dr. THEODOR, Professor of Surgery in the University of Berne.

1902 VON LEYDEN, ERNST, M.D., Professor of Medicine in the University of Berlin, Bendlerstrasse 30, Berlin, W.

1895 LUCAS-CHAMPIONNIÈRE, Dr. JUST, Surgeon to the St. Louis Hospital, Paris.

1881 MAZZONI, COSTANZO, Professor of Surgery at the Royal University of Rome, and Surgeon to the Hospital of San Giacomo at Rome.

1889 MITCHELL, SILAS WEIR, M.D., LL.D., 1524, Walnut Street, Philadelphia.

*** *Members are requested to inform the Secretaries of any Corrections when necessary.*

LIST OF MEMBERS.

(O.M.) *Original Member.*
(P.) *President.*
(V.P.) *Vice-President.*
(T.) *Treasurer.*
(S.) *Secretary.*
(C.) *Member of Council.*

The Surnames of Members who have compounded for their Subscriptions are printed in this type (TYPE). *The Surnames of Members who have paid the Composition Fee for the 'Transactions' are printed in this type* (Type). *The figures succeeding the word* Trans. *show the number of Papers contributed to the 'Transactions.'* C.C. *refers to the Clinical Cases exhibited.*

ELECTED

1896 ABRAHAMS, BERTRAM LOUIS, M.B., B.Sc., 14, Welbeck Street, W. *Trans.* 2, *C.C.* 6.

1895 ACKERLEY, RICHARD, Croft House, The Hill, Surbiton.

1889 ACLAND, THEODORE DYKE, M.D., 19, Bryanston Square, W. *Trans.* 1.

1883 ADAMS, WILLIAM COODE, M.B., 1, Eton Avenue, South Hampstead, N.W.

1888 ADDINSELL, AUGUSTUS W., M.B., C.M., 7, Upper Brook Street, W.

1904 ADDISON, OSWALD LACY, M.B., Hospital for Sick Children, Great Ormond Street, W.C.

1884 ADENEY, EDWIN LEONARD, M.D., 3, Sion Terrace, Mount Sion, Tunbridge Wells.

1883 ALLCHIN, WILLIAM HENRY, M.D., 5, Chandos Street, W. (C. 1894–7.)

1888 ANDERSON, JOHN, C.I.E., M.D., 9, Harley Street, W.

1868 ANDERSON, JOHN FORD, M.D., 41, Belsize Park, N.W. (C. 1897–8.)

1899 ANDREWS, EDWARD COLLINGWOOD, M.D., 110, Finchley Road, N.W.

1905 ARKWRIGHT, JOSEPH ARTHUR, M.D., B.C., 13, Welbeck Street, Cavendish Square, W.

1902 ARMOUR, DONALD JOHN, M.B., 89, Harley Street, W. *C.C.* 1.

1885 ARMSTRONG, HENRY GEORGE, Wellington College, Berkshire.

1888 ARMSTRONG, HUGH, Tamworth, New South Wales.

O.M. ARNOTT, HENRY, The Rectory, 32, High Street, Beckenham, Kent. (C. 1871–5.) *Trans.* 3.

1903 ATKINSON, THOMAS REUELL, M.D., Chadwell Heath, Essex.

1894 ATTLEE, JOHN, M.D., B.C., 58, Brook Street, W. *C.C.* 1.

1898 AVERY, LEONARD, 29, Chester Street, Grosvenor Place, S.W.

1905 BAILEY, WILLIAM HENRY, M.D., Featherstone Hall, Southall.

1880 BAKER, HENRY FRANCIS, 2, Mandeville Place, Manchester Square, W.

ELECTED

1895 BALDWIN, GERALD R., 166, Victoria Street, Melbourne, Australia. *Trans.* 1.

1883 BALLANCE, CHARLES ALFRED, M.B., M.S., 106, Harley Street, W. (C. 1894–6.) *Trans.* 3, *C.C.* 5.

1904 BALLANCE, H. A., 46, Prince of Wales Road, Norwich.

1888 BANHAM, HENRY FRENCH, M.D., Assington Vicarage, Colchester.

1868 BANTOCK, GEORGE GRANVILLE, M.D., 14, Upper Hamilton Terrace, N.W.

1876 BARKER, ARTHUR E. J., 87, Harley Street, W. (C. 1883–5, V.P. 1901–3.) *Trans.* 19, *C.C.* 13.

1882 BARKER, FREDERICK CHARLES, M.D., Surgeon-Major, Bombay Medical Service, India.

1894 BARLING, HARRY GILBERT, 87, Cornwall Street, Newhall Street, Birmingham. (C. 1901–3.) *Trans.* 3.

1875 BARLOW, SIR THOMAS, Bart., K.C.V.O., M.D., 10, Wimpole Street, W. (C. 1880–2, 1891–4, S. 1888–90, V.P. 1895–8.) *Trans.* 11, *C.C.* 5.

1902 BARNARD, HAROLD L., 21, Wimpole Street, Cavendish Square, W. *Trans.* 2, *C.C.* 7.

1888 BARRS, A. G., M.D., 22, Park Place, Leeds.

1888 BARTON, EDWIN A., 56, Kensington Court, Kensington, W.

1891 BARTON, J. KINGSTON, 14, Ashburn Place, Courtfield Road, S.W. (C. 1901–4.)

1901 BARWELL, HAROLD SHUTTLEWORTH, 55, Wimpole Street, Cavendish Square, W.

O.M. BARWELL, RICHARD, 55, Wimpole Street, Cavendish Square, W. (C. 1872–5, V.P. 1877–9.) *Trans.* 21, *C.C.* 2.

O.M. **BASTIAN**, HENRY CHARLTON, M.D., F.R.S., 8A, Manchester Square, W. (C. 1876–8, V.P. 1891–3.) *Trans.* 7.

1896 BATTEN, FREDERICK E., M.D., 33, Harley Street, W. (C. 1903–6.) *Trans.* 5, *C.C.* 8.

1899 BATTEN, RAYNER DERBY, M.D., B.S., 33, Harley Street, W. *C.C.* 1.

1888 BATTERHAM, JOHN WILLIAMS, M.B., B.S., Bank House, Grand Parade, St. Leonard's.

1886 BATTLE, WILLIAM HENRY, 49, Harley Street, W. (C. 1899–1902.) *Trans.* 7, *C.C.* 19.

1868 BÄUMLER, CHRISTIAN G. H., M.D., The University, Freiburg i/Br., Baden, Germany. *Trans.* 4.

1903 BEAUMONT, EDGAR, "Claremont," Gipsy Hill, Upper Norwood, S.E. *C.C.* 2.

1898 BEDDARD, ARTHUR PHILIP, M.D., 44, Seymour Street, Portman Square, W.

1880 **BEEVOR**, CHARLES EDWARD, M.D., 135, Harley Street, W. (C. 1890–1.) *Trans.* 2, *C.C.* 10.

1901 BEEVOR, SIR HUGH REEVE, Bart., M.D., 17, Wimpole Street, Cavendish Square, W. *C.C.* 3.

ELECTED

1884 BENHAM, F. LUCAS, M.D., Campden House, nr. Exeter, Semaphore, South Australia. *Trans.* 4.

1883 BENHAM, ROBERT FITZROY, 11, Earl's Court Square, S.W.

1874 BENNETT, Sir WILLIAM HENRY, K.C.V.O., 1, Chesterfield Street, W. (C. 1889, 1892–4, S. 1890–1, V.P. 1895–8.) *Trans.* 4, *C.C.* 3.

1896 BENTHAM, EDWARD COOPER, 10, Princes Street, Cavendish Square, W.

1889 BENTLEY, ARTHUR J. M., M.D., Mena House, Pyramids, Cairo, Egypt.

1882 BERRY, FREDERICK HAYCRAFT, M.D., Watford, Herts.

1885 BERRY, JAMES, B.S., 21, Wimpole Street, W. (C. 1898–1901.) *Trans.* 1, *C.C.* 1.

1889 BIDWELL, LEONARD ARTHUR, 15, Upper Wimpole Street, W. (C. 1901–4.) *Trans.* 5, *C.C.* 1.

1882 BINDLEY, PHILIP HENRY, M.B. (Travelling).

1889 BISSHOPP, FRANCIS ROBERT BRYANT, M.A., M.D., B.S., Parham House, Tunbridge Wells.

1905 BLAKE, WILLIAM HENRY, M.D., Bedford Lodge, West Wickham, Kent.

1904 BOLTON, CHARLES, M.D., 16, Devonshire Street, Portland Place, W. *C.C.* 1.

1893 BOND, JAMES WILLIAM, M.D., 26, Harley Street, W. *C.C.* 2.

1898 BOSANQUET, WILLIAM CECIL, M.D., 117A, Harley Street, Cavendish Square, W.

1900 BOUSFIELD, ARTHUR, M.B., The Cheal, Hornsey Lane, N.

1899 BOWLAN, MARCUS MARWOOD, M.B., B.S., The Infirmary, Raine Street, St. George-in-the-East, E.

1883 BOWLBY, ANTHONY A., C.M.G., 24, Manchester Square, W. (C. 1891–3, 1904– , S. 1901–4.) *Trans.* 6, *C.C.* 4.

1883 Bowles, ROBERT LEAMON, M.D., Prior's Mesne, Lydney, Gloucestershire. (C. 1890–1.)

1896 BOX, CHARLES R., M.D., 2, Devonshire Place, Portland Place, W. *Trans.* 3.

1889 BOYD, STANLEY, B.S., 134, Harley Street, W. (C. 1899–1902.) *Trans.* 1, *C.C.* 7.

1890 BRADFORD, JOHN ROSE, M.D., F.R.S., 8, Manchester Square, W. (C. 1900–1902.) *Trans.* 2.

1878 BRIDGES, ROBERT, M.B., M.A., The Manor House, Yattendon, Berkshire. *Trans.* 1.

1868 BRIGHT, GEORGE CHARLES, M.D., Cannes, Alpes Maritimes, France.

O.M. BROADBENT, Sir WILLIAM HENRY, Bart., K.C.V.O., M.D., F.R.S., 84, Brook Street, W. (C. 1871–3, V.P. 1881–3, P. 1887–8.) *Trans.* 17.

1887 BROCK, J. H. E., M.D., B.S., 77, Fellows Road, South Hampstead, N.W.

1894 **BRODIE**, C. GORDON, Fernhill, Wootton Bridge, Isle of Wight. *C.C.* 1.

1905 BROOK, WILLIAM FREDERICK, Longland House, Swansea.

1898 **Brook**, WILLIAM HENRY BREFFIT, M.D., B.S., 8, Eastgate, Lincoln. (C. 1906– .) *Trans.* 4, *C.C.* 1.

ELECTED

1890 BROWN, WALTER HENRY, 19, Queen Street, Leeds. *Trans.* 2.

1876 BROWNE, GEORGE BUCKSTON, 80, Wimpole Street, W. (C. 1891–3.) *Trans.* 3.

1904 BROWNE, H. S. D., M.B., B.C., 78, High Street, Winchester.

1893 BROWNE, JAMES WILLIAM, M.B., 37, Holland Park Avenue, W. *Trans.* 1.

1887 BROWNE, OSWALD AUCHINLECK, M.A., M.D., 7, Upper Wimpole Street, W.

1883 BRUCE, JOHN MITCHELL, M.D., 23, Harley Street, W. (C. 1901–4.)

O.M. BRYANT, THOMAS, M.Ch., 42, Norfolk Square, W. (C. 1872, V.P. 1876–7, P. 1885–6.) *Trans.* 9.

1905 BRYDONE, JAMES MEAR, M.B., B.C., 16, South Audley Street, Grosvenor Square, W.

1890 BUCKLAND, FRANCIS O., B.A., M.B., C.M., Brockenhurst, Hants. *Trans.* 1.

1901 BUCKNALL, THOMAS RUPERT HAMPDEN, M.S., 16, Devonshire Street, W. *C.C.* 1.

1891 BURGHARD, FREDERIC FRANÇOIS, M.D., M.S., 86, Harley Street, W.

1881 BURNET, ROBERT WILLIAM, M.D., 36, Grosvenor Street, W. *Trans.* 1.

1879 BURTON, WILLIAM EDWARD, 24, Wimpole Street, W.

1900 ZUM BUSCH, JOSEF PAUL, M.D., Chiswell House, 133, Finsbury Pavement, E.C. *Trans.* 1, *C.C.* 1.

1881 BUTLIN, HENRY TRENTHAM, 82, Harley Street, W. (C. 1887–9, V.P. 1904–6.) *Trans.* 8, *C.C.* 1.

1884 BUXTON, DUDLEY WILMOT, M.D., B.S., 82, Mortimer Street, W.

1902 BUZZARD, EDWARD FARQUHAR, M.D., 33, Harley Street, W. *Trans.* 2.

O.M. BUZZARD, THOMAS, M.D., 74, Grosvenor Street, W. (S. 1870–2, C. 1873–6, V.P. 1880–1, P. 1895–7.) *Trans.* 15, *C.C.* 3.

1901 CADDY, ADRIAN, M.D, 2/2, Harington Street, Calcutta.

1891 CADDY, ARNOLD, 2/2, Harington Street, Calcutta.

1893 CALEY, HENRY ALBERT, M.D., 24, Upper Berkeley Street, W. *C.C.* 1.

1890 CALVERT, JAMES, M.D., 113, Harley Street, Cavendish Square, W. *Trans.* 2, *C.C.* 2.

1893 CAMPBELL, HARRY, M.D., 23, Wimpole Street, W., and Coniston Cottage, Fox Lane, Upper Norwood, S.E. (C. 1904- .) *C.C.* 4.

1891 CARLESS, ALBERT, M.S., M.B., 6, Upper Wimpole Street, W. (C. 1905– .)

1905 CARLING, E. ROCK, M.B., B.S., 38, New Cavendish Street, W.

1890 CARR, JOHN WALTER, M.D., 19, Cavendish Place, W. (C. 1903–6.) *Trans.* 2, *C.C.* 7.

1901 CARSON, HERBERT WILLIAM, 26, Welbeck Street, Cavendish Square, W. *Trans.* 1.

1901 Carwardine, THOMAS, M.S., 16, Victoria Square, Clifton, Bristol. *Trans.* 1.

ELECTED

1885 CATON, RICHARD, M.D., 86, Rodney Street, Liverpool. *Trans.* 3.

1890 CHAPMAN, CHARLES WILLIAM, M.D., 21, Weymouth Street, W. (C. 1900–3.) *Trans.* 3, *C.C.* 2.

1884 CHAPMAN, PAUL M., M.D., 1, St. John's Street, Hereford. *C.C.* 1.

1906 CHARLES, JOHN ROGER, M.D., 12, Victoria Square, Clifton, Bristol.

1893 CHARSLEY, ROBERT STEPHEN, "The Old Barn," Slough.

1885 CHEYNE, W. WATSON, C.B., M.B., C.M., F.R.S., 75, Harley Street, W. (C. 1894–6.) *Trans.* 2, *C.C.* 8.

1873 CHISHOLM, EDWIN, M.D., 44, Roslyn Gardens, Darlinghurst, Sydney, New South Wales.

O.M. **CHURCH**, Sir WILLIAM SELBY, Bart., K.C.B., M.D., 130, Harley Street, W. (C. 1874–6.)

1873 CHURTON, THOMAS, M.D., 35, Park Square, Leeds. (C. 1889–91.) *Trans.* 6.

O.M. CLAPTON, EDWARD, M.D., Towercroft, 41, Eltham Road, Lee, S.E. (C. 1872–4.) *Trans.* 1.

1874 CLARK, ANDREW, 71, Harley Street, W. *Trans.* 1.

1887 CLARK, FRANCIS WILLIAM, Hong-Kong.

1898 CLARKE, JAMES JACKSON, M.B., 18, Portland Place, W. *Trans.* 3, *C.C.* 11.

1885 Clarke, J. MICHELL, M.D., 28, Pembroke Road, Clifton, Bristol.

1885 CLARKE, WILLIAM BRUCE, M.B., 51, Harley Street, W. (C. 1894–7.) *Trans.* 2, *C.C.* 3.

1877 Clay, ROBERT HOGARTH, M.D., 4, Windsor Villas, Plymouth.

1887 CLEMOW, ARTHUR HENRY WEISS, M.D., C.M., 101, Earl's Court Road, W. *Trans.* 1, *C.C.* 1.

1877 **CLUTTON**, HENRY HUGH, M.A. (*President*), 2, Portland Place, W. (C. 1885–7, V.-P. 1902–4, P. 1905– .) *Trans.* 12, *C.C.* 3.

1898 COBB, ERNEST HERBERT, Belmont, Stevenage, Herts.

1893 COLE, ROBERT HENRY, M.D., Moorcroft, Hillingdon, Middlesex.

1882 COLLIER, HERBERT, M.D., 21, South Quay, Great Yarmouth, Norfolk.

1902 COLLINS, VICTOR EVELYN, M.B., Graaff Reinet, Cape Colony.

1896 COLMAN, WALTER STACY, M.D., 9, Wimpole Street, W. (C. 1903–6.) *Trans.* 2, *C.C.* 3.

1882 COLQUHOUN, DANIEL, M.D., Dunedin, New Zealand.

1868 COOPER, FRANK W. (address uncommunicated).

1900 COOPER, HARRY, M.D., Fownhope, Surbiton Hill, Surrey.

1903 COOPER, PERCY ROBERT, M.D., "Glenthorn," The Downs, Bowdon, Cheshire.

1902 CORNER, EDRED MOSS, B.Sc., M.B., 37, Harley Street, W. *Trans.* 6, *C.C.* 6.

O.M. COUPER, JOHN, 80, Grosvenor Street, W. (C. 1874.)

1875 COUPLAND, SIDNEY, M.D., 16, Queen Anne Street, W. (S. 1882–4, C. 1885–7, V.-P. 1898–1901.) *Trans.* 5, *C.C.* 3.

1886 COUSINS, JOHN WARD, M.D., Riversdale, Kent Road, Southsea. *Trans.* 1.

ELECTED

1882 COXWELL, C. F., M.B., Brighton, Melbourne, Victoria. *Trans.* 2.

1897 CRAWFURD, RAYMOND H. P., M.D., 71, Harley Street, Cavendish Square, W. *C.C.* 3.

1879 CRIPPS, WILLIAM HARRISON, 2, Stratford Place, W. (C. 1886–8.) *Trans.* 3.

1872 CRITCHETT, Sir G. ANDERSON, 21, Harley Street, W.

1877 CROCKER, HENRY RADCLIFFE, M.D., 121, Harley Street, W. (C. 1884–5.) *Trans.* 16.

1896 CROOKE-LAWLESS, W. R., Surg.-Maj. A.M.S., M.D., Guards' Club, S.W.

1898 CROUCH, HERBERT CHALLICE, 3, Mount Pleasant, Fowey, Cornwall.

1905 CUNNING, JOSEPH, M.B., B.S., 77, Wimpole Street, W. *Trans.* 1.

1893 CURTIS, HENRY JONES, M.D., B.S., Memorial Hospital, Buluwayo, Rhodesia. *C.C.* 1.

1902 CUTHBERT, CHARLES FIRMIN, 2, Barton Street, Gloucester.

1872 DALBY, Sir WILLIAM BARTLETT, M.B., 18, Savile Row, W. (C. 1879–81.) *Trans.* 4.

1896 DALTON, NORMAN, M.D., 4, Mansfield Street, Portland Place, W. (C. 1904– .) *Trans.* 4, *C.C.* 7.

1898 DARLEY-HARTLEY, WILLIAM, M.D., Seapoints, Cape Town, S. Africa.

1893 DAUBER, JOHN HENRY, M.B., B.Ch., 39, Hertford Street, Mayfair, W.

1879 Davy, HENRY, M.D., 29, Southernhay, Exeter.

1889 DEAN, HENRY PERCY, M.B., 69, Harley Street, W.

1897 DEANE, JOHN HENRY, 50, Wallwood Road, Leytonstone, Essex.

1899 DE CHAZAL, EDMOND LUCIEN, M.D., Port Louis, Mauritius.

1903 DELBRUCK, RAOUL ERNEST, M.B., 13, Buckingham Gate, S.W.

1879 Dennis, FREDERIC S., M.D., 542, Madison Avenue, New York, U.S.A.

1875 DENT, CLINTON T., 61, Brook Street, W. (C. 1884–6, V.P. 1905– .) *Trans.* 5. *C.C.* 1.

O.M. DICKINSON, WILLIAM HOWSHIP, M.D., 10, Stanhope Place, Marble Arch, W. (C. 1874–5, V.P. 1888–9.) *Trans.* 2.

1894 Dickson, THOMAS HUGH, M.B., B.C., H.M. Customs, Lower Thames Street, E.C.

1871 DIVER, EBENEZER, M.D., 95, London Road, Portsmouth. (C. 1890–2.) *Trans.* 1.

1901 DOUGLAS, JOHN J., M.D., 42, Central Hill, Norwood, S.E. *C.C.* 1.

1868 DRAGE, CHARLES, M.D., Hatfield, Herts.

1896 DREW, DOUGLAS, M.D., B.S., 1, Harley Street, Cavendish Square, W. *Trans.* 1. *C.C.* 1.

1906 DRYSDALE, J. H., M.D., 11, Devonshire Place, W.

O.M. DUCKWORTH, Sir DYCE, M.D., LL.D., 28, Grosvenor Place, S.W. (C. 1875–7, V.P. 1887–8, P. 1891–2.) *Trans.* 24, *C.C.* 8.

1902 DUDGEON, LEONARD S., 6, Powis Gardens, Bayswater, W. *Trans.* 1, *C.C.* 2.

1884 DUKE, EDGAR, 11, Wilbury Road, Hove.

1869 DUKE, OLLIVER THOMAS, M.B., Surgeon, Bengal Army, India

ELECTED

1899 DUNCAN, ANDREW, M.D., 24, Chester Street, Grosvenor Place, S.W. *Trans.* 1.

1889 DUNCAN, JOHN, M.D., St. Petersburg.

1889 DUNN, LOUIS ALBERT, M.S., 51, Devonshire Street, Portland Place, W. (C. 1899–1902.) *Trans.* 2, *C.C.* 2.

1884 EDMUNDS, WALTER, M. C., 2, Devonshire Place, Portland Place, W. (C. 1902–5.) *Trans.* 2.

1899 EID, ALFRED, M.D., Cairo, Egypt.

1902 ELLIOT, ANDREW, M.D., 11, Upper Berkeley Street, Portman Square, W.

1882 EMOND, EMILE, M.D., 113, Boulevard Beaumarchais, Paris.

1902 ENGLISH, THOMAS CRISP, B.S., 31, Grosvenor Street, W. *C.C.* 1.

1893 EVANS, WILLMOTT H., M.D., B.S., 2, Upper Wimpole Street, Cavendish Square, W. *C.C.* 1.

1888 **EVE**, FREDERIC S., 61, Harley Street, Cavendish Square, W. (C. 1899–1902.) *Trans.* 6, *C.C.* 10.

1877 **EWART**, WILLIAM, M.D., 33, Curzon Street, W. (C. 1884–6, V.P. 1905– .) *Trans.* 5, *C.C.* 4.

1899 FAGGE, CHARLES HERBERT, M.S., 22, St. Thomas's Street, London Bridge, S.E. *Trans.* 1, *C.C.* 1.

1868 **Fairbank**, FREDERICK ROYSTON, M.D., Westcott, Dorking, Surrey. *Trans.* 2.

1905 FAIRBANK, HAROLD A. T., 137, Harley Street, W. *C.C.* 1.

1889 FARDON, EDWARD ASHBY, Middlesex Hospital, W.

1900 FAWCETT, JOHN, M.D., 66, Wimpole Street, W. *Trans.* 2, *C.C.* 2.

1902 FEDDEN, WALTER FEDDE, M.B., M.S., 20, Lower Seymour Street, Portman Square, W.

1902 FENNELL, CHARLES HENRY, M.D., County Asylum, Hellingly, Sussex. *C.C.* 1.

1887 FENWICK, E. HURRY, 14, Savile Row, W. *Trans.* 2, *C.C.* 2.

1872 FENWICK, J. C. J., M.D., Long Framlington, Morpeth.

1893 FENWICK, WILLIAM SOLTAU, M.D., 29, Harley Street, W. *Trans.* 2.

1878 FIELD, GEORGE P., 34, Wimpole Street, W.

1876 FINLAY, Prof. DAVID WHITE, M.D., 2, Queen's Terrace, Aberdeen. (C. 1885–7, S. 1891.) *Trans.* 5.

1894 FLETCHER, HERBERT MORLEY, M.D., 98, Harley Street, W. (C. 1906– .) *Trans.* 1, *C.C.* 1.

1878 **FONMARTIN**, HENRY DE, M.D. (Travelling.)

1905 FORSYTH, DAVID, M.D., 24, St. Thomas's Street, London Bridge, S.E.

1890 FOSTER, MICHAEL G., M.D., M.A., Villa San Giovanni, San Remo, Italy.

1899 FOWLER, CHARLES OWEN, M.D., Cotford House, Thornton Heath, Surrey.

1881 FOWLER, JAMES KINGSTON, M.D. (*Trustee*), 35, Clarges Street, W. (C. 1887–9, 1899–1902, S. 1896–9, V.-P. 1904–6.) *Trans.* 4, *C.C.* 6.

1886 FOX, R. HINGSTON, M.D., 29, Weymouth Street, Portland Place, W. *C.C.* 1.

ELECTED

1878 FOX, THOMAS COLCOTT, M.B., 14, Harley Street, W. (C. 1888–90.) *Trans.* 7, *C.C.* 2.

1893 FOXWELL, ARTHUR, M.D., 22, Newhall Street, Birmingham.

1902 FRENCH, HERBERT, M.D., 26, St. Thomas's Street, London Bridge, S.E. *Trans.* 1. *C.C.* 1.

1897 FRIPP, Sir ALFRED DOWNING, C.B., M.V.O., M.S., 19, Portland Place, W. (C. 1904– .) *Trans.* 3.

1899 FÜRTH, KARL, M.D., 39, Harley Street, W.

1890 FULLER, HENRY ROXBURGH, M.D., 45, Curzon Street, W.

1897 FURNIVALL, PERCY, 28, Weymouth Street, Portland Place, W.

1891 FYFFE, W. KINGTON, M.B., B.C., 19, Duke Street, Manchester Square, W. (Travelling, New Zealand.) *Trans.* 1.

1895 GALLOWAY, JAMES, M.D., 54, Harley Street, W.

1887 GARROD, ARCHIBALD EDWARD, M.A., M.D. (*Hon. Secretary*), 9, Chandos Street, Cavendish Square, W. (C. 1898–1901, S. 1905– .) *Trans.* 5, *C.C.* 7.

1879 GARSTANG, THOMAS WALTER HARROPP, Edge Mount, Altrincham.

1903 GATES, EDWARD A., via Palestro A., Florence.

1885 GIBBONS, ROBERT ALEXANDER, M.D., 29, Cadogan Place, S.W. *Trans.* 1

1893 GIBBS, CHARLES, 48, Queen Anne Street, W. *C.C.* 1.

1868 GLOVER, JAMES GREY, M.D., 25, Highbury Place, N. (C. 1878–80. V.P. 1892–4.) *Trans.* 2.

1893 GLOVER, LEWIS G., M.B., B.C., 17, Belsize Park, Hampstead, N.W.

1875 GODLEE, RICKMAN JOHN, M.S., 19, Wimpole Street, W. (C. 1882–3, 1887–9, S. 1884–6, V.P. 1895–8.) *Trans.* 14, *C.C.* 10.

1901 GOFFE, ERNEST GEORGE LEOPOLD, M.D., Western Hospital, Seagrave Road, Fulham, S.W.

1882 GOLDIE, ROBERT WILLIAM, Hirst House, Hirst, Morpeth, Northumberland.

1878 GOLDING-BIRD, C. H., M.B., 12, Queen Anne Street, W. (C. 1887–9, V.-P. 1903–5.) *Trans.* 18, *C.C.* 1.

1894 GOODALL, EDWARD WILBERFORCE, M.D., Eastern Hospital, Homerton, N.E. (C. 1904– .) *Trans.* 8.

1875 GOODHART, JAMES FREDERIC, M.D., 25, Portland Place, W. (C. 1880–2, V.P. 1897–1900.) *Trans.* 14, *C.C.* 2.

1891 GOODMAN, ROGER NEVILLE, M.B., Elmside, Kingston-on-Thames.

1869 GOODRIDGE, HENRY FREDERICK AUGUSTUS, M.D., 10, Brock Street, Bath.

1882 GOODSALL, D. H., 17, Devonshire Place, W.

1877 GOULD, A. PEARCE, M.S., 10, Queen Anne Street, W. (C. 1885–7, 1895–8, S. 1892–5, V.-P. 1898–1901.) *Trans.* 14, *C.C.* 9.

1901 GOWAN, BOWIE CAMPBELL, Raven Dene, Great Stanmore, Middlesex.

ELECTED

1875 GOWERS, Sir WILLIAM RICHARD, M.D., F.R.S., 50, Queen Anne Street, W. (C. 1881–2, V.-P. 1903–5.) *Trans.* 5, *C.C.* 1.

1904 GRAHAM, GEORGE HERBERT, M.D., 14, Old Cavendish Street, W.

1891 GRANT, J. DUNDAS, M.D., 18, Cavendish Square, W.

1868 GREEN, T. HENRY, M.D., 74, Wimpole Street, W. (C. 1877–9.) *Trans.* 2, *C.C.* 1.

1875 Greenfield, WILLIAM SMITH, M.D., 7, Heriot Row, Edinburgh. (C. 1881.) *Trans.* 3.

1893 GRIFFITH, WALTER SPENCER ANDERSON, M.D., 96, Harley Street, W.

1895 Grube, KARL, M.D., Neuenahr, Germany. *Trans.* 1.

1895 GUTHRIE, LEONARD GEORGE, M.D., 15, Upper Berkeley Street, W. (C. 1906– .) *Trans.* 1, *C.C.* 9.

1887 HABERSHON, SAMUEL HERBERT, M.D., 88, Harley Street, W. (C. 1901–4.) *C.C.* 1.

1900 HADLEY, WILFRED J., M.D., 33, Queen Anne Street, Cavendish Square, W.

1875 HALE, C. D. B., 3, Sussex Place, W. *Trans.* 1.

1903 HALL, JOHN BASIL, M.C., 31, Manningham Lane, Bradford.

1878 HALL, F. DE HAVILLAND, M.D., 47, Wimpole Street, W. (C. 1885–7, V.-P. 1904–6.) *Trans.* 8, *C.C.* 5.

1889 HALSTEAD, GEORGE EZRA, M.D., B.S., Albion Hill House, Ramsgate.

1888 HANDFIELD-JONES, MONTAGU, M.D., 35, Cavendish Square, W.

1886 Handford, HENRY, M.D., 6, Regent Street, Nottingham. (C. 1893–4.) *Trans.* 8, *C.C.* 1.

1906 HANN, REGINALD GEORGE, 23, Blundell Street, Leeds.

1904 HARBURN, JOHN ENGLISH, 8, Broad Walk, Buxton, Derbyshire.

1886 HARDIE, JAMES, M.D., 15, St. John Street, Manchester.

1890 HARPER, JAMES, M.D., 25, Rosary Gardens, South Kensington, S.W.

1872 HARRIS, HENRY, M.D., Trengweath, Redruth, Cornwall.

1889 HARRIS, HERBERT ELWIN, M.B., 13, Lansdown Place, Victoria Square, Clifton, Bristol. *Trans.* 1.

1903 HARRIS, WILFRED, M.D., 61, Wimpole Street, Cavendish Square, W. *Trans.* 1, *C.C.* 2.

1881 HARRISON, CHARLES EDWARD, M.B., Queen Alexandra Military Hospital, Millbank, S.W.

1892 HARRISON, DAMER, 53, Rodney Street, Liverpool. *Trans.* 1.

1901 HARTLEY, PERCIVAL HORTON-SMITH, M.V.O., M.D., 19, Devonshire Street, Portland Place, W.

1869 HAWARD, J. WARRINGTON, 57, Green Street, Grosvenor Square, W. (C. 1876–8, 1884–6, S. 1881–3, V.P. 1888.) *Trans.* 15.

1899 Hawkes, CLAUDE SOMERVILLE, Glencairn, Wickham Terrace, Brisbane, Queensland, Australia.

1886 HAWKINS, FRANCIS HENRY, M.D., 73, London Street, Reading. (C. 1902–5.) *Trans.* 6, *C.C.* 3.

ELECTED

1889 HAWKINS, HERBERT PENNELL, M.D., B.Ch., 56, Portland Place, W. (C. 1900–3.) *Trans.* 1.

1890 HAWKINS-AMBLER, GEORGE ARTHUR, 30, Rodney Street, Liverpool.

1900 HAYWARD, JOHN ARTHUR, M.D., 23, The Grange, Wimbledon Common, S.W.

1903 HEATH, PHILIP MAYNARD, M.B., 36, Cavendish Square, W. *C.C.* 1.

1879 HENDERSON, GEORGE COURTENAY, M.D., Kingston, Jamaica, West Indies.

1884 HERRINGHAM, WILMOT PARKER, M.D., 40, Wimpole Street, W. (C. 1894–7.) *Trans.* 6, *C.C.* 4.

1874 HOLDERNESS, WILLIAM BROWN, 15, Park Street, Windsor.

1868 Holman, Sir CONSTANTINE, M.D., 26, Gloucester Place, Portman Square, W. (C. 1894–7.)

1878 HOOD, DONALD WILLIAM CHARLES, M.D., 43, Green Street, Park Lane, W. (C. 1891–3.) *Trans.* 1.

1884 HORSLEY, Sir VICTOR, M.B., F.R.S., 25, Cavendish Square, W. (C. 1894.) *Trans.* 2, *C.C.* 1.

1895 HOUGH, CHARLES HENRY, The Cottage, Clappersgate, Ambleside, Windermere.

1880 HOVELL, T. MARK, 105, Harley Street, W. *Trans.* 1.

1893 HOWARD, R. J. BLISS, M.D., 31, Queen Anne Street, W.

1898 HULKE, SYDNEY BACKHOUSE, Ivy House, Walmer, Kent.

1897 HUMPHRYS, CHARLES B., Eagle House, Blandford, Dorset.

1897 HUNT, GEORGE BERTRAM, M.B., 47, Albemarle Crescent, Scarborough. *Trans.* 1, *C.C.* 1.

1892 HUNTER, WILLIAM, M.D., 103, Harley Street, W.

O.M. HUTCHINSON, JONATHAN, F.R.S., 15, Cavendish Square, W. (C. 1867–8, V.P. 1875–6.) *Trans.* 14, *C.C.* 1.

1896 HUTCHINSON, JONATHAN, jun., 15, Cavendish Square, W. (C. 1902–5. *Trans.* 6, *C.C.* 8.

1893 IONIDES, THEODORE HENRY, M.B., B.S., 25, First Avenue, Brighton.

1883 JACKSON, GEORGE HENRY, Ashburton, Carew Road, Eastbourne.

O.M. JACKSON, J. HUGHLINGS, M.D., F.R.S., 3, Manchester Square, W. (C. 1872–3, V.P. 1887.) *Trans.* 2, *C.C.* 1.

1888 JAMES, JAMES THOMAS, M.D., 30, Harley Street, W.

1901 JOHNSON, EDWARD ANGAS, M.B., B.S., 56, Franklin Street, Adelaide, South Australia.

1889 JOHNSON, RAYMOND, M.B., B.S., 11, Wimpole Street, W. (C. 1900–3.) *Trans.* 6, *C.C.* 6.

1893 JOHNSTON, G. F., M.D., 3, Montagu Place, Montagu Square, W.

1904 JONES, A. ERNEST, M.D., B.Sc., 13, Harley Street, W.

ELECTED

1903 JONES, ERNEST LLOYD, 59, Trumpington Street, Cambridge.
1902 JONES, LAWRENCE, 31, Grosvenor Street, W.
1898 Jones, ROBERT, 11, Nelson Street, Liverpool. *Trans.* 2.
1872 JONES, THOMAS RIDGE, M.D., 4, Chesham Place, S.W. (C. 1892–3.)
1876 JORDAN, FURNEAUX, 10, Ferndale, Teignmouth, S. Devon. *Trans.* 1.
1902 JOWERS, REGINALD F., 55, Brunswick Square, Brighton.
1878 KEETLEY, CHARLES ROBERT BELL, 56, Grosvenor Street, W. (C. 1895–8.) *Trans.* 2.
1898 KELLOCK, THOMAS HERBERT, 8, Queen Anne Street, Cavendish Square, W. (C. 1903–6.) *Trans.* 4, *C.C.* 7.
1901 KELYNACK, THEO. N., M.D., 120, Harley Street, W.
1897 KEYSER, CHARLES RALPH, Cotswold Sanatorium, Stroud, Gloucestershire. *Trans.* 1, *C.C.* 5.
1883 KIDD, PERCY, M.D., 60, Brook Street, W. (C. 1891–2, 1902–5, S. 1899–1902.) *Trans.* 5, *C.C.* 10.
1887 Knaggs, R. LAWFORD, B.C., 27, Park Square, Leeds. *Trans.* 2.
1878 LACEY, THOMAS WARNER, 196, Burrage Road, Plumstead.
1897 LAMPLOUGH, CHARLES, Kirkstall, Alverstoke, Hants.
1890 LANCASTER, ERNEST LE CRONIER, M.B., B.Ch., Winchester House, Swansea, S. Wales. *Trans.* 2.
1895 LANE, JAMES ERNEST, 46, Queen Anne Street, W. (C. 1905– .) *Trans.* 1.
1883 LANE, WILLIAM ARBUTHNOT, M.B., M.S., 21, Cavendish Square, W. (C. 1893–6.) *Trans.* 29, *C.C.* 10.
O.M. **LANGTON**, JOHN, 62, Harley Street, W. (C. 1878–80, V.P. 1892–4, P. 1897–9.) *Trans.* 5.
1886 LANKESTER, HERBERT, M.D., Ingleborough, Woking, Surrey.
1885 LARDER, HERBERT, Whitechapel Infirmary, Vallance Road, E. *C.C.* 1.
1893 LAWSON, ARNOLD, M.D., 12, Harley Street, W.
1900 LEAF, CECIL H., M.B., 75, Wimpole Street, Cavendish Square, W.
1877 Lediard, HENRY AMBROSE, M.D., 35, Lowther Street, Carlisle. (C. 1889, V.-P. 1902–4.) *Trans.* 5, *C.C.* 1.
1896 Leech, PRIESTLEY, M.D., King Cross, Halifax.
1877 LEES, DAVID B., M.D., 22, Weymouth Street, W. (C. 1885, V.-P. 1902–4.) *Trans.* 6.
1902 LEGG, THOMAS PERCY, M.B., 141, Harley Street, Cavendish Square, W.
1899 LESLIE, R. MURRAY, M.D., 26, Harley Street, Cavendish Square, W. *C.C.* 1.
1901 LEWERS, ARTHUR HAMILTON NICHOLSON, M.D., 72, Harley Street, Cavendish Square, W.
1892 LEWIS, EDWARD JOHN, M.B., B.C., 74, Hamilton Terrace, N.W.
1895 LEWIS, ERNEST E., M.D., 30, Weymouth Street, W.
1903 LITTLE, E. GRAHAM, M.D., 61, Wimpole Street, W.
1890 LITTLE, JOHN FLETCHER, M.B., 125, Harley Street, W. *C.C.* 5.
1891 LITTLEWOOD, HARRY, 25, Park Square, Leeds. *Trans.* 1.

ELECTED

1885 LOCKWOOD, CHARLES BARRETT, 19, Upper Berkeley Street, W. (C. 1896-9.) *Trans.* 7.

1876 **LONGHURST**, ARTHUR EDWIN TEMPLE, M.D., 26, Lower Belgrave Street, Eaton Square, S.W. (C. 1889-91.) *Trans.* 1.

1904 LONGHURST, FREDERIC W., 26, Lower Belgrave Street, Eaton Square, S.W.

1897 LOW, HAROLD, M.B., 10, Evelyn Gardens, South Kensington, S.W.

1899 LOW, V. WARREN, M.D., B.S., 146, Harley Street, Cavendish Square, W. *Trans.* 1.

1881 LUBBOCK, MONTAGU, M.D., 19, Grosvenor Street, W.

1876 LUCAS, R. CLEMENT, M.B., B.S., 50, Wimpole Street, W. (C. 1883-5, V.P. 1901-3.) *Trans.* 12. *C.C.* 1.

1894 LUFF, ARTHUR PEARSON, M.D., 9, Queen Anne Street, Cavendish Square, W.

1879 LUNN, JOHN REUBEN, St. Marylebone Infirmary, Rackham Street, Ladbroke Grove Road, W. (C. 1890-1, V.P. 1905- .) *Trans.* 8, *C.C.* 23.

1893 LYS, HENRY GRABHAM, M.D., Southbrook, Suffolk Road, Bournemouth.

1889 MACBRIDE, P., M.D., 16, Chester Street, Edinburgh.

1891 MACDONALD, GREVILLE, M.D., 85, Harley Street, W.

1901 MCGAVIN, LAURIE HUGH, 6, Mansfield Street, Cavendish Square, W. *Trans.* 3, *C.C.* 6.

1881 MCHARDY, MALCOLM MACDONALD, 5, Savile Row, W. *Trans.* 1.

1891 MACKENZIE, HECTOR W. G., M.A., M.D., 34, Upper Brook Street, W. (C. 1902-5.) *Trans.* 6, *C.C.* 1.

1879 MACKENZIE, SIR STEPHEN, M.D., 18, Cavendish Square, and Merrycourt, Gt. Bookham, Leatherhead. (C. 1884, 1888-90, S. 1885-7. V.P. 1900-2.) *Trans.* 9, *C.C.* 10.

1884 MACKERN, JOHN, M.B., St. German's Lodge, Shooter's Hill Road, Blackheath, S.E.

1885 MACLAREN, RODERICK, M.D., Portland Square, Carlisle. *Trans.* 1.

1898 MACREADY, JONATHAN F.C.H., 42, Devonshire Street, Portland Place, W.

1879 MAGILL, JAMES, M.D., M.C., Coldstream Guards, Queen Anne's Mansions, S.W.

1885 MAGUIRE, ROBERT, M.D., 4, Seymour Street, W. *Trans.* 1.

1881 MAKINS, GEORGE HENRY, C.B. (*Treasurer*), 47, Charles Street, Berkeley Square, W. (C. 1892-4, 1898-1901, S. 1895-8, T. 1903- , V.P. 1906- .) *Trans.* 5, *C.C.* 7.

1887 MALCOLM, JOHN D., M.B., C.M., 13, Portman Street, W. (C. 1900-3.) *Trans.* 3, *C.C.* 2.

1890 MANSON, Sir PATRICK, K.C.M.G., M.D., C.M., F.R.S., 21, Queen Anne Street, W. (C. 1895-7.) *C.C.* 1.

1902 MARRIOTT, CECIL, M.B., M.C., 11, Welford Road, Leicester.

ELECTED

1888 **Marriott**, HYDE, M.B., Dial House, Stockport.

1868 MARSH, Professor F. HOWARD, 14, Hertford Street, Mayfair, W. (C. 1876–7, 1881–3, S. 1878–80, V.P. 1887–8, T. 1899–1901, P. 1901–3.) *Trans.* 20, *C.C.* 7.

1887 MARTIN, SIDNEY, M.D., B.S., F.R.S., 10, Mansfield Street, W. (C. 1896–9.)

1888 MASON, DAVID JAMES, M.D., C.M., Rosemont, Maidenhead.

1892 MASTERS, JOHN ALFRED, M.D., 94, Knightsbridge, S.W.

1884 MAUDSLEY, HENRY CARR, M.D., 22, Collins Street, Melbourne, Victoria.

1897 MAY, CHICHESTER GOULD, M.D., 59, Cadogan Place, S.W.

1868 **May**, EDWARD HOOPER, M.D., High Cross, Tottenham, Middlesex.

1888 MAY, WILLIAM PAGE, M.D., B.Sc., 9, Manchester Square, W.; and Helouan, nr. Cairo, Egypt (October to April).

1901 MENZIES, F. U., Edinburgh University Union, Edinburgh.

1888 MENZIES, J. HERBERT, 47, Earl's Court Square, S.W.

1893 MERCER, WILLIAM BRACEWELL, M.B., B.C., Cliffe Cottage, Ripponden, near Halifax, Yorks.

1878 MEREDITH, WILLIAM APPLETON, C.M., 21, Manchester Square, W. (C. 1887–9.) *Trans.* 2.

1894 MICHELS, ERNST, M.D., 48, Finsbury Square, E.C.

1873 MICKLE, WILLIAM JULIUS, M.D. (address uncommunicated). (C. 1897–1900.)

1890 MILEY, MILES, M.A., M.B., 21, Belsize Avenue, Hampstead, N.W.

1896 MILLS-ROBERTS, ROBERT HERBERT, C.M.G., Llanberis, North Wales. *Trans.* 1.

1902 MOON, R. O., M.D., 50, Green Street, Grosvenor Square, W. *C.C.* 1.

1874 **MORGAN**, JOHN HAMMOND, C.V.O. (*Trustee*), 68, Grosvenor Street, W. (C. 1883–5, V.P. 1898–1901.) *Trans.* 2, *C.C.* 8.

1888 MORISON, ALEXANDER, M.D., 14, Upper Berkeley Street, W. *Trans.* 2, *C.C.* 1.

1899 MORISON, RUTHERFORD, 14, Saville Row, Newcastle-on-Tyne. *Trans.* 1.

1903 MORLEY, ARTHUR S., 29, Gower Street, W.C.

1877 MORRIS, HENRY, M.A., M.B., 8, Cavendish Square, W. (C. 1884–6. V.P. 1903–5.) *Trans.* 9.

1877 MORRIS, MALCOLM ALEX., 8, Harley Street, W. (C. 1890–2.) *Trans.* 1, *C.C.* 1.

1901 MORSE, THOMAS HENRY, All Saints' Green, Norwich. *Trans.* 1.

1902 MORTON, CHARLES ALFRED, 14, Vyvyan Terrace, Clifton, Bristol. *Trans.* 1.

1885 MOTT, FREDERICK WALKER, M.D., F.R.S., 25, Nottingham Place, W. (C. 1895–8.) *Trans.* 1, *C.C.* 4.

1899 MOUAT-BIGGS, CHARLES E. FORBES, 2, Fauconberg Villas, Bayshill, Cheltenham. *C.C.* 2.

1879 MOULLIN, CHARLES W. MANSELL, 69, Wimpole Street, W. (C. 1888–90.) *Trans.* 11, *C.C.* 4.

ELECTED

1900 MOYNIHAN, BERKELEY GEORGE ANDREW, M.S., 33, Park Square, Leeds. (C. 1904– .) *Trans.* 3.

1905 MUECKE, FRANCIS FREDERICK, M.B., B.S., 63, Wellington Road, N.W.

1875 MURPHY, Sir SHIRLEY F., 9, Bentinck Terrace, Regent's Park, N.W. (C. 1888–90.) *C.C.* 1.

1885 MURRAY, ALEXANDER DALTON, M.B., Colombo, Ceylon.

1893 MURRAY, GEORGE REDMAYNE, M.D., 11, Ellison Place, Newcastle-on-Tyne.

1883 MURRAY, HUBERT MONTAGUE, M.D., 25, Manchester Square, W. (C. 1893–6.) *Trans.* 1.

1894 MURRAY, JOHN, 110, Harley Street, W. *C.C.* 1.

1872 MYRTLE, ANDREW S., M.D., 10, Park Parade, Harrogate. (C. 1892.)

1902 NABARRO, DAVID, M.D., 4, Albemarle Mansions, Heath Drive, Hampstead, N.W.

1892 NASH, WALTER GIFFORD, 31, St. Peter's, Bedford.

1889 Newman, D., M.D., 28, Woodside Place, Glasgow. *Trans.* 5.

O.M. NORTON, ARTHUR TREHERN, C.B., Leyfields Wood, Ashampstead, Berks. (C. 1874–6.) *Trans.* 7.

1880 O'CONNOR, BERNARD, M.D., Twyford Abbey, Willesden, N.W. *Trans.* 1.

1899 OGLE, CYRIL, M.D., 96, Gloucester Place, Portman Square, W. *Trans.* 1.

1887 Oliver, THOMAS, M.D., 7, Ellison Place, Newcastle-upon-Tyne.

1887 OPENSHAW, THOMAS HORROCKS, C.M.G., M.B., 16, Wimpole Street, W. (C. 1905– .) *Trans.* 1, *C.C.* 8.

1868 OPPERT, FRANZ, M.D., 128, Leipzigerstrasse, Friedenau, Germany. *Trans.* 1.

1889 ORD, W. WALLIS, M.D., B.Ch., The Hall, Salisbury. *Trans.* 1, *C.C.* 1.

1887 ORMEROD, JOSEPH ARDERNE, M.D., 25, Upper Wimpole Street, W. (C. 1899–1902.) *C.C.* 2.

1884 ORMSBY, Sir LAMBERT HEPENSTAL, M.D., 92, Merrion Square West, Dublin.

1888 OXLEY, ALFRED RICE, M.D., 5, Kensington Square, W.

1888 PAGE, FREDERICK, M.D., 1, Saville Place, Newcastle-on-Tyne.

1875 PAGE, HERBERT W., M.C., M.B., 146, Harley Street, W. (C. 1882–4, V.P. 1899–1902.) *Trans.* 8, *C.C.* 2.

1884 PAGET, STEPHEN, 70, Harley Street, W. (C. 1898–1901.) *Trans.* 9, *C.C.* 3.

1881 PARKER, RUSHTON, M.B., B.S., 59, Rodney Street, Liverpool. (C. 1896–9.) *Trans.* 1, *C.C.* 2.

1890 PARKIN, ALFRED, M.S., 24, Albion Street, Hull. *Trans.* 2.

1894 PARKINSON, JOHN PORTER, M.D., 57, Wimpole street, W. *Trans.* 1. *C.C.* 5.

ELECTED

1898 PARTRIDGE, ARTHUR A. H., M.D., M.Ch., St. Germans, Sutton, Surrey.

1881 PASTEUR, WILLIAM, M.D., 4, Chandos Street, W. (C. 1891–3, 1905–6, S. 1902–5, V.P. 1906– .) *Trans.* 7, *C.C.* 5.

1893 PATERSON, DONALD ROSE, M.D., C.M., 15, St. Andrew's Crescent, Cardiff.

1900 PATON, EDWARD PERCY, M.S., 53, Queen Anne Street, Cavendish Square, W. *Trans.* 3.

1892 PAUL, FRANK THOMAS, 38, Rodney Street, Liverpool. *Trans.* 1.

1893 PAUL, JOHN ERNEST, M.B., 26, Queensborough Terrace, Kensington Gardens, W. *Trans.* 1.

O.M. PAVY, FREDERICK WILLIAM, M.D., F.R.S., 35, Grosvenor Street, W. (C. 1869–71, V.P. 1882–4.) *Trans.* 3.

1879 PEEL, ROBERT, 120, Collins Street East, Melbourne, Victoria.

1882 PEPPER, AUGUSTUS JOSEPH, M.S., M.B., 13, Wimpole Street, W. *Trans.* 1.

1898 PERKINS, J. J., M.D., 41, Wimpole Street, Cavendish Square, W. *Trans.* 1, *C.C.* 1.

1895 PHEAR, ARTHUR G., M.D., B.C., 47, Weymouth Street, Portland Place, W. *Trans.* 2.

1895 PHILLIPS, F. B. WILLMER, M.B., 7, Harper Place, Bedford.

1885 PHILLIPS, SIDNEY, M.D., 3, Upper Brook Street, W. (C. 1893-6.) *Trans.* 10, *C.C.* 6.

1885 PITT, GEORGE NEWTON, M.D., 15, Portland Place, W. (C. 1894–6.) *Trans.* 7, *C.C.* 6.

1883 PITTS, BERNARD, M.A., M.C., 109, Harley Street, W. (C. 1893.) *Trans.* 5.

1871 Playne, ALFRED, M.B., Maidenhead.

1884 POLLARD, BILTON, B.S., 24, Harley Street, W. (C. 1895–8.) *Trans.* 2.

1868 POLLOCK, JAMES EDWARD, M.D., 37, Collingham Place, S.W. (C. 1878–80.)

1881 POWELL, H. A., M.A., 44, Sandgate Road, Folkestone.

O.M. POWELL, Sir R. DOUGLAS, Bart., K.C.V.O., M.D., 62, Wimpole Street, W. (C. 1874–6, V.P. 1889–90, P. 1899-1901.) *Trans.* 4.

1868 PRENTIS, CHARLES, Surgeon-Major, Bengal Medical Service; India.

1902 PRICE, F. W., M.B., 77, Wimpole Street, W.

1884 PRINGLE, JOHN JAMES, M.B., 23, Lower Seymour Street, W. (C. 1890–2, 1897–1900.) *Trans.* 1, *C.C.* 3.

1884 PYE-SMITH, PHILIP HENRY, M.D., F.R.S., 48, Brook Street, W. (C. 1890–2.) *Trans.* 1.

1896 PYE-SMITH, RUTHERFORD JOHN, 350, Glossop Road, Sheffield.

1893 RAKE, ALFRED THEODORE, M.B., B.S., 58, Delancey Street, Regent's Park, N.W.

1895 RAMSAY, HERBERT MURRAY, 35A, Hertford Street, Mayfair, W.

1889 RANKING, JOHN E., M.D., Hanover House, Tunbridge Wells.

ELECTED

1883 READ, THOMAS LAURENCE, 11, Petersham Terrace, Queen's Gate, S.W.

1902 REID, Sir JAMES, Bart., G.C.V.O., K.C.B., 72, Grosvenor Street, Grosvenor Square, W.

1901 REISSMANN, CHARLES, M.D., College Town, Adelaide, South Australia.

1899 Rennie, GEORGE EDWARD, M.D., College Street, Hyde Park, Sydney, N.S.W.

1868 RICE, MICHAEL W., M.D., Elmbank, Hargrave, Northamptonshire, (C. 1876–8.)

1898 RICHARDS, JOSEPH STEWART, M.D., B.S., 5, Wellesley Villas, Wellesley Road, Croydon, S.E. *C.C.* 2.

1903 RIGBY, HUGH, M.S., 7, Wimpole Street, Cavendish Square, W. *C.C.* 2.

O.M. RINGER, SYDNEY, M.D., F.R.S., 15, Cavendish Place. W. (C. 1871–2.) *Trans.* 1.

1896 RISDON, WILLIAM ELLIOT, M.D., 4, Etchingham Park Road, Church End, Finchley, N.

1903 RIVIERE, CLIVE, M.D., 19, Devonshire Street, W. *C.C.* 1.

1873 Roberts, DAVID LLOYD, M.D., 11, St. John Street, Manchester.

1888 ROBERTS, FRANK ERNEST, Tulse Dale Villa, Lower Norwood, S.E.

1883 ROBERTS, FREDERICK THOMAS, M.D., 102, Harley Street, W. (C. 1892–4.)

1900 ROBERTS, GRIFFITH LLOYD, M.B., C.M., Castle Square, Carnarvon, North Wales.

1890 ROBERTSON, ROBERT, M.D., Belgrave Road, Ventnor, Isle of Wight.

1885 ROBINSON, ARTHUR HENRY, M.D., St. Mary's Infirmary, Highgate Hill, N. *C.C.* 3.

1892 ROBINSON, HENRY BETHAM, M.D., M.S., 1, Upper Wimpole Street, W. (C. 1901–4). *Trans.* 10, *C.C.* 11.

1885 ROBSON, A. W. MAYO, 8, Park Crescent, W., (C. 1893–6.) *Trans.* 15.

1889 ROLLESTON, HUMPHRY DAVY, M.A., M.D., 55, Upper Brook Street, Grosvenor Square, W. (C. 1899–1902.) *Trans.* 11. *C.C.* 10.

1897 ROSS, FREDERICK WILLIAM FORBES, M.D., 15, Gower Street, W.C.

1877 ROTH, BERNARD, 38, Harley Street, Cavendish Square, and "Kingswood," Enfield, Middlesex. *Trans.* 1, *C.C.* 4.

1890 ROUGHTON, EDMUND WILKINSON, B.S., 38, Queen Anne Street, W. *Trans.* 2, *C.C.* 1.

1905 ROUGHTON, JOHN PAUL, Evelyns, Kettering, Northamptonshire.

1874 ROWLAND, EDWARD ROGER, Dordrecht, Wodehouse, S. Africa.

1904 ROWLANDS, R. P., M.S., 6, St. Thomas's Street, London Bridge, S.E. *C.C.* 2.

1906 ROWNTREE, CECIL W., B.S., 20, Richmond Road, Canonbury, N. *Trans.* 1.

1898 RUSSELL, ALFRED ERNEST, M.D., B.S., 9, Wimpole Street, W. *C.C.* 1.

1900 RUSSELL, J. S. RISIEN, M.D., 44, Wimpole Street, Cavendish Square, W. *Trans.* 1, *C.C.* 1.

ELECTED

1903 RUSSELL, JAMES WILLIAM, M.D., 72, Newhall Street, Birmingham.
1887 RUTHERFOORD, H. T., M.B., Salisbury House, Taunton.
1885 RYLE, REGINALD JOHN, M.D., 15, German Place, Brighton.
1882 SAINSBURY, HARRINGTON, M.D., 52, Wimpole Street, W. (C. 1898–1901.)
1899 SANDIFER, HENRY STEPHEN, M.D., B.S., 11, Porchester Gardens, W.
1893 SANSOM, ARTHUR ERNEST, M.D., 84, Harley Street, W. *Trans.* 1, *C.C.* 1.
1873 SAVAGE, GEORGE HENRY, M.D., 3, Henrietta Street, W. (C. 1882–3.)
1886 SAVILL, THOMAS DIXON, M.D., 60, Upper Berkeley Street, W. *Trans.* 1, *C.C.* 6.
1899 SCHORSTEIN, GUSTAVE, M.B., 11, Portland Place, W.
1886 SCOTT, ALFRED, 15, German Place, Brighton.
1894 SCOTT, BERNARD, "Hartington," Poole Road, Bournemouth.
1892 SCOTT, RICHARD JAMES HERBERT, 28, Circus, Bath. *C.C.* 1.
1902 SEARS, ALFRED ERNEST, 33, Lee Terrace, Blackheath, S.E. *Trans.* 1.
1897 SEGUNDO, CHARLES SEMPILL DE, M.B., B.S., 6, Brook Street, Hanover Square, W.
1892 SELWYN-HARVEY, JOHN STEPHENSON, M.D., 1, Astwood Road, S.W.
1878 SEMON, Sir FELIX, C.V.O., M.D., 39, Wimpole Street, W. (C. 1885–7.) *Trans.* 8, *C.C.* 3.
1884 SHARKEY, SEYMOUR J., M.D., 22, Harley Street, W. (C. 1895–8.)
1898 SHAW, HAROLD BATTY, M.D., 7, Devonshire Street, Portland Place, W. *C.C.* 9.
1889 SHAW, LAURISTON ELGIE, M.D., 64, Harley Street, W. *C.C.* 1.
1906 SHEBBEN, JAMES, 40, Devonshire Street, Portland Place, W. *Trans.* 3.
1875 SHERWOOD, ARTHUR PAUL, 8, Seaside Road, Eastbourne.
1903 SIMPSON, GRAHAM, The Sheffield Royal Hospital, Sheffield. *Trans.* 1, *C.C.* 1.
1879 SKERRITT, EDWARD MARKHAM, M.D., Ivor House, Durdham Park, Clifton, Bristol. (C. 1895–8.) *Trans.* 2.
1872 SLIGHT, GEORGE, M.D., 14, Old Burlington Street, W.
1896 SMITH, EBENEZER STANLEY, M.D., 68, Wimpole Street, Cavendish Square, W.
1888 SMITH, FREDERICK J., M.D., 138, Harley Street, W. (C. 1905– .) *Trans.* 2.
1884 SMITH, R. PERCY, M.D., 36, Queen Anne Street, Cavendish Square, W. (C. 1898–1901.)
1894 SMITH, THOMAS RUDOLPH, M.B., B.C., 25, Bridge Road, Stockton-on-Tees.
1893 SNAPE, ERNEST ALFRED, M.D., 41, Welbeck Street, W.
1868 SNOW, WILLIAM V., M.D., Richmond Gardens, Bournemouth.
1890 SOLLY, ERNEST, M.B., Strathlea, Harrogate, Yorks. *C.C.* 1.

ELECTED

1888 SPENCER, WALTER GEORGE, M.S., M.B. (*Hon. Secretary*), 35, Brook Street, W. (C. 1896-9. S. 1904- .) *Trans.* 14, *C.C.* 17.

1885 SPICER, FREDERICK, M.D., 17, Wimpole Street, Cavendish Square, W.

1888 SPICER, ROBERT HENRY SCANES, M.D., 28, Welbeck Street, W. *C.C.* 1.

1882 SPOONER, FREDERICK HENRY, M.D., 4, Maitland Place, Lower Clapton, N.E.

1896 SPURRELL, CHARLES, Medical Superintendent, Poplar and Stepney Sick Asylum, Devon's Road, Bromley-by-Bow, E.

1876 SQUIRE, A. BALMANNO, 24, Weymouth Street, W. *Trans.* 5, *C.C.* 4.

1879 STAPLES, FRANCIS PATRICK, Brigade-Surgeon, Army (retired). (Address uncommunicated.)

1896 STEWARD, FRANCIS JAMES, M.B., B.S., 125, Harley Street, W. (C. 1906- .) *Trans.* 3, *C.C.* 1.

1874 Stirling, EDWARD C., M.D. [care of Messrs. ELDER & Co., 7, St. Helen's Place, E.C.], Adelaide, South Australia.

1899 STONE, WILLIAM GREAM, M.D., 93, Denmark Hill, S.E. *C.C.* 1.

1884 STONHAM, CHARLES, C.M.G., 4, Harley Street, W. *C.C.* 3.

1878 STRUGNELL, FREDERICK WILLIAM, Grove End House, Highgate Road, Highgate, N.W. (C. 1903-6.) *C.C.* 1.

1878 Sturge, WILLIAM ALLEN, M.D., 29, Boulevard Dubouchage, Nice, France.

1894 SUTHERLAND, GEORGE A., M.D., 73, Wimpole Street, Cavendish Square, W. (C. 1906- .) *Trans.* 1, *C.C.* 2.

1882 SYMONDS, CHARTERS JAMES, M.S. (*Trustee*), 58, Portland Place, W. (C. 1888-9, 1901-4, S. 1898-1901, V.P. 1906- .) *Trans.* 12, *C.C.* 23.

1876 SYMONDS, HORATIO PERCY, 35, Beaumont Street, Oxford.

1885 TAIT, EDWARD SABINE, M.D., 48, Highbury Park, N.

1885 TAIT, HENRY BREWER, Lincluden, Sunnyside Road, Hornsey Lane, N.

1891 TATE, WALTER WILLIAM HUNT, M.D., 32, Queen Anne Street, W.

1886 TAY, WAREN, 4, Finsbury Square, E.C.

1897 TAYLOR, E. CLAUDE, M.D., B.S., 181, Rosslyn Hill, Hampstead, N.W.

1875 TAYLOR, FREDERICK, M.D., 20, Wimpole Street, W. (S. 1879-81, C. 1882-4, V.P. 1894-7, T. 1901-3, P. 1903-5.) *Trans.* 17, *C.C.* 3.

1889 Taylor, HENRY HERBERT, 10, Brunswick Place, Hove, Sussex.

1890 TAYLOR, JAMES, M.D., 49, Welbeck Street, W. *C.C.* 3.

1882 TAYLOR, SEYMOUR, M.D., 16, Seymour Street, W. *Trans.* 1, *C.C.* 4.

1885 Taylor, W. C. EVERLEY, 34, Queen Street, Scarborough.

1886 TEALE, THOMAS PRIDGIN, M.B., F.R.S., 38, Cookridge Street, Leeds. (C. 1897-1900.)

1896 TEMPLETON, GEORGE, M.B., 10, Seymour Street, Portman Square, W.

1890 THANE, EDGAR HERBERT, M.D., Wagga-Wagga, New South Wales.

ELECTED

1886 THOMPSON, CHARLES HERBERT, M.D., 133, Harley Street, Cavendish Square, W. *C.C.* 1.

O.M. THOMPSON, EDMUND SYMES, M.D., 33, Cavendish Square, W. (C. 1880–2.) *Trans.* 1.

1897 THOMSON, H. CAMPBELL, M.D., 34, Queen Anne Street, Cavendish Square, W. *C.C.* 1.

1894 THOMSON, STCLAIR, M.D., 28, Queen Anne Street, W. *Trans.* 2, *C.C.* 9.

1896 THORNE, WILLIAM BEZLY, M.D., 2, Harley Street, W. *C.C.* 2.

1872 THORNTON, WILLIAM PUGIN, 35, St. George's Road, Canterbury. *Trans.* 5.

1885 THURSFIELD, THOMAS WILLIAM, M.D., Selwood, Beauchamp Square, Leamington.

1899 TILLEY, HERBERT, M.D., 89, Harley Street, Cavendish Square, W. *C.C.* 2.

1891 TOMSON, W. BOLTON, M.D., Park Street West, Luton, Bedfordshire.

1897 TOOGOOD, F. SHERMAN, M.D., The Infirmary, 282, High Street, Lewisham, S.E.

1892 TOOTH, HOWARD HENRY, C.M.G., M.D., 34, Harley Street, W. (C. 1905– .) *Trans.* 1.

1887 TOTSUKA, KANKAI, Tokio, Japan.

1897 TUBBY, ALFRED HERBERT, M.S., 25, Weymouth Street, Portland Place, W. (C. 1905– .) *Trans.* 2, *C.C.* 5.

1900 TULLIS, GEORGE AUGUSTUS, M.D., Holmbush, Grove Road, Southsea.

1904 TURNER, GEORGE GREY, 31, Oxford Street, Newcastle-on-Tyne.

1882 TURNER, GEORGE ROBERTSON, 41, Half Moon Street, W. (C. 1897–1900.) *Trans.* 9. *C.C.* 6.

1904 TURNER, PHILIP, M.S., 8, St. Thomas's Street, London Bridge, S.E.

1888 TURNER, PHILIP DYMOCK, M.D., Sudbury, Ryde, Isle of Wight. *Trans.* 2.

1898 TURNER, WILLIAM, M.S., 17, Harley Street, Cavendish Square, W. *C.C.* 1.

1893 TURNEY, HORACE GEORGE, M.D., 68, Portland Place, W. (C. 1906– .) *C.C.* 5.

1878 TYSON, WILLIAM JOSEPH, M.D., 10, Langhorne Gardens, Folkestone. (C. 1886–8, V.-P. 1900–2.) *Trans.* 8.

1881 UHTHOFF, JOHN CALDWELL, M.D., Wavertree House, Brunswick Place, Brighton. (C. 1898–1901.)

1868 VENNING, Sir EDGCOMBE, 30, Cadogan Place, S.W. (C. 1876–8.) *Trans.* 2.

1890 VOELCKER, ARTHUR FRANCIS, M.D., B.S., 101, Harley Street, W. (C. 1900–3.) *Trans.* 2, *C.C.* 4.

1868 WAGSTAFFE, WILLIAM WARWICK, Purleigh, St. John's Hill, Sevenoaks. (C. 1878.)

1886 **WAINEWRIGHT**, BENJAMIN, M.B., C.M. (address uncommunicated).

1885 WAKLEY, THOMAS, jun., 16, Hyde Park Gate, S.W.

1899 WALKER, HENRY ROE, 8, Harley Street, W.

ELECTED

1896 WALLACE, CUTHBERT SYDNEY, M.B., 26, Upper Wimpole Street, W. (C. 1902–5.) *Trans.* 8, *C.C.* 5.

1890 WALLIS, FREDERICK CHARLES, M.B., B.C., 107, Harley Street, W. (C. 1902–5.) *Trans.* 6, *C.C.* 10.

1888 WALTERS, FREDERICK RUFENACHT, M.D., Crooksbury Sanatorium, Farnham, Surrey. *C.C.* 2.

1896 WARD, EDWARD, M.B., 30, Park Square, Leeds. *Trans.* 1.

1904 WARING, HOLBURT J., M.S., 37, Wimpole Street, Cavendish Square, W.

1888 Warner, PERCY, Rydal, Woodford Green, Essex.

1891 WATERHOUSE, HERBERT FURNIVALL, M.D., C.M., 81, Wimpole Street, W. (C. 1905– .)

1902 WATSON, CHARLES GORDON, 44, Welbeck Street, Cavendish Square, W. *C.C.* 1.

1896 **WEBER**, FRED. PARKES, M.D., 19, Harley Street, W. *Trans.* 3, *C.C.* 12.

O.M. WEBER, Sir HERMANN D., M.D., 10, Grosvenor Street, W. (C. 1867–71, V.P. 1873–5.) *Trans.* 9.

1882 WEST, SAMUEL, M.D., 15, Wimpole Street, W. (C. 1887–9.) *Trans.* 17, *C.C.* 5.

1895 WETHERED, FRANK J., M.D., 83, Harley Street, W.

1874 WHEELHOUSE, CLAUDIUS GALEN, Cliffe Point, Filey, Yorks. *Trans.* 1.

1891 WHITE, CHARLES PERCIVAL, M.B., B.C., 22, Cadogan gardens, S.W.

1882 WHITE, EDWIN FRANCIS, Westlands, 280, Upper Richmond Road, Putney, S.W.

1890 WHITE, GILBERT B. MOWER, M.B., B.S., 112, Harley Street, W.

1883 WHITE, WILLIAM HALE, M.D. 65, Harley Street, W. (C. 1887–9, 1896–9, S. June, 1893–6, V.P. 1906– .) *Trans.* 17, *C.C.* 4.

1883 WHITE, WILLIAM HENRY, M.D., 43, Weymouth Street, W. *Trans.* 1. *C.C.* 1.

1894 WHITELOCKE, RICHARD HENRY ANGLIN, M.B., C.M., 6, Banbury Road, Oxford.

1897 WHITFIELD, ARTHUR, M.D., 21, Bentinck Street, Manchester Square, W.

1882 WHITTLE, EDWARD GEORGE, M.D., 9, Regency Square, Brighton.

1871 WIGHT, GEORGE, M.B., C.M., 428, Liverpool Road, N.

1879 WILCOX, HENRY, M.B., Newlyn, Fleet, Hants.

1894 **WILKIN**, GRIFFITH CHARLES, Conway House, Paignton, South Devon.

1884 WILLCOCKS, FREDERICK, M.D., 14, Mandeville Place, W. *C.C.* 1.

O.M. WILLETT, ALFRED, 26, Upper Wimpole Street, W. (C. 1872–5, V.P. 1889–91.) *C.C.* 2.

1888 WILLIAMS, CAMPBELL, 18, Queen Anne Street, Cavendish Square, W. *Trans.* 2.

O.M. WILLIAMS, CHARLES THEODORE, M.V.O., M.D., 2, Upper Brook Street, W. (C. 1877–9, V.P. 1889–90.) *Trans.* 8.

1888 WILLIAMS, DAWSON, M.D., 2, Agar Street, Strand, W.C. (C. 1893–7.)

ELECTED

1903 WILLIAMS, LEONARD, M.D., 8, York Street, Portman Square, W. *C.C.* 1

1890 WILLIAMS, W. ROGER, Beaufort House, Clifton Down, Clifton, Bristol.

O.M. WILLIS, FRANCIS, M.D., The Spa, Braceborough, Stamford.

1893 WILLS, JOSEPH PEARCE BUDGETT, M.D., Chintings, Bexhill-on-Sea.

1886 WILSON, ALBERT, M.D., 1, Belsize Park, N.W. *Trans.* 1, *C.C.* 2.

1888 Wilson, CLAUDE, M.D., C.M., Belmont, Tunbridge Wells. (C. 1905– .) *Trans.* 2.

1891 WILSON, THEODORE STACEY, M.D., C.M., 27, Wheeley's Road, Edgbaston, Birmingham. *Trans.* 2.

1905 WIRGMAN, C. WYNN, M.D., B.S., 45, Queen Anne Street, Cavendish Square, W.

1890 WOOD, NEVILLE, 42, Elvaston Place, Queen's Gate, S.W.

1879 WOODWARD, GEORGE P. M., M.D., Deputy Surgeon-General; Sydney, New South Wales.

1894 WOOLLETT, CHARLES JEROME, "Ambleside," Streatham, S.W.

1884 WORTS, EDWIN, 6, Trinity Street, Colchester.

1892 WYNTER, WALTER ESSEX, M.D., B.S., 27, Wimpole Street, Cavendish Square, W. *C.C.* 4.

1872 YEO, I. BURNEY, M.D., 44, Hertford Street, W. (C. 1881–3.) *Trans.* 8.

[*It is requested that any change of Title or Residence be communicated to the Secretaries before the* 1*st of July in each year, in order that the list may be made as correct as possible.*]

LIST OF MEMBERS.

ORIGINAL MEMBERS (ALPHABETICALLY).

Henry Arnott.
Richard Barwell.
Henry Charlton Bastian, M.D., F.R.S.
Sir Wm. Henry Broadbent, Bart., K.C.V.O., M.D., F.R.S.
Thomas Bryant.
Thomas Buzzard, M.D.
Sir William Selby Church, Bart., K.C.B., M.D.
Edward Clapton, M.D.
John Couper.
William Howship Dickinson, M.D.
Sir Dyce Duckworth, M.D.
Timothy Holmes.
Jonathan Hutchinson, F.R.S.
J. Hughlings Jackson, M.D., F.R.S.
John Langton.
Arthur Trehern Norton, C.B.
Frederick William Pavy, M.D., F.R.S.
Sir Richard Douglas Powell, Bart., K.C.V.O., M.D.
Sydney Ringer, M.D., F.R.S.
Sir Thomas Smith, Bart., K.C.V.O.
Edmund Symes Thompson, M.D.
Sir Hermann D. Weber, M.D.
Alfred Willett.
Charles Theodore Williams, M.D.
Francis Willis, M.D.

ARRANGED ACCORDING TO DATE OF ELECTION.

1868 Sir Constantine Holman, M.D.
Christian G. H. Bäumler, M.D.
James Grey Glover, M.D.
T. Henry Green, M.D.
Howard Marsh, M.C.
Charles Prentis.
Sir Edgcombe Venning.
John Ford Anderson, M.D.
1868 George Granville Bantock, M.D.
George Charles Bright, M.D.
Frank W. Cooper.
Edward Hooper May, M.D.
William Warwick Wagstaffe.
James Edward Pollock, M.D.
Franz Oppert, M.D.
William V. Snow, M.D.

1868 Charles Drage, M.D.
Frederick Royston Fairbank, M.D.
Michael W. Rice, M.D.
1869 J. Warrington Haward.
Henry Frederick Augustus Goodridge, M.D.
Olliver Thomas Duke, M.B.
1871 Alfred Playne, M.B.
George Wight, M.B.
Ebenezer Diver, M.D.
1872 I. Burney Yeo, M.D.
Henry Harris, M.D.
William Pugin Thornton.
Sir G. Anderson Critchett.
J. C. J. Fenwick, M.D.
Andrew S. Myrtle, M.D.
Sir William Bartlett Dalby, M.B.
Thomas Ridge Jones, M.D.
George Slight, M.D.
1873 William Julius Mickle, M.D.
David Lloyd Roberts, M.D.
George Henry Savage, M.D.
Edwin Chisholm, M.D.
Thomas Churton, M.D.
1874 John Hammond Morgan, C.V.O.
Edward R. Rowland.
Claudius Galen Wheelhouse.
Edward C. Stirling, M.D.
Sir William Henry Bennett, K.C.V.O.
William Brown Holderness.
Andrew Clark.
1875 Sir Thomas Barlow, Bart., K.C.V.O., M.D.
Sidney Coupland, M.D.
Clinton T. Dent.
C. D. B. Hale.
Rickman John Godlee, M.S.
Arthur Paul Sherwood.
James Frederic Goodhart, M.D.
Sir William Richard Gowers, M.D., F.R.S.
William Smith Greenfield, M.D.
Sir Shirley F. Murphy.
Herbert W. Page.
Frederick Taylor, M.D.
1876 Arthur E. J. Barker.
Horatio Percy Symonds.
A. Balmanno Squire.
David White Finlay, M.D.
Furneaux Jordan.
R. Clement Lucas, B.S.
George Buckston Browne.
1876 Arthur Edwin Temple Longhurst, M.D.
1877 Robert Hogarth Clay, M.D.
A. Pearce Gould, M.S.
Henry Radcliffe-Crocker, M.D.
David B. Lees, M.D.
William Ewart, M.D.
Henry Morris, M.B.
Henry Ambrose Lediard, M.D.
Bernard Roth.
Henry Hugh Clutton, M.C.
Malcolm Alex. Morris.
1878 George P. Field.
Thomas Warner Lacey.
Thomas Colcott Fox, M.B.
Sir Felix Semon, C.V.O., M.D.
Henry de Fonmartin, M.D.
C. H. Golding-Bird, M.B.
Donald William Charles Hood, M.D.
Lord Lister, P.C., O.M., F.R.S.
F. de Havilland Hall, M.D.
William Allen Sturge, M.D.
William Joseph Tyson, M.D.
Charles Robert Bell Keetley.
William Appleton Meredith, C.M.
Robert Bridges, M.B., M.A.
Frederick William Strugnell.
1879 William Edward Burton.
James Magill, M.D.
Edward Markham Skerritt, M.D.
Henry Wilcox, M.B.
Sir Stephen Mackenzie, M.D.
William Harrison Cripps.
Francis Patrick Staples.
Geo. Courtenay Henderson, M.D.
Henry Davy.
Thos. Walter Harropp Garstang.
Charles W. Mansell Moullin.
John Reuben Lunn.
George P. M. Woodward, M.D.
Robert Peel.
Frederic S. Dennis, M.D.
1880 T. Mark Hovell.
Henry Francis Baker.
Bernard O'Connor, M.D.
Charles Edward Beevor, M.D.
1881 George Henry Makins, C.B.
Robert William Burnet, M.D.
James Kingston Fowler, M.D.
Charles Edward Harrison, M.B.
Malcolm Macdonald McHardy.
Rushton Parker.

1881 Montagu Lubbock, M.D.
William Pasteur, M.D.
John Caldwell Uhthoff, M.D.
Henry Trentham Butlin.
H. A. Powell, M.A.

1882 George Robertson Turner.
Robert William Goldie.
Frederick Charles Barker, M.D.
Daniel Colquhoun, M.D.
Seymour Taylor, M.D.
Philip Henry Bindley, M.B.
Edward George Whittle, M.D.
D. H. Goodsall.
Frederick Henry Spooner, M.D.
Frederick Haycraft Berry, M.D.
Herbert Collier, M.D.
Samuel West, M.D.
Emile Emond, M.D.
Charters James Symonds, M.S.
C. F. Coxwell, M.B.
Augustus Joseph Pepper, M.B.
Harrington Sainsbury, M.D.
Edwin Francis White.

1883 Anthony A. Bowlby, C.M.G.
Percy Kidd, M.D.
William Henry White, M.D.
Hubert Montague Murray, M.D.
Robert Fitzroy Benham.
William Henry Allchin, M.D.
John Mitchell Bruce, M.D.
William Arbuthnot Lane, M.S.
Bernard Pitts.
William Hale White, M.D.
William Coode Adams, M.B.
Robert Leamon Bowles, M.D.
George Henry Jackson.
Thomas Laurence Read.
Frederick Thomas Roberts, M.D.
Charles Alfred Ballance, M.B., M.S.

1884 Frederick Willcocks, M.D.
R. Percy Smith, M.D.
Edgar Duke.
John Mackern, M.B.
Paul M. Chapman, M.D.
Wilmot Parker Herringham, M.D.
Philip Henry Pye-Smith, M.D., F.R.S.
Charles Stonham, C.M.G.
Dudley Wilmot Buxton, M.D.
Edwin Worts.
Seymour J. Sharkey, M.D.
John James Pringle, M.B.

1884 Frederick Lucas Benham, M.D.
Walter Edmunds, M.C.
Stephen Paget.
Sir Lambert Hepenstal Ormsby, M.D.
Edwin Leonard Adeney, M.D.
Sir Victor Horsley, F.R.S.
Henry Carr Maudsley, M.D.
Bilton Pollard, B.S.

1885 Frederick Spicer, M.B.
Herbert Larder.
James Berry, B.S.
Fred. Walker Mott, M.D., F.R.S.
George Newton Pitt, M.D.
W. C. Everley Taylor.
Sidney Phillips, M.D.
A. W. Mayo Robson.
Thomas Wakley, jun.
Herbert William Allingham.
Thomas William Thursfield, M.D.
Alexander Dalton Murray, M.B.
Robert Maguire, M.D.
Robert Alexander Gibbons, M.D.
Henry Brewer Tait.
Richard Caton, M.D.
Arthur Henry Robinson, M.D.
Edward Sabine Tait, M.B.
William Bruce Clarke, M.B.
Charles Barrett Lockwood.
Reginald J. Ryle, M.D.
J. Michell Clarke, M.D.
Henry George Armstrong.
Roderick Maclaren, M.D.
W. Watson Cheyne, C.B., F.R.S.

1886 Thomas Dixon Savill, M.D.
Benjamin Wainewright, M.B.
Waren Tay.
William Henry Battle.
James Hardie, M.D.
Francis Henry Hawkins, M.D.
R. Hingston Fox, M.D.
John Ward Cousins, M.D.
T. Pridgin Teale, F.R.S.
H. Lankester, M.D.
Charles Herbert Thompson, M.D.
Henry Handford, M.D.
Alfred Scott.
Albert Wilson, M.D.

1887 Archibald E. Garrod, M.D.
H. T. Rutherfoord, M.B.
Kankai Totsuka.
Thomas Oliver, M.D.
Samuel Herbert Habershon, M.D.

1887 Oswald Auchinleck Browne, M.D.
Joseph Arderne Ormerod, M.D.
J. H. E. Brock, M.D., B.S.
Francis William Clark.
A. H. Weiss Clemow, M.D., C.M.
E. Hurry Fenwick.
R. Lawford Knaggs, B.C.
John D. Malcolm, M.B., C.M.
Sidney Martin, M.D., B.S., F.R.S.
Thomas Horrocks Openshaw, C.M.G., M.B.

1888 A. G. Barrs, M.D.
J. W. Batterham, M.B., B.S.
Montagu Handfield-Jones, M.D.
Alfred Rice Oxley, M.D.
Robert Henry Scanes Spicer, M.D.
Campbell Williams.
Frederic S. Eve.
Alexander Morison, M.D.
Frederick Page, M.D.
Frederick J. Smith, M.D.
Frederick R. Walters, M.D.
Claude Wilson, M.D., C.M.
Charles H. Gage-Brown, M.D.
J. H. Menzies.
Frank Ernest Roberts.
Hugh Armstrong.
Hyde Marriott, M.B.
Percy Warner.
J. T. James, M.D.
Edwin A. Barton.
W. Page May, M.D.
Philip D. Turner, M.D.
Dawson Williams, M.D.
Augustus W. Addinsell, M.B., C.M.
John Anderson, C.I.E., M.D.
Henry French Banham, M.D.
David James Mason, M.D., C.M.
Walter G. Spencer, M.B., M.S.

1889 Theodore Dyke Acland, M.D.
Raymond Johnson, M.B., B.S.
H. D. Rolleston, M.A., M.D.
P. MacBride, M.D.
D. Newman, M.D.
Herbert Elwin Harris, M.B.
John E. Ranking, M.D.
Edward Ashby Fardon.
Stanley Boyd, B.S.
George Ezra Halstead, M.D., B.S.
Henry Herbert Taylor.
John Duncan, M.D.

1889 Wm. Wallis Ord, M.D., B.Ch.
Leonard Arthur Bidwell.
Arthur J. M. Bentley, M.D.
Francis R. B. Bisshopp, M.D., B.Sc.
Henry Percy Dean, M.B.
Louis Albert Dunn, M.S.
Herbert Pennell Hawkins, M.D., B.Ch.
Lauriston Elgie Shaw, M.D.

1890 John Rose Bradford, M.D., F.R.S.
J. Fletcher Little, M.B.
Robert Robertson, M.D.
Ernest Solly, M.B.
James Taylor, M.D.
Francis O. Buckland, B.A., M.B. C.M.
Edmund W. Roughton, B.S.
James Calvert, M.D.
H. Roxburgh Fuller, M.D.
Arthur F. Voelcker, M.D.
Neville Wood.
W. Roger Williams.
Gilbert B. M. White, M.B., B.S.
Frederick Charles Wallis, M.B., B.C.
Alfred Parkin, M.S.
George A. Hawkins-Ambler.
James Harper, M.D.
Walter Henry Brown.
John Walter Carr, M.D.
Ernest Le Cronier Lancaster, M.B., B.Ch.
Sir Patrick Manson, K.C.M.G., M.D., F.R.S.
Miles Miley, M.A., M.B.
Edgar Herbert Thane, M.B.
Charles William Chapman, M.D.
Michael G. Foster, M.A., M.D.

1891 Frederic François Burghard, M.D., M.S.
Roger Neville Goodman, M.B.
Herbert Furnivall Waterhouse, M.D., C.M.
Walter William Hunt Tate, M.D.
Greville MacDonald, M.D.
J. Kingston Barton.
J. Dundas Grant, M.D.
W. Kington Fyffe, M.B., B.C.
Albert Carless, M.B., M.S.
W. Bolton Tomson, M.D.
Harry Littlewood, M.D.

1891 Hector W. G. Mackenzie, M.A., M.D.
Chas. Percival White, M.B., B.C.
Arnold Caddy.
Theodore Stacey Wilson, M.D., C.M.
1892 William Hunter, M.D.
Frank Thomas Paul.
Walter Essex Wynter, M.D., B.S.
Damer Harrison.
John Alfred Masters, M.D.
Walter Gifford Nash.
John Stephenson Selwyn-Harvey, M.D.
Edward John Lewis, M.B., B.C.
Henry Betham Robinson, M.D. M.S.
Richard James Herbert Scott.
Howard Henry Tooth, C.M.G., M.D.
1893 John Ernest Paul, M.B.
James William Bond, M.D.
Harry Campbell, M.D.
W. Soltau Fenwick, M.D.
Ernest Alfred Snape, M.D.
Lewis G. Glover, M.B., B.C.
William Bracewell Mercer, M.B., B.C.
Robert Henry Cole, M.D.
Donald Rose Paterson, M.D., C.M.
Walter Spencer Anderson Griffith, M.D.
Alfred Theodore Rake, M.B., B.S.
James William Browne, M.B.
George Redmayne Murray, M.D., M.A.
R. J. Bliss Howard, M.D.
Henry Jones Curtis, M.D., B.S.
Henry Albert Caley, M.D.
John Henry Dauber, M.B.
Theodore Henry Ionides, M.B., B.S.
Arthur Foxwell, M.D.
Horace George Turney, M.D.
Henry Grabham Lys, M.D.
Arthur Ernest Sansom, M.D.
G. F. Johnston, M.D.
Willmott H. Evans, M.D., B.S.
Charles Gibbs.
Robert Stephen Charsley.
Joseph Pearce Budgett Wills, M.D.
Arnold Lawson, M.D.
1894 Herbert Morley Fletcher, M.D.
Edward Wilberforce Goodall, M.D.
Harry Gilbert Barling.
Ernst Michels, M.D.
Charles Jerome Woollett.
StClair Thomson, M.D.
George A. Sutherland, M.D.
John Murray.
Richard Henry Anglin Whitelocke, M.B., C.M.
John Attlee, M.D., B.C.
Griffith Charles Wilkin.
Thomas Hugh Dickson, M.B., B.C.
C. Gordon Brodie.
Bernard Scott.
John Porter Parkinson, M.D.
Thomas Rudolph Smith, M.B., B.C.
Arthur Pearson Luff, M.D.
1895 Herbert Murray Ramsay.
Arthur G. Phear, M.D., B.C.
Ernest E. Lewis, M.D.
Karl Grube, M.D.
Gerald R. Baldwin.
James Galloway, M.D.
F. B. Willmer Phillips, M.B.
Charles Henry Hough.
Leonard George Guthrie, M.D.
James Ernest Lane.
Frank J. Wethered, M.D.
Richard Ackerley.
1896 Charles Spurrell.
Cuthbert Sidney Wallace, M.B.
Charles R. Box, M.D.
Walter Stacy Colman, M.D.
Edward Ward, M.B.
Norman Dalton, M.D.
Fred. Parkes Weber, M.D.
Francis James Steward, M.B., B.S.
William Bezly Thorne, M.D.
Douglas Drew, M.D., B.S.
Surg.-Capt. W. R. Crooke-Lawless, A.M.S., M.D.
William Elliot Risdon, M.D.
Priestley Leech, M.D.
Ebenezer Stanley Smith, M.D.
Edward Cooper Bentham.
Robert Herbert Mills-Roberts, C.M.G.
Jonathan Hutchinson, jun.
Frederick E. Batten, M.D.
Rutherford John Pye-Smith.
George Templeton.

1896 Bertram Louis Abrahams, M.B., B.Sc.
1897 Raymond H. P. Crawfurd, M.D.
John Henry Deane.
Percy Furnivall.
Arthur Whitfield, M.D.
Frederick William Forbes Ross, M.D.
Harold Low, M.B.
Charles Ralph Keyser.
George Bertram Hunt, M.B.
Alfred Herbert Tubby, M.S.
Charles Lamplough.
H. Campbell Thomson, M.D.
F. Sherman Toogood, M.D.
E. Claude Taylor, M.D.
Charles Humphrys.
Charles Sempill de Segundo, M.B.
Sir Alfred Downing Fripp, C.B., M.V.O., M.S.
Chichester Gould May, M.D.
1898 J. J. Perkins, M.D.
James Jackson Clarke, M.B.
Ernest Herbert Cobb.
Sydney Backhouse Hulke.
Thomas Herbert Kellock.
William Darley-Hartley.
Robert Jones.
Arthur Philip Beddard, M.D.
Alfred Ernest Russell, M.D., B.S.
William Cecil Bosanquet, M.D.
Jonathan F. C. H. Macready.
Arthur A. H. Partridge, M.B., M.Ch.
Leonard Avery.
Herbert Challice Crouch.
William Turner, M.B., B.S.
Harold Batty Shaw, M.D.
Joseph Stewart Richards, M.D., B.S.
William Henry Breffit Brook, M.D., B.S.
1899 George Edward Rennie, M.D.
V. Warren Low, M.D., B.S.
Rayner Derry Batten, M.D., B.S.
Charles E. Forbes Mouat-Biggs.
Rutherford Morison.
R. Murray Leslie, M.D.
Herbert Tilley, M.D.
Charles Owen Fowler, M.D.
Cyril Ogle, M.B.
1899 Charles Herbert Fagge, M.S.
Claude Somerville Hawkes.
Henry Stephen Sandifer, M.D., B.S.
Marcus Marwood Bowlan, M.B., B.Sc.
Alfred Eïd, M.D.
Karl Fürth, M.D.
Wm. Gream Stone, M.D.
Andrew Duncan, M.D.
Edmond Lucien De Chazal, M.D.
Henry Roe Walker.
Gustave Schorstein, M.B.
Edward Collingwood Andrews, M.D.
1900 Berkeley George Andrew Moynihan, M.S.
Harry Cooper, M.D.
George Augustus Tullis, M.D.
Griffith Lloyd Roberts, M.B., C.M.
Edward Percy Paton, M.S.
John Arthur Hayward, M.D.
Wilfred J. Hadley, M.D.
John Fawcett, M.D.
Arthur Bousfield, M.B.
J. S. Risien Russell, M.D.
Cecil H. Leaf, M.B.
Josef Paul zum Busch, M.D.
1901 Ernest George Leopold Goffe, M.D.
Arthur Hamilton Nicholson Lewers, M.D.
Charles Reissmann, M.D.
Adrian Caddy, M.B.
Herbert William Carson.
Thomas Henry Morse.
Laurie Hugh McGavin.
F. U. Menzies.
Thomas Rupert Hampden Bucknall, M.S.
Edward Angas Johnson, M.B.
Percival Horton-Smith Hartley, M.D.
Sir Hugh Reeve Beevor, Bart., M.D.
Theo. N. Kelynack, M.D.
Thomas Carwardine, M.S.
Bowie Campbell Gowan.
John J. Douglas, M.D.
Harold Shuttleworth Barwell.
1902 Charles Henry Fennell, M.D.

1902 Harold L. Barnard
Thomas Percy Legg, M.B.
Andrew Elliot, M.D.
Sir James Reid, Bart., G.C.V.O., K.C.B.
F. W. Price, M.B.
Alfred Ernest Sears.
Reginald F. Jowers.
Cecil Marriott, M.B.
Edward Farquhar Buzzard, M.D.
Donald John Armour, M.B.
Edred Moss Corner, B.Sc., M.B.
Herbert French, M.D.
Lawrence Jones, M.B.
Thomas Crisp English.
Walter Fedde Fedden, M.B.
David Nabarro, M.D.
Charles A. Morton.
Victor Evelyn Collins, M.B.
Leonard S. Dudgeon.
R. O. Moon, M.D.
Charles Gordon Watson.
Charles Firmin Cuthbert.

1903 Raoul Ernest Delbruck, M.B.
Clive Riviere, M.D.
Edward A. Gates, M.D.
E. Graham Little, M.D.
Percy Robert Cooper, M.D., B.Sc.
Leonard Williams, M.D.
Ernest Lloyd Jones, M.D.
John Basil Hall, M.C.
Thomas Reuell Atkinson, M.D.
Graham Simpson.
Edgar Beaumont.
James William Russell, M.D.
Philip Maynard Heath, M.B.

1903 Wilfred Harris, M.D.
Arthur S. Morley.
Hugh Rigby, M.S.

1904 Holburt J. Waring, M.S.
Charles Bolton, M.D.
R. P. Rowlands, M.S.
H. A. Ballance, M.S.
Frederic W. Longhurst.
H. S. D. Browne, M.B., B.C.
Philip Turner, M.S.
George Herbert Graham, M.D.
George Grey Turner, M.B., M.S.
John English Harburn.
Oswald Lacy Addison, M.B.
A. Ernest Jones, M.D., B.Sc.

1905 Harold A. T. Fairbank, M.S.
David Forsyth, M.D.
E. Rock Carling, M.B., B.S.
Joseph Cunning, M.B., B.S.
William Henry Bailey, M.D., D.P.H.
James Mear Brydone, M.B., B.C.
Francis Frederick Muecke, M.B., B.S.
William Frederick Brook
Joseph Arthur Arkwright, M.D., B.C.
William Henry Blake, M.D.
John Paul Roughton.
C. Wynn Wirgman, M.D., B.S.

1906 Cecil Rowntree, B.S.
Reginald George Hann.
John Roger Charles, M.D.
J. H. Drysdale, M.D.
James Sherren.

REPORT

OF THE

COUNCIL OF THE CLINICAL SOCIETY,

MAY, 1906.

THE principal feature of interest in the history of the Society during the past year has been the part taken by the Council in the question of the proposal for Amalgamation. As an outcome of these deliberations a Special General Meeting of the Society was held on November 21st, 1905, at which the following resolution was proposed, seconded and duly carried :—

> "This Special General Meeting of the Clinical Society expresses its concurrence with the Resolution adopted by the Council of the Society in favour of the Amalgamation of the various Medical Societies of London, provided that the scheme proposed prove to be financially feasible."

The number and quality of papers read have been well up to the average, and the cases shown on clinical evenings have elicited great attention and interest on the part of members who came to inspect them.

The Society has lost by death four Honorary Members, Sir John Burdon Sanderson (also a Trustee), Mr. Christopher Heath, Professor Hermann Nothnagel, Professor Johann Mikulicz-Radecki, and one Ordinary Member, Dr. William Ogle (of Derby).

Thirteen Ordinary Members have been elected, and eleven members have resigned membership. There are 15 Honorary and 589 Ordinary Members at the present time.

THE CLINICAL SOCIETY OF LONDON.

Statement of Cash Receipts and Payments from the 1st May, 1905, to the 30th April, 1906.

G. H. MAKINS, Esq., C.B., *Treasurer.*

RECEIPTS.	£	s.	d.	£	s.	d.
Balance, 1st May, 1905				102	3	2
186 Subscriptions at £1 1s. received by Collector	£195	6	0			
159 Subscriptions at £1 1s. received by Bank	166	19	0			
345				362	5	0
21 Subscriptions at 10s. 6d. received by Collector	11	0	6			
1 Subscription at 10s. 6d. received by Bank	0	10	6			
				11	11	0
8 Admission Fees at £2 2s.				16	16	0
5 „ „ at £1 1s.				5	5	0
1 Composition Fee				2	2	0
Sale of *Transactions*				12	5	11
Dividend on Consols (£668 18s. 2d).				15	11	2
				£527	19	3

PAYMENTS.	£	s.	d.	£	s.	d.
Cost of *Transactions*, Vol. XXXVIII:						
Printing, paper, binding, delivery, &c.	£143	11	5			
Illustrations	62	3	9			
				205	15	2
Meetings:						
Rent of Rooms	105	0	0			
Hire of Microscopes and Lantern	5	6	0			
Hire of Epidiascope	2	12	0			
Report of Committee *re* Amalgamation of Societies	2	5	10			
A. Tapson (attendance)	5	0	0			
Refreshments	33	8	0			
				153	11	10
Treasurer and Hon. Secretaries:						
Secretarial assistance	26	5	0			
Commission to Collector	15	15	0			
				42	0	0
Printing and Stationery				66	17	3
Subscription returned				1	1	0
Bank Charges				0	4	2
Petty Cash Expenditure				12	19	0
Balances:						
At Bank	42	16	7			
Petty Cash	2	14	3			
				45	10	10
				£527	19	3

H. H. CLUTTON, *President.*
G. H. MAKINS, *Treasurer.*
WALTER G. SPENCER, *Hon. Secretary.*

Examined with the vouchers and found correct,
G. A. SUTHERLAND,
CAMPBELL WILLIAMS, } *Auditors.*
May 8th, 1906.

COMMUNICATIONS.

I.—*The Cystoscope in Diagnoses of Diseases of the Bladder and Kidneys. Lesions Illustrated by an Opaque Projector.* By DAVID NEWMAN, M.D., F.F.P.S.G.Glasgow. *Read October* 13, 1905.

IT is not my purpose to read a formal paper this evening, but to endeavour to demonstrate the morbid aspects of the urinary bladder, with special reference to the cystoscopic appearances presented by the mucous membrane of the trigon and the orifices of the ureters in certain diseases of the kidney. I shall do so by reference to cases and will show you on the screen of the opaque projector the appearances as nearly as I can reproduce them artificially. I shall in the first instance ask your attention to the cystoscope I use and to the method I employ in fixing the locality and measuring the area of a lesion. Then I will show you the appearances of a healthy bladder and demonstrate some of the most obvious lesions, such as hyperæmia, tuberculous ulceration, varicose veins, stone partly hidden by an enlarged prostate, stone at the orifice of the ureter, papilloma and fibroma, and afterwards the appearances of the orifices of the ureters observed in renal calculus, tuberculous kidney, pyonephrosis, acute ascending ureteritis, and I will show you shoots occurring in hæmaturia and pyuria.

It may be of interest to you to see my original electric cystoscope (January 18, 1883) which is still armed with the first electric lamp introduced into a human bladder. Edison's incandescent lamp had just been patented, and one or two of them were sent to Glasgow for Sir William Thomson (Lord Kelvin). The late Mr. White showed them to me at the time I was struggling with the difficulties of cystoscopy

with reflected light and I at once appreciated the value of direct illumination. Having procured a lamp (Fig. 1, F and A), I had it fixed at the end of a thin rod E through which run the wires C and D from two Grove cells, and supplying a current sufficient for a one candle-power lamp. The rest of the apparatus consists of a speculum and the catheters. The speculum is represented in Figs. 2 and 3. It is a hollow cone, made of

FIG 1.

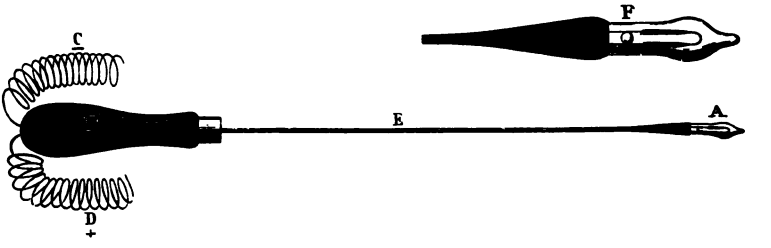

vulcanite, the apex (H and J) of which is movable, and the small end of the remaining portion (G) is closed with a small glass disc. The apex is rotated out of its place by a handle (L).

The method of using these instruments is as follows: "The bladder is first washed out with a warm solution of boracic acid, so as to remove all the urine. It is now distended with eight ounces of the boracic acid solution, and the electric

FIG. 2.

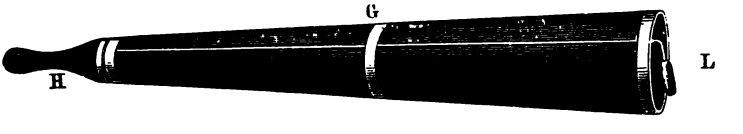

lamp is introduced through the urethra without being connected with the battery. It is important that the lamp should be introduced before the circuit is completed, as if this precaution be not taken the lamp is apt to become heated and may crack when it is passed into the fluid contents of the bladder. Two gum-elastic catheters (No. 2) should now be passed, and after them the speculum is introduced with the cover (H) in position as represented in Fig. 2. The current is now passed through the lamp, the cover (J) of the speculum is rotated, as represented in Fig. 3, and on inspec-

tion the structures forming the floor of the bladder are easily seen. The speculum should be passed so far into the bladder that the small end closed by the glass disc is about a quarter of an inch beyond the inner orifice of the urethra. The ureters are easily seen, and may be catheterised. The bladder is then allowed to empty itself, the catheters being retained in position, and the urine drawn off from each kidney separately. This method is, of course, only applicable to female patients, but may be used for any purpose where it is found necessary to examine the interior of the bladder.

When the bladder is well illuminated, the orifices of the ureters are easily seen, as narrow, oblique, slit-like openings, about two inches apart from each other. These openings are situated at the posterior angle of the trigon, nearly an inch and a half from the inner orifices of the urethra, and are united by a curved elevation, which, however, extends a little

FIG. 3.

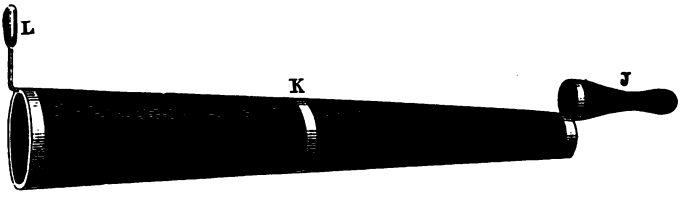

beyond them. The elevation referred to corresponds in position to the anterior lip of the os uteri externum."*

With this simple apparatus I succeeded in studying the appearance of the orifices of the ureters under various conditions of health and disease and recognised a point of considerable importance in diagnosis, namely that "When there is distinct evidence of irritation of the orifice of one ureter, while the other is normal in appearance, it may be safely inferred that the renal lesion is, if unilateral, on the side of the morbid ureter." Since 1883 great changes have taken place. The cystoscope I now show you is the one I use, and it fulfils the following requirements: (1) Comparatively small lumen of the stem, so that the instrument may be introduced without injury to the urethra or to the neck of the bladder; (2) large field of vision and a clear view; (3) easy means of clearing the field, should it become obscure, without removing the stem of the instrument from the

* *The Diagnosis of Disease of the Kidney amenable to Surgical Treatment*, p. 26.

FIG. 4.

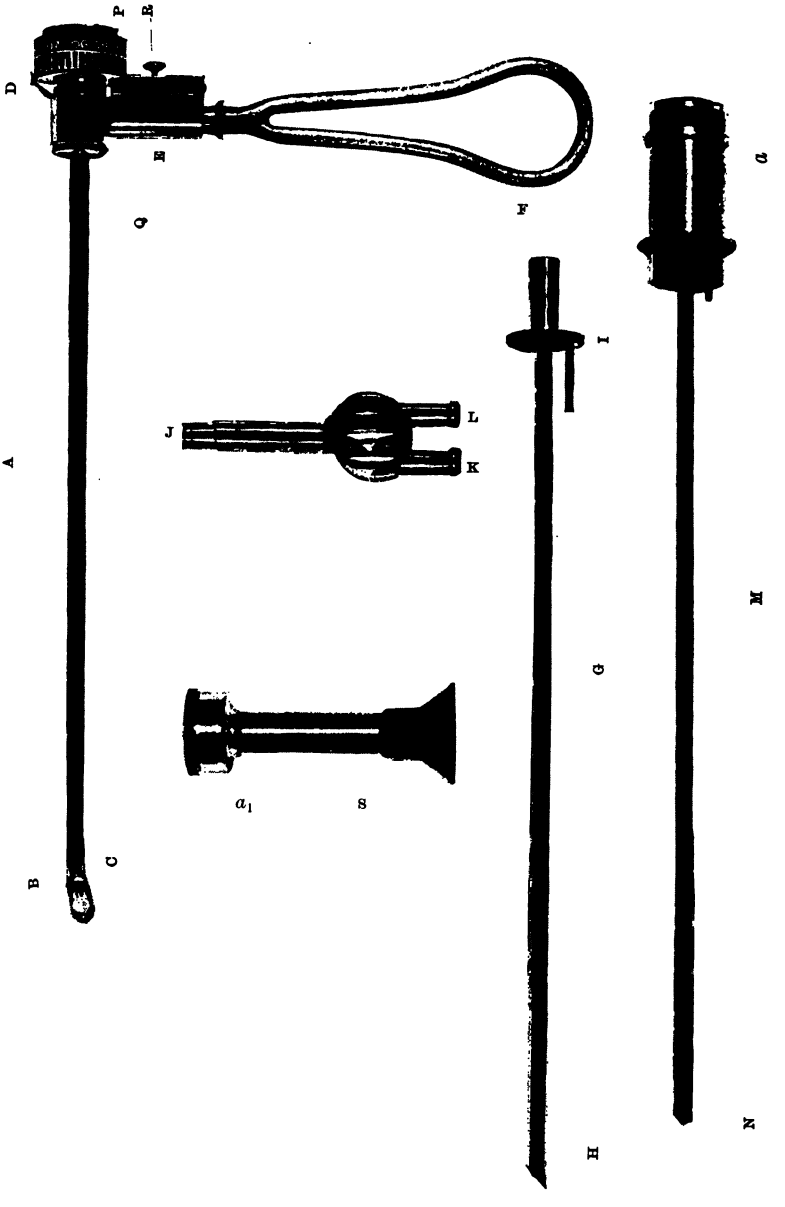

FIG. 4 (*continued*).



bladder; (4) good illumination without danger of scalding the mucous membrane of the bladder; (5) ease in sterilising the instrument; (6) facility in emptying the bladder, should there be clamant call to urinate, without necessitating the removal of the cystoscope: and (7) ability to demonstrate to a second observer the object seen; (8) means of steadying the instrument while an examination is being made, of fixing the prism of the cystoscope at any particular point, and of defining clearly the position of the lesion.

The cystoscope (Figs. 4, 5) consists of two distinct parts, a hollow stem (A) which is introduced into the bladder and retained there as long as may be required, and accessory parts which are used for cleansing the bladder or for observation. The former has at one end of the stem a cold electric lamp (B) (Löwenstein's), and immediately behind the lamp is a window (C). At the other end of the stem is a pack-box (D) and a collar marked by the degrees of a circle. Passing from the pack-box at right angles is a piece of metal with a slot in it in which a movable handle (F) may be fixed. Before the cystoscope is introduced the tube (G) is passed into the stem (A) so that the part (H) acts as a shutter to the window (C). After the cystoscope has entered the bladder, the tube (G) is rotated half a circle or slightly withdrawn, and the cystoscope is converted into a wash-out catheter. The double action stopcock (J) should then be fixed to the tube (I) so as to regulate the direction of the flow of fluid. A rubber tube leading to the limb (K) should contain solution under fluid-pressure

of a two-feet column (Fig. 5); while a rubber tube leading from (L) should contain fluid having suction of a two-feet fall, the former for ingress, the latter for egress of solution from

Fig. 5.

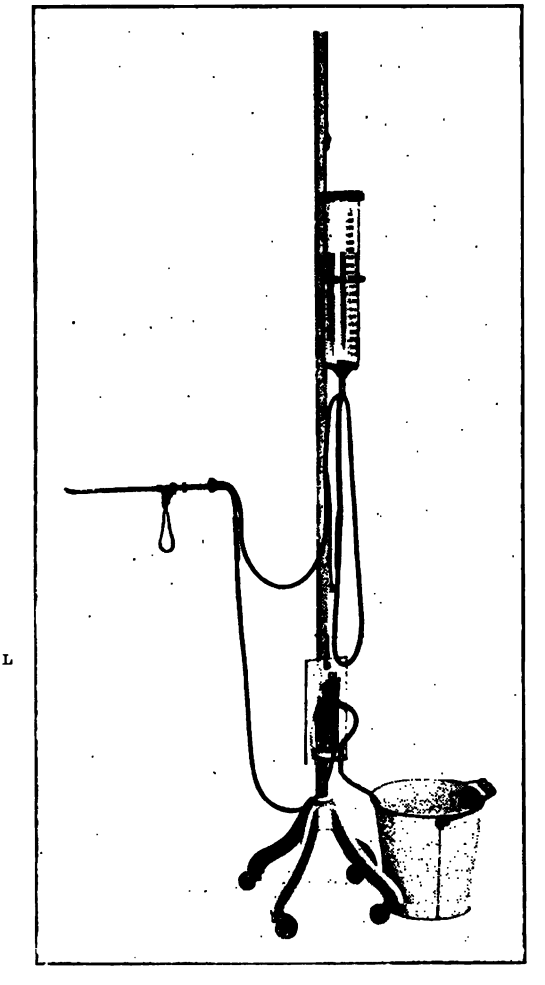

bladder. This part of the apparatus practically affords a wash-out catheter by which the bladder is cleansed prior to the introduction of the telescope (M) so that the prism (N)

comes to be immediately opposite the window (C). The electrodes are introduced into the openings (O) and (P) and the circuit completed by pressing the switch (R) against the body of the cystoscope, the lamp is lighted and the observation made. Should the fluid become opaque before the examination is completed, the bladder may be re-washed by withdrawing the telescope and re-introducing the tube (G) without moving the stem of the instrument from the urethra. To prevent the solution from escaping during the withdrawal of the auxiliary parts of the cystoscope there is a valve at (Q).

This instrument differs from the ordinary cystoscope also in that two eye-pieces may be screwed on to the telescope (*a*), one (S) single, the other (T) a double eye-piece. In the latter the image is reflected into the second eye-piece at right angles to the shaft of the telescope, so that a student can look through the second eye-piece (*x*) while his instructor is making observations through the first eye-piece (*y*). The surgeon seats himself in front of the patient in the usual way, and while he is making an inspection of the bladder and describing it to the student, each feature presented is as clearly seen by the second party as by the first. This invention greatly facilitates instruction in cystoscopy. The instrument is also adapted to define very clearly the position of a lesion. The method of doing this I shall describe presently. The cystoscope is pre-eminently an instrument for looking with and to teach the method of using it we must appeal to the eye more than to the ear. I shall, therefore, endeavour to give you some idea by means of this model of what is seen on looking into a healthy bladder.

At the back of the projector I have placed a disc with an opening three inches in diameter, so that only a portion of this large diagram is illuminated at one time and its image thrown upon the screen. By moving the diagram I can show you in the model cystoscope the appearance of the mucous membrane bit by bit just as it is seen in making an inspection with the cystoscope. When the cystoscope is passed into the bladder, the prism is directed forwards in relationship to the patient, but upwards in relationship to the horizon, so that when the light is turned on the first object which attracts attention is an air-bubble, and, as I shall show you presently, it is a most useful guide in locating lesions. If the patient is lying straight on his back, the air-bubble is in contact with the most anterior portion of the bladder in the middle line. I now move the diagram so as to show you the conditions

presented when the cystoscope is rotated to the observer's left, but from left to right in relation to the patient. The mucous membrane is of a pale pink colour, ramified by arterioles, and, the bladder being distended with only eight ounces of fluid, folds of mucous membrane are distinctly seen. The ridges of the trigon are also well marked, and their lips being thick and pronounced, the orifices of the ureters are easily detected. The area of the trigon is smooth, almost free from blood-vessels, and paler in colour than the rest of the mucous membrane. So far as you have seen the bladder is normal, but if we make a further examination we find an ulcer covered by a white slough.

How are we to locate the position of the lesion? It is clearly not on the floor of the bladder and it is not on the anterior wall. It first comes into view when the cystoscope is rotated some distance to the right of the perpendicular. As the view obtained by the cystoscope includes about 75 per cent. of a circle or sphere, it is impossible to define for descriptive purposes the limits of the ulcer unless an exact method be followed. I have had considerable difficulty in finding a method for recording the situation and extent of lesions. The sphere of a bladder might be divided as the face of a clock, and we might speak of an ulcer occupying a space corresponding to four o'clock; or a circle might be made similar to the mariner's compass and we might record the ulcer as being S.E. by E., but I fear to a landsman that would not convey a very clear idea.

The plan I have adopted I will explain in a few words. You will observe immediately opposite the handle (Fig. 4) and fixed to the metal collar within which the cystoscope rotates, there is a small pointer (w). It corresponds in position to a hair line in the cystoscope which is thrown on the prism. This is illustrated in the model. On making the examination the handle is allowed to rest upon the operating table or is held by an assistant and is maintained in a perpendicular position so that the pointer corresponds exactly to the middle line in front. This point, which we may call the meridian, is fixed. The circumference of the disc is graduated into 180° from right to left, and from left to right of the meridian, so that when the stem (Fig. 4) of the cystoscope is turned round to the *patient's* right the number of degrees of rotation to the right are recorded on the register by the pointer. Making the scale 180° to the right and to the left of the meridian incurs a danger of mistakes in recording, the observer's right being

PLATE I.

Illustrating Dr. David Newman's paper on the Cystoscope in Diagnoses of Diseases of the Bladder and Kidneys.

Fig. 1.

Fig. 2.

Fig. 3.

Fig. 4.

Fig. 5.

Fig. 6.

Bale & Danielsson, Ltd. lith.

substituted for that of the patient, an error very easily made; but to obviate this error I have the disc coloured, one hemisphere, the right, green, starboard according to ship's lights, and red, port, indicating the left hemisphere; that is to say, when the prism is looking towards the right side of the bladder, the pointer is covering a portion of the green semicircle, whereas when the prism is looking towards the left hemisphere of the bladder the pointer is covering a portion of the red hemisphere of the circle register. By this method not only are we enabled to fix the exact position, but we are also afforded a means of defining its limits and recording with some degree of precision the changes observed from time to time. Let me illustrate an example by means of the model. The cystoscope has been passed, the air-bubble seen, the hair line on the prism is made to correspond to the centre of the air-bubble, the pointer is at 0, the stem of the cystoscope is now rotated to the patient's right (the observer's left) and a search is made. You see now a small white slough, the centre of which corresponds to the hair line on the disc. On looking at the register we find, as shown by the pointer, that the cystoscope has been rotated 110° to the right of the meridian, and on measuring from edge to edge of the ulcer the lesion is found to extend between 105° and 115° to the right of the middle line in front, or 65° to 75° to the right of the middle line behind. We are therefore able clearly to define the longitude of a lesion and approximately measure the degrees of the sphere of the bladder occupied by it. But to define the latitude is more difficult, and although I have tried several methods I have not yet been able to hit upon a reliable one. Before showing you some morbid changes seen with the cystoscope in renal disease I shall endeavour to illustrate one or two of the more easily recognised lesions of the vesical mucous membrane.

Case 1 (Plate I, fig. 1).—Hyperæmia of the bladder in a case of injury to the medulla oblongata. The mucous membrane is moderately injected and thickened, and outside the ridge of the trigon it is thrown into deep folds, the ridge itself is unduly prominent, and immediately above the ureteral orifice the mucous membrane is constricted so as to form a distinct neck, the lips of the orifice are drawn slightly apart and are of a bright red colour. The blood-vessels are more numerous than normal, and are distended unduly. This is a good example of acute hyperæmia, brought about by paralysis

of the vaso-motor centres. The patient lived for three days after the injury to the medulla, and during that period he excreted an excessive quantity of urine of low specific gravity. The kidneys showed evidence of marked hyperæmia, the urine contained albumen, some blood-corpuscles, but no tube cast or organisms, and it could be evacuated without the aid of a catheter. This seemed to indicate that while the vaso-motor nerve supply was impaired, the sensory and motor nerves supplying the bladder were unaffected by the injury to the spinal cord.

Case 2 (Plate I, fig. 2).—Early tuberculosis, with ulcers on the floor of the bladder. The symptoms were very insidious at the begining, consisting of frequent micturition, evacuation on an average every two hours, and pain at the commencement and at the end of the act only. The urine was generally clear in colour, but what was passed first in the morning contained more or less blood, almost no pus, and no organisms could be discovered by the microscope. At this time (May, 1902) the patient appeared to be in perfect health beyond the troubles just mentioned. He weighed over 14 st. and had a good appetite. Gradually the discomfort increased, and by August, 1902, the irritation was so great that he was confined to bed. Blood was occasionally present in the urine but not in large quantities and was not increased by exercise nor relieved by rest. Ten examinations were made for tubercle bacillus up till August 25th, with negative results. At that date several groups of tubercle bacilli were discovered, and subsequent inoculation experiments proved the presence of tuberculous infective matter in the urine. A cystoscopic examination revealed one large and several small ulcers occupying the floor of the bladder. They were situated within the area of the trigon. The largest was very irregular in shape (fig. 2) and was covered by a white slough, while the margins were deeply injected and of a bright red colour. The smaller ulcers were rounded, with minute, caseous areas in their centre. The ureteral orifices were strictly normal in appearance, and there was no evidence of tuberculosis in either kidney. Suprapubic cystostomy was performed, the ulcers curetted, and now (April, 1905) the patient can retain urine for four and a half hours. He suffers no pain or discomfort and the urine is free from tuberculous infective matter, as proved by repeated inoculations of animals. (May, 1906, free from recurrence.)

Case 3 (Plate I, fig. 3).—Recent tuberculous deposit close to the neck of the bladder. The case was that of a young lady, æt. 19. The symptoms did not point to any serious bladder lesion, the only inconvenience complained of being frequent micturition. The urine contained a trace of albumen, tubercle bacilli were found in considerable numbers, it deposited a minute quantity of pus, but no tube-casts were discovered. The kidneys were free from disease, and no evidence of tuberculous disease could be discovered except in the bladder. The mucous membrane of the bladder was moderately injected, and the vessels in its walls were more numerous and larger than normal. Extending along the floor of the bladder from a little below the orifice of the left ureter to the neck of the bladder there was a pale mass, like œdematous granulation tissue, and in it a number of small, white, caseous points were seen; these were tubercles just beginning to break down. There was no distinct ulceration. Two years ago the urethra was dilated, and the whole of the tuberculous deposit was removed with a curette. The bladder was washed out regularly for ten days, after which nitrate of silver solutions, of varying strength, were injected at intervals. The patient made a good recovery, and there has been no recurrence of the disease (August, 1905). (June, 1906, free from recurrence.)

Case 4 (Plate I, fig. 4).—Advanced ulceration of the bladder, due to mixed infection by tubercle and *B. coli*. The case was one of old-standing tuberculous disease of the left kidney, with prolonged and profuse pyuria and persistent hæmaturia, severe pain, frequent micturition, and constant elevation of temperature. A cystoscopic examination showed marked hyperæmia of the mucous membrane and distinct prominence and thickening of the ridges of the trigon, pigmentation, and advanced tuberculous ulceration of the bladder. The vas deferens and the ureters were also involved. On account of great irritation even with the assistance of an anæsthetic a cystoscopic examination was obtained with difficulty. The ulcers at the base of the bladder varied greatly in appearance. Most of them were circular in form, surrounded by rings of deeply injected mucous membrane. Some were covered with blood-clot, others were occupied by bright yellow sloughs, while one, the largest of the group, was of a bright green colour and had an irregular yellow ring close to its margin. The whole of the mucous membrane was thickened and

more or less eroded. The arteries were much distended and there were several submucous hæmorrhages. On the anterior wall of the bladder there was a rounded mass, not unlike a small very ripe cherry, and on its most prominent aspect an irregular-shaped ulcer covered by a green slough similar to the one just described.

Case 5 (Plate I, fig. 5).—The mucous membrane is pale in colour and two tuberculous caseous nodules are seen, the smaller one pear-shaped, the larger long, oval. These, the only tuberculous lesions in the bladder, were curetted (June, 1903) with a successful result. Tubercle bacilli got by inoculation and microscopic examination.

Case 6 (Plate I, fig. 6).—Rounded phosphatic stone lying close to the orifice of the left ureter. The mucous membrane of the bladder is thrown into very distinct folds, immediately outside the ridge of the trigon. There is marked hyperæmia and a considerable thickening of the mucous membrane. The ureter opening shows evidence of considerable irritation and the muscular wall is markedly hypertrophied. The stone is very distinct and requires no description.

Case 7 (Plate II, fig. 7).—Encysted stone in which without the assistance of the cystoscope the calculus would probably have escaped observation. The mucous membrane of the bladder is practically normal. The colour, except immediately around the opening of the saccule, is pale, but the lips of the opening are deeply congested, rounded, thickened, and in contrast to the bright red lips of the opening a pale white object is seen. In such cases the difficulty is to determine whether such a white object is a stone or a tubercular ulcer covered with a slough, but by passing the finger into the rectum or the vagina, while at the same time observing through the cystoscope, if the object is a stone the bladder wall is pushed forward to a degree represented by the size of the stone and not by that of the point of the finger.

Case 8 (Plate II, fig. 8).—Papilloma of the bladder. The patient was a man of advanced years, but was free from any prostatic enlargement or inflammatory disease of the bladder. To within six week of my seeing him he enjoyed good health, with the exception of occasional attacks of painless hæmaturia. In the middle of June, 1904, he first complained of difficulty

PLATE II.

Illustrating Dr. David Newman's paper on the Cystoscope in Diagnoses of Diseases of the Bladder and Kidneys.

Fig. 7.

Fig. 8.

Fig. 9.

Fig. 10.

Fig. 11.

Fig. 12.

Bale & Danielsson, Ltd. lith.

NOT TO BE

in micturition and pain. This was referred to the urethra and was limited to the beginning of the act. When the stream had properly begun the pain diminished but again became severe on completion of micturition. At this time he noticed that the urine contained a larger quantity of blood, which steadily increased in amount till I saw him, at the end of August. At that time he was passing not only blood but small clots and he told me that he had been passing urine every hour and a half during the day and five or six times during the night.

On examination of the bladder under chloroform a papilloma was seen almost immediately above the neck of the bladder. The growth was pale in colour, looked soft, was translucent and floated freely in the solution. No vessels were seen ramifying upon its surface, but the mucous membrane behind it was deeply congested. The introduction of the cystoscope did not cause any bleeding, but to the left of the growth a mass of partly decolorised blood-clot was seen firmly adherent to the bladder wall. The rest of the bladder did not present any changes worthy of note. The papilloma was removed and the patient made a good recovery.

Case 9 (Plate II, fig. 9).—Sarcoma of bladder. This tumour of the bladder is very rare. The case was one of a man æt. 26, who had been operated upon several times for "recurrent fibroids," one on the right knee, a second on the hip, and a third on the right lumbar region. When I saw him for the first time there were seven such tumours below the level of the waist, and one over the left shoulder in front. He complained of frequent and painful micturition, and had occasional attacks of hæmaturia. Cystoscopic examination revealed a large rounded tumour on the anterior wall of the bladder. In colour the surface was mottled blush-red, and there was an irregular, lozenge-shaped, pale blue patch almost in the centre; over the surface there was a large number of small capillaries. The mucous membrane was deeply injected and the vessels dilated.

Case 10 (Plate II, fig. 10).—Pedunculated fibroma on anterior wall of bladder, removed by suprapubic cystostomy. The mucous membrane was deeply injected. The urine was normal, except on three occasions, when it contained blood; the last hæmaturia was considerable, and led to a cystoscopic examination, when the tumour was discoverd.

Having shown you these lesions in the bladder, may I now ask your attention to some of the appearances presented by the orifices of the ureters in impacted ureteral calculus.

Case 11 (Plate II, fig. 11).—Stone impacted at the orifice of the left ureter. The mucous membrane of the bladder is unusually dark in colour and the lower part of the ureter is somewhat club-shaped and in the dilated orifice a stone about the size of a horse-bean is seen impacted. The symptoms of the case were more those of vesical calculus than of ureteral obstruction, and this circumstance is to some extent explained by the irregular form of the stone. Had the calculus been rounded and smooth, probably it would have led to more complete obstruction than it did, the irregularity in the form of its walls permitting the passage of urine. It was with the expectation of finding a stone in the bladder that I made the cystoscopic examination, but at once saw that the calculus was firmly impacted in the ureter and it could be detected by a rectal examination. Suprapubic operation was performed and the calculus extracted from the ureter.

Case 12 (Plate II, fig. 12, Plate III, fig. 13).—In this case the calculus had been impacted in the ureter for many months without giving rise to any serious symptoms, the patient being able to follow his usual occupation except for short periods when the pain was most severe. The attacks occurred at irregular intervals during the last three years. On cystoscopic examination round the orifice of the ureter the mucous membrane was darker in colour than elsewhere, the lips were very sharply defined and the orifice between the lips was of a bright scarlet colour but was regular and clearly defined (fig. 12). The mucous membrane of the bladder was practically healthy, but on account of some enlargement of the middle lobe of the prostate the examination was difficult. An X-ray photograph taken at this time showed a shadow at a point corresponding to the union of the lower and middle third of the ureter. On September 10 the patient passed an irregular-shaped calculus about the size of a horse-bean. The same day another X-ray photograph was taken, when the shadow shown in the first photograph was seen to have disappeared. On the 11th the mucous membrane of the bladder was found to be practically healthy. The orifice of the right ureter was normal, that of the left considerably dilated, of a long oval shape, with the margins slightly thickened and irregular.

PLATE III.

Illustrating Dr. David Newman's paper on the Cystoscope in Diagnoses of Diseases of the Bladder and Kidneys.

Fig. 13.



Fig. 14.

Fig. 15.

Fig. 16.

Fig. 17.

Fig. 18.

Bale & Danielsson, Ltd. Lith.

Main

Close to the middle of the upper lip there was a submucous hæmorrhage and a similar spot was seen on the margin of the lower lip (fig. 13). No blood was seen escaping from the ureter. Considering the size of the stone and that the examination was made almost immediately after the calculus was passed, one is rather surprised that there was not more laceration of the lips of the orifice.

Case 13 (Plate III, fig. 14).—History of repeated attacks of renal colic without suppression of urine, but followed by hæmaturia; marked irritation of the bladder, frequent but not painful micturition, and latterly almost constant presence of blood; no renal symptoms; swelling in bladder diagnosed as a tumour, but at operation discovered to be a small calculus included in mucous membrane of bladder. J. H., æt. 35, a marine engineer, first suffered from renal colic on a homeward voyage from India in December, 1893. The first attack lasted for about twenty-four hours only. Complete relief from pain followed, and lasted for seven weeks. Travelling from London to Leeds brought on a second seizure, which lasted for five hours, but although shorter in duration the suffering was more severe in this than in the first attack, and when the pain passed off the patient noticed that the urine contained blood. During 1894 the patient suffered from seven attacks, three of which were followed by hæmaturia. At no time were there any symptoms suggestive of suppression of urine or of hydronephrosis. Towards the end of 1894 the patient complained greatly of frequent micturition; during the act he suffered little or no pain, but on many occasions blood appeared in the urine in moderate quantities. Only twice could the hæmaturia be described as profuse. There were no symptoms pointing to any renal lesion, nor could swelling or tenderness be made out in either lumbar region. No information was gained by rectal examination. No tube-casts and no albumen were present in the urine except those derived from the blood. A cystoscopic examination showed the presence of a rounded swelling immediately over the orifice of the right ureter, about the size of a small cherry, very vascular on the surface, but smooth and free from ulceration. The swelling was diagnosed as a fibroma of the bladder pressing upon the orifice of the ureter and so causing an obstruction to the escape of urine. Suprapubic cystotomy was performed, and the swelling was seized with ring vulsellum forceps. Immediately pressure was made the swelling cracked, and a little traction

brought away a calculus and a thin but complete covering of mucous membrane as shown in fig. 14.

Case 14 (Plate III, fig. 15).—Descending ureteritis in a case of pyonephrosis with calculus impacted in the left ureter three inches above the bladder. The case was one in which the patient suffered from renal symptoms for nearly ten years and when first seen by me there was a large accumulation of pus in the left kidney. The pus generally escaped freely; at other times it appeared in the urine as flakes or threads, and microscopic examination of the deposit demonstrated the presence of large spheroidal granular cells, degenerated epithelium, and a few blood-corpuscles. For many years there was no very marked vesical disturbance, micturition was not unduly frequent, and the urine was acid, and on standing usually the pus was precipitated rapidly and separated clearly from the supernatant fluid. For some time prior to the time the patient consulted me almost no pus had appeared in the urine, but the pain in the left renal region had steadily increased. Cystoscopic examination showed marked hyperæmia of the mucous membrane of the bladder and considerable dilatation of the vessels in the neighbourhood of the left ureter. At the first examination no urine or pus could be seen escaping from the ureter, but at a second examination masses of a purulent discharge were exuded from the ureter occasionally and assumed the form and appearance of cheese maggots. These curled up and fell to the floor of the bladder, where they lay and could be seen easily by the cystoscope. In evacuation of urine, however, they were broken up and mixed with the stream. The lips of the orifice were considerably thickened, and immediately above the outer angle there was a distinct depression and marked pigmentation of the mucous membrane. A little above this point a large vessel was seen on the surface, and at a point where it forked into two branches there was an elevation, but not very pronounced. Nephrotomy was performed and a large quantity of thick, almost putty-like, pus was evacuated.

Case 15 (Plate III, fig. 16).—Recent ascending ureteritis. This is a case of acute septic infection of the bladder consequent upon the incautious use of catheters after an operation for ruptured perineum.

The patient suffered from retention of urine and a district nurse was entrusted by the doctor to pass a catheter when

required. Ten days after the patient (a woman æt. 25) was admitted into the Royal Infirmary. The mucous membrane of the bladder was soft and swollen, almost œdematous-looking, and presented a peculiar glistening, waxy appearance. The ridge of the trigon was rounded and smooth and the orifice of the ureter appeared like a red spot in the centre of a pale pinkish circular area surrounded by a dark ring of deeply pigmented mucous membrane. The margins of the orifice were slightly ulcerated. The flow of urine from the kidney could not be perceived as distinct shoots, and probably escaped in a continuous stream.

Case 16 (Plate III, fig. 17).—Periureteritis from a case of chronic pyonephrosis. The case was one of old-standing suppurative disease of the left kidney, culminating in complete obstruction to the left ureter. Before I saw the patient nephrotomy had been performed, but the wound was not draining well. I enlarged the opening and in doing so found the kidney to be about the size of a cocoanut, riddled with cavities and firmly adherent to the adjacent parts. On draining the kidney by a special method for about eight months, for the first four months almost no urine escaped from the ureter, but after that time occasional floods of purulent urine found its way into the bladder. With the first examination with the cystoscope the ureteral orifice was contracted to a pin-head opening, the vesical mucous membrane was deeply injected, swollen, and thrown into deep folds. The ridges of the trigon were very distinctly marked and immediately below the orifice of the left ureter the mucous membrane was deeply pigmented. No shoots of urine were seen to escape. After the kidney had been drained for six months another examination was made, when the inflammation of the bladder was found to have subsided and the orifice of the ureter was considerably wider than formerly. About once in three minutes a shoot of purulent urine was seen to escape. The kidney was excised and the ureter wall was found to be greatly thickened and the lumen contracted. The walls were infiltrated with firm connective tissue. The mucous membrane was eroded and the ureter was firmly adherent to the surrounding parts, while it was with great difficulty that the kidney could be separated from the diaphragm and the posterior abdominal wall.

Case 17 (Plate III, fig. 18).—Case of recent acute pyo-

nephrosis, with temporary obstruction due to calculus. The mucous membrane of the bladder was dark in colour and the vessels unduly prominent. While at rest the orifice of the ureter appeared like a saucer-shaped depression in the mucous membrane of the bladder, the hollow of the saucer being of a bright red colour, while the lip was of a pale pink, so as to form almost a complete ring, the ring being deficient only at its lowermost part. Immediately before a shoot occurred the orifice of the ureter assumed a pear-shaped form (fig. 18), the upper margin of the opening corresponding to the large end of the pear. You will see in the projector's screen the movement taking place and a shoot of urine escaping.

I will now show you shoots of blood and pus escaping from the ureter under different conditions.

In health the urine collects slowly above the closed sphincters at the orifices of the ureters, and at intervals is thrown by squirts with considerable force into the bladder. The length of the intermission depends upon the activity of the kidney. Under favourable circumstances about ten to fifteen drops are ejected, alternately, from each ureter every thirty or forty seconds. By carefully watching the line of the ureter, the portion coursing through the wall of the bladder, the part immediately above the sphincter, will be seen gradually to distend. Immediately before the urinary squirt appears the expanded duct, looking in form not unlike a miniature engorged leech, is drawn slowly upwards and outwards. It gives a sudden wriggle, its muscular fibres contract, the sphincter is forced open, and the contents are ejected. The urine, as it is thrown into the bladder, forms a distinct jet which shoots downwards and inwards. The spurt occupies about two seconds. The form of the spout can be seen most easily in cases of renal hæmaturia. The aspect of the orifices of the ureters individually and in relation to each other is important to observe. It may be stated as a general observation that when the appearance of the orifice of one ureter is altered while that of the other is normal the renal lesion is on the side of the morbid ureter. And again, if the number of the urinary shoots be counted within a given time, as they occur from each side, and a marked difference is observed, the side on which most shoots are seen is either the site of considerable local irritation or is the most active organ functionally. When due to morbid irritation the shoots not only succeed one another rapidly, but they are of short

duration, and the urine which escapes is small in quantity, whereas in increased functional activity the shoots, in addition to being frequent, are prolonged, and the amount of the urine is large. Instead of coming in regular and distinct jets every twenty or thirty seconds the force of the shoots may be diminished. The manner in which the urine enters the bladder may be so slow as to be hardly perceptible. In stricture of the ureter, or when its lumen is obstructed by a stone, the urine may dribble into the bladder, just as it dribbles out of it in enlarged prostate or in stricture of the urethra.

The arrangement which I have here is very convenient for demonstrating the shoots. Blood is most readily seen and the shoots may be of all sizes, as you see, or it may trickle into the bladder almost continuously. Blood-clots may also escape and after blocking the ureter for some time may be expelled by a shoot of deeply blood-stained urine as you now see. The pus is not so easily perceived when in small quantity, but when copious it imparts a very distinct milky appearance to the urine.

I may summarise the subject of cystoscopic diagnosis of renal disease in the following conclusions: (1) When one ureteral orifice is altered, while the other is normal, the renal lesion is on the side of the morbid ureter. (2) When the urinary shoots are more frequent on one side than on the other—(*a*) greater functional activity is indicated by the shoots being uniform in size and regular in rhythm; (*b*) undue irritation of the kidneys is to be inferred when the shoots, while more frequent than normal, are irregular in rhythm, unequal, and small in size; (*c*) stricture, stone, or chronic ureteritis should be suspected when the shoots are distorted in form or irregular in amount. (3) When the urine does not escape in distinct jets—(*a*) dilatation of the ureter without paralysis of the sphincter is indicated when the urine dribbles into the bladder at intervals; (*b*) destruction of the sphincter action is shown by the urine flowing into the bladder almost continually. (4) The character of the morbid fluids escaping from the ureter, or of clots, etc., occupying the opening, denotes the morbid changes taking place in the corresponding kidney. (5) The deformity of the orifice also indicates the character of the renal disease—(*a*) pin-head contraction (chronic inflammation or impacted calculus); (*b*) elongated and distorted (distension of renal pelvis or infected nephritis); (*c*) swollen or pouting (prolonged

but not acute inflammation or renal parenchyma); (*d*) dilated (advanced tuberculous or calculous pyonephrosis); (*e*) **U**-shaped (significance doubtful—usually denotes prolonged irritation of renal pelvis).

II.—*A Case of Tuberculosis in a Diverticulum of the Bladder found in an Inguinal Hernia.* By Edred M. Corner, M.B., B.C., F.R.C.S., and Cecil W. Rowntree, M.B., B.S., F.R.C.S. *Read October* 13, 1905.

WE have brought this case to the notice of the Society on account of the rarity of the conditions it presented.

A boy, æt. 18 months, was admitted to the Hospital for Sick Children in July, 1904. According to the mother's account a swelling had been present in the right side of the scrotum since birth. It varied in size from time to time, and when the child was in bed almost entirely disappeared. On the whole, however, there had been a decided increase in size of the swelling. There was no history of any pain, tenderness, urinary or other symptoms.

On admission the child presented a moderate-sized swelling on the right side of the scrotum, extending from the external abdominal ring to a point just above the testicle. The examination provoked neither pain nor the desire for micturition. The condition was regarded as an ordinary irreducible hernia in a sac which was separate from the tunica vaginalis of the testis.

In the short time previous to the operation during which the patient was under observation no noteworthy change occurred in the condition. At the operation the inguinal canal was opened throughout its length, when it was apparent that the conditions were unusual. No sac was obvious, and there appeared to be an unusual amount of rather dense fibro-fatty tissue. Further dissection revealed a layer of muscle, which on incision was found to enclose a thin-walled sac, from which there flowed several drachms of pale, clear urine. This was under no pressure, flowing in a gentle stream increased with each expiration.

Examination with the finger and sound showed beyond doubt that it was a process of the bladder which had been opened. The inguinal region of the other side was examined by means of a finger in the bladder, but with a negative result.

An attempt was now made to separate the process from the structures of the cord, which was found to be spread over

its outer and anterior surfaces. This was quite easy above, but at the lower end the cord was found to be somewhat firmly adherent, more particularly so to the upper end of the tunica vaginalis; and at this part the process of the bladder, which for the greater part of its extent was of uniform character, showed a remarkable bulky enlargement, due to considerable thickening of its wall, and owing to the presence of a dimple in the centre, it presented the most remarkable resemblance, both to sight and touch, to the os uteri.

The diverticulum when isolated was found to be about two inches long, and was excised at the level of the internal abdominal ring, the bladder being sewn up in two layers with continuous sutures. The operation was completed on the lines of Bassini's method, the wound being closed without drainage.

The part removed showed a mucous lining which was like the bladder mucous membrane, except that it was smoother. At the part covering the thickened lower end of the sac there was some superficial ulceration. The whole mass was put into hardening solution, and kept for further examination.

During the course of the operation a most careful search failed to find any trace of a co-existing peritoneal hernia sac, and we must, therefore, regard this case as one of hernia of the bladder of the purely extra-peritoneal type.

Hernia of the bladder of all types is a rare occurrence in children. Gibson * of New York, in 1897, when analysing 103 cases of hernia of the bladder of all varieties, found only three in children; while Moynihan, † lecturing in 1900, was only able to add one more case. Since that date two cases have been published, one by Mr. Curtis ‡ and one by Dr. Taylor. §

Mr. Curtis refers to other unpublished instances, all of which died of septic peritonitis, a calamity which no doubt accounts for the small number of published cases.

Where it has been possible to refer to the original papers, in most of the cases the hernia was upon the right side, which was the case in our patient. The age of the reported cases varied between two and thirteen; our case is therefore the youngest so far recorded.

* Gibson, *Trans. Med. Soc.*, New York, 1897.
† Moynihan, *Brit. Med. Journ.*, 1900.
‡ Curtis, *Brit. Med. Journ.*, 1903, ii.
§ Taylor, *Lancet*, 1903, i.

None of them were diagnosed correctly before operation, and there appears to have been a complete absence of all classical symptoms, such as the *micture à deux temps*, which are probably only found in adults, with large direct herniæ containing a large proportion of the bladder.

The treatment obviously depends upon the stage at which the condition is disclosed; if the bladder is cut into, then the incision must be carefully sutured and the organ returned to the abdomen, any associated peritoneal protrusion being dealt with *secundum artem*. If recognised earlier, then the peritoneum can be gently separated, and the bladder pushed back out of the way. In our own case the line of treatment was justified by the length and shape of the protrusion, and by the fact that it had already been incised. In children the question of drainage need hardly detain us, as the urine is perfectly sterile, and one can rely upon a water-tight suturing.

To leave a catheter in the bladder is usually condemned as unnecessary and harmful, while periodic catheterisation is not usually indicated.

As to the causes of hernia of the bladder we have no certain knowledge; it is certainly very easy in the course of any ordinary radical cure of hernia by traction upon the peritoneum to pull out a portion of the bladder, which may be recognised at the inner pillar of the ring by the reddish-brown colour of its muscles, often concealed, however, by a layer of extra-peritoneal fat. And again, the presence of bladder in recurrent herniæ is not uncommon.* This renders it probable that the descent of the bladder is secondary to the descent of the peritoneum, which perhaps in these cases has a more intimate connection with the bladder than is usual. In such a way many of the cases may be accounted for, but how are we to account for the condition of affairs in our case? Here there was no peritoneum to lead the way. As a possible explanation one thinks of the vagaries of the gubernaculum testes, and it is possible that an abnormal attachment to the bladder may have led to the condition.

Any classification of these cases, in our present state of knowledge, is purely arbitrary, and is only possible on an anatomical basis, depending upon the presence or absence of peritoneum.

We may, therefore, describe a purely extra-peritoneal type in which there is a diverticulum of the bladder lying in

* Künnen, "Case of a Boy of five who had had a previous Radical Cure," *Revue Médicale de la Suisse Romande*, 1892.

the inguinal canal, and unassociated with a peritoneal sac. Of this class our case seems the only representative.

The other class must include all cases of oblique inguinal hernia in which the protrusion of a peritoneal pouch is associated with the descent of a part of the bladder. The cases in the group will vary in degree. In some the bladder element will be very small, being represented by a slight bulging at the inner pillar of ring; in the other the bladder will predominate, the peritoneum being present as an insignificant pouch, which, as has been strongly urged by Moynihan,* is very likely to be overlooked.

Direct herniæ are, of course, unknown in children, and we have failed to find any record of the presence of the bladder in a femoral hernia in a child, although not unknown, of course, in adults. The infrequency of hernia of the bladder in childhood is a matter for some surprise when one remembers the relatively high position in the abdomen occupied by the viscus in children. But, on the other hand, the majority of cases of hernia of the bladder in adults are of the direct variety, which arise from a point much nearer the middle line than do the oblique. And again, many of the cases are recurrent herniæ after radical cures in which the bladder has probably been already pulled into dangerous proximity to the interior abdominal ring.

The further history of our case is of great interest. The part removed at the operation was sent to the pathologist, who reported that the area of ulceration and thickening at the lower end of the sac showed a typical round-cell infiltration with giant-cell formation, indicative of the presence of tuberculosis. This came as a great surprise, in view of the absence of symptoms and the healthy appearance of the child; and careful examination failing to show any further signs of tuberculous mischief, he was discharged in about a fortnight with the wound soundly healed. About two months after operation, however, he was brought back to the hospital with the history that his abdomen had been getting larger during the last few weeks. Examination revealed a large amount of free fluid in the belly, but no tumour and no enlargement of the glands. Laparotomy was performed a few days afterwards, and after the evacuation of a large quantity of almost clear yellowish fluid, it was found that the entire peritoneum, parietal and visceral, was red, injected, and

* *Loc. cit.*

covered with tubercles. The site of the former operation was examined, and it was found that the peritoneum over the internal abdominal ring was quite smooth. The peritoneum was sponged dry, and the wound closed. The boy made an excellent recovery; there was no re-accumulation of fluid, and he left the hospital convalescent. He was seen by one of us a few weeks ago, and is now, fourteen months after the second operation, in good health, without any sign of recurrence of either his hernia or his tuberculous peritonitis.

This case is interesting, therefore, not only an account of the coincidence of the presence of tuberculosis in a unique example of hernia of the bladder, but because of the remarkable way in which the boy was cured of what was regarded as rapid tuberculous peritonitis by the simple procedure of laparotomy with evacuation of the fluid.

III.—*The After-History and Post-Mortem Record of a case of Cardiac Syphiloma with Bradycardia and Obstruction of the Inferior Vena Cava.* By CHARLES W. CHAPMAN, M.D. *Read November* 10, 1905.

IN the Session 1897-98 of this Society I showed the patient, a man æt 48, whose case is the subject of this communication, under the heading "A Case of Bradycardia, with Obstruction of the Inferior Vena Cava." The action of the heart was slow and there was a systolic mitral murmur. There were greatly dilated and varicose veins over the middle and right side of the abdomen and a similar condition was seen on the outer side of the right leg. This condition as far as the abdomen was concerned had existed for five years at least, while the veins of the leg had only recently become dilated. There was a history of an itching sore on the penis 20 years previously. There had never been any secondary symptoms and as the sore had given little or no inconvenience to the patient, only a short local treatment had been adopted.

During the following Session, 1899-1900, I read a paper on the same case, entitled "A Case of Obstruction of the Inferior Vena Cava, probably Syphilitic." In this paper I went fully into the history and detailed the conditions found on examination. A provisional diagnosis was made of obstruction of the inferior vena cava from pressure of a gumma, or to thrombosis from phlebitis. Arguments in support of the syphilitic origin of the disease were given, with an account of the treatment adopted, the paper concluding with references to recorded cases of syphilitic affections of the circulatory system and to literature bearing on the subject. The account of the case when exhibited and the report of the paper are to be found in the Clinical Society's *Transactions*, vols. xxxii and xxxiii.

Up to May 6 of this year the man had been a more or less constant attendant at the Out-Patient Room, which means that I had him under my observation for eight years, and he had had dilated abdominal veins for nearly fourteen years. There was nothing special to note beyond that he was for the greater part of the time under iodide, and that the

pulse rate ranged between 33 and 44, and that the syncopal attacks subsided. He was never well if the treatment was suspended for more than two or three weeks. He was able to continue his work as a barber up to his last visit.

Early in June last I was informed that the patient had been admitted into the London Hospital for suppurating appendicitis, that he had been operated upon and shortly afterwards succumbed to general peritonitis. I at once communicated with the hospital authorities, and it is owing to their courtesy, coupled with the kindness of Mr. Miller, that I am able to give an account of the *post mortem*.

Post mortem.—The abdomen was distended and covered with varicose veins. On opening it there was evidence of an appendix abscess and general peritonitis.

In the pleuræ there were a few thin adhesions about the right apex and both cavities were dry. At the apex of the right lung there was a patch of obsolete calcareous tubercle. The root of this lung, with the neighbouring large vessels, glands, and mediastinal tissues were firmly matted into a mass of fibro-calcareous material. In the base of the right lung the rings of the larger bronchi were calcified. The pericardium contained an excess of clear fluid. The two surfaces were free. There was great increase of epicardial fat over the right auricle and at the base of the heart. Over the left ventricle and auricle the visceral pericardium was thick and opaque in places. The heart was pyriform in shape, the right side being about the same size as the left. It weighed 15 oz. The heart-muscle was brown and tough, with visible strands of fibrous tissue running through it. The left ventricle was dilated but not hypertrophied; the right ventricle and auricle were dilated and contained a small amount of black clot. The cavity of the left auricle was greatly diminished and constricted in its middle to a ring which just admitted the tip of an index finger. The cause of this narrowing was a dense calcareous mass situated beneath the endocardium. This condition of calcification affected the whole circumference of the left auricle, the interauricular septum, the aortic sinus, and first inch of the aorta being in all places deep. The interventricular septum was thick and muscular.

The valves.—The mitral curtains were thin and pliant, but just above the mitral ring the left auricle was narrowed by the ring already described. The aortic cusps were thin and pliant. The pulmonary and tricuspid valves were natural.

The coronary arteries were narrowed at their orifices, but further down were unchanged. The aorta contained many patches of atheroma.

Summary of the condition of the heart.—The calcareous mass produced a condition amounting to mitral stenosis. It also narrowed the left auricle, partially occluded the coronary vessels, and affected the interauricular septum. There was great fibrosis of the myocardium.

The kidneys beyond a few cortical cysts presented no gross changes. The liver weighed 56 oz., was firm and bile-stained. *The left testicle* presented a typical diffuse fibrous gummatous condition.

Microspical examination.—Sections were cut of the heart-muscle and the left testicle. The condition of the latter confirmed the macroscopic appearances of gumma. The heart-muscle showed an advanced general, diffuse, fibrosis. The walls of the main divisions of the coronary artery were apparently natural, but there was considerable increase in the adventitia of the smaller arterioles. There was no obliterative proliferation of the intima.

There are two points to which I would like to call attention. (1) That the initial lesion was so insignificant to the patient that but little treatment was adopted. (2) It is probable the disease was still in progress when he came under my observation in 1897, when a lump the size of half a walnut at the back of the neck was noted and which completely disappeared under the mercurial treatment to which he was subjected. The prolongation of the patient's life may fairly be attributed to the recognition of the true nature of the case and to the vigorous and prolonged treatment.

It is an interesting question whether the bradycardia which was present at least for the last eight years was due to myocardial invasion, with gummatous deposit and subsequent fibrosis, or to an early implication of the orifice of the coronary arteries. The affection of one testicle only is in accordance with the observations of Wilks and Moxon, who also considered the unilateral presence of gumma in these organs a ready indication of syphilitic taint.

Attention may here be called to a valuable paper by Sir Dyce Duckworth on a case of cardiac syphiloma in this Society's *Reports*, vol. xxix, which should be read in connection with the case under consideration. I would particularly refer to some of the author's closing remarks, which I cordially endorse, for they voice the chief reason, and apology if need

be, for bringing this case to your notice for a third time. They are: "The great object is to recognise the nature of the disease as soon as possible, and to treat the patient by large doses of iodide of potassium. On these lines the best results may be anticipated."

IV.—*Case of Suppurative Pylephlebitis associated with Suppurating Mesenteric Gland.* By Francis H. Hawkins, M.D. *Read November* 10, 1905.

A SCHOOLBOY æt. 12 was admitted into the Royal Berkshire Hospital under my care on April 16, 1904, complaining of vomiting, diarrhœa, and pain in the region of the umbilicus. No definite history of any previous illness could be obtained, but it was stated that for some time past the boy had been getting thinner. The history of the present attack was that on April 1 when walking along the street he suddenly commenced to vomit; of this no particular notice was taken. On April 4 he went to watch a football match, and while so doing he had a sudden chill, followed by vomiting, and was so ill he had to be taken home. Shortly after getting home diarrhœa set in, and this with the vomiting had continued for twelve days. On admission it was noted that the patient was a thin, fair-haired boy with a somewhat muddy complexion. He was lying on the left side. The alæ nasi moved freely in respiration. There was no jaundice. The tongue was moist and covered with a thin white fur. The abdomen was very slightly distended and moved freely in respiration. On palpation there was no rigidity, but pain was felt about one inch to the right and a little above the umbilicus, and there was some tenderness over the left half of the epigastric region. The percussion note was normal in all regions. The upper border of the liver was at the lower border of the fifth rib in the right mammary line and extended one finger's breadth below the costal margin; dulness was not marked over the epigastric region; the spleen was not felt.

Respirations were 30 per minute. Both sides of the thorax moved freely in respiration. The percussion note was normal anteriorly and posteriorly excepting over the left base, where the note was somewhat muffled, and over this area the expiratory murmur was somewhat prolonged. No adventitious sound could be heard. The pulse was 130 per minute. The heart was normal, the urine sp. gr. 1005, neutral, no albumen. The temperature was 105°.

Subsequent history.—There was no vomiting or diarrhœa after admission to the hospital. The bowels were constipated and relieved only by enemata. Shortly after admission the

patient had a rigor, also one on the 18th, 20th, and 21st, and two rigors on the 22nd, 23rd, and 24th. He also had profuse perspirations. On the 19th albumen appeared in the urine.

On April 20 it was noted that the liver was slightly more enlarged, and on the 22nd a distinct swelling was seen in the epigastric region as if projecting from beneath the left costal margin; its base was the costal margin from the seventh to the ninth costal cartilages, its convexity downward and to the right. Below this swelling the left lobe of the liver could be felt, extending for about a quarter of an inch into the left half of the umbilical region. The swelling was soft and exquisitely painful. The lower part was firm, and the border of the left lobe could be distinctly mapped out.

The patient died on April 25, nine days after admission to the hospital and twenty-five days after the first attack of vomiting.

Necropsy.—There was no jaundice. Body somewhat emaciated. On opening the abdomen the left lobe of the liver reached in the mid-sternal line nearly to the umbilicus. The region corresponding to the swelling noted above consisted of one fairly large central yellowish swelling, with several smaller ones around. The right lobe extended for some distance below the costal margin. The liver weighed 4½ lb., transverse measurement 10 inches; the left lobe from above down 6½ inches, the right 7½. The surface of the left lobe was greenish-black in colour, and there were numerous indentations. The right lobe also had several small indentations. On following up the portal vein multiple abscesses were seen, in the left lobe two about the size of a large walnut and a number of small ones. The rest of the liver substance was greenish-black in colour. The right lobe contained two small deep-seated abscesses.

The mesenteric glands were enlarged, several were suppurating, and one (in the area of pain, *i. e.* one inch to the right and a little above the umbilicus) was of a brownish-black colour, and on drawing the intestine aside it burst, and discharged extremely offensive pus.

The spleen was enlarged upwards. This was the cause of the muffled note at the base of the left lung. It weighed 13 oz., and measured 7½ inches in length and 3½ in width. It was somewhat discoloured, but there was no abscess. There was no peritonitis. The other organs showed no evidence of disease.

Report from the Clinical Research Association.—"Direct examination of this pus reveals the presence of a considerable mixture of organisms, but neither tubercle bacilli nor pyogenic cocci can be found, and the only organism detected in cultures is the *Bacillus coli communis.*

"There is nothing in the structure of this mesenteric gland to throw light on the suppuration in the liver. Its tissues are much softened, and the lymphatic channels are dilated from recent absorption."

Remarks.—Cases of suppurative pylephlebitis are by no means common; they are invariably secondary to some other suppurative process in the organs in which the roots of the portal vein originate, and in this case I am inclined to think that the necrotic mesenteric gland was the primary cause, and hence it appears that this case is worthy of record, as such a cause is least commonly associated with suppurative pylephlebitis.

V.—*A Successful Case of Splenectomy for Rupture of the Spleen, with Remarks on the Diagnosis and Treatment of this Accident.* By GRAHAM SIMPSON, F.R.C.S. *Read November* 10, 1905.

MR. President and Gentlemen,—Two reasons have influenced me in reading this paper before you to-night: the first, that successful operations for traumatic rupture of the spleen are still uncommon; the second, the hope that some remarks that I shall make on the diagnosis and treatment of this accident may form the starting-point of a discussion which will, I am sure, be of value to all of us.

I will now give an account of the case:

Henry C., æt. 27, a builder's joiner, was at work on a joist on August 10, 1904, when the joist broke and he fell through a ceiling on to the floor below, a distance of some twenty feet. The patient thinks that he struck his left side against some projection during his fall, but he was not certain about this, though he was not rendered unconscious by the accident.

This happened at 10 a.m., and he was at once brought to the Sheffield Royal Hospital, where he was admitted for a fracture of the left femur; he certainly did not, at the time of admission, complain of abdominal pain.

He was admitted under the nominal care of Mr. R. J. Pye-Smith, during his absence on a holiday, and to his kindness I am indebted for permission to publish the case.

At 2 p.m. (four hours after the accident) I was called to see the patient as he was complaining of severe abdominal pain. I found him looking pale and anxious and obviously in great pain, his face drawn and haggard and his breathing thoracic and jerky. His pulse was 140, his temperature 100° F., and his respirations 50. He complained of unbearable pain in the abdomen, "like stomach-ache but more acute"; he felt sick but had not vomited, and he was sure that he was going to die. He wanted to pass water but was unable to do so; his bowels had not acted since admission. His injured leg was not troubling him.

On examination, the abdomen was rigid, especially in its upper part; it did not move with respiration; the liver dulness was present and there was some dulness in the epigastrium; the abdominal wall was tender on pressure, more so in the upper part. I felt sure that a catastrophe had happened

inside the abdomen and that an exploration should be performed at once.

I was inclined to diagnose rupture of the intestine high up. Some delay was caused by my not being able to find any of the honorary staff, and as I feared any further waiting would be fatal, at 3.45 p.m. (five and three quarter hours after the accident) chloroform was administered and I made a vertical incision just to the left of the umbilicus, with the level of that point as its centre. On opening the abdominal cavity neither gas nor fluid escaped, nor were there any signs of commencing peritonitis, but, on inserting my hand to explore the upper part of the abdomen, directly the omentum was pressed away from the anterior abdominal wall there was an alarming rush of dark red blood. This appeared to come from the left lobe of the liver, which was then examined but with some difficulty, as the blood flowed with great rapidity and continually flooded the field. As no obvious lesion of the liver was found, the spleen was next palpated, and I easily made out a large transverse tear, starting from the hilum. A long pair of artery forceps was applied to the pedicle, which at once controlled the bleeding and made the rest of the operation simple.

The incision was prolonged upwards and the spleen brought round in front of the stomach, so that its anterior and external surface looked backwards and inwards, the pedicle was transfixed and ligatured with stout silk from its posterior aspect, the spleen excised, and the blood swabbed out of the abdominal cavity. The wound was sewn up in layers.

The patient was not so well by this time, though his condition was by no means desperate; it was thought advisable to infuse three pints of saline fluid into a vein on account of his having lost so much blood.

The operation took about three quarters of an hour. On his leaving the table, the patient's pulse was very rapid, but quite distinct.

Next morning, August 11.—The patient had passed a fair night and had slept at intervals, had vomited once after drinking some hot milk, and had complained of some abdominal pain. Saline enemata had been ordered every four hours, but had not been well retained His pulse was 110, of fair tension. Calomel (1 gr. every four hours) was successful in causing his bowels to act. A catheter was passed, as he was suffering from retention of urine.

On August 12 a blood count was made: Reds, 3,376,000; whites, 10,000.

All went well till August 15 (the fifth day after the operation), when he suddenly began to complain of severe epigastric pain.

On examination, I found his pulse 120 and his temperature 101° F.; there was marked pulsation in the epigastrium, no rigidity of the abdominal wall, but great tenderness. I began to fear that my ligature had slipped, but decided to wait, as I thought the pulsation might be only communicated from the right ventricle. In a short time the patient felt better.

After this progress was uneventful, with two exceptions—the wound suppurated (I fear that my aseptic conscience must have slept during the excitement of stopping the bleeding), and the femur, which was put up in a Hodgen's splint, was found to be still ununited at the end of six weeks. However, it was put up again in the same way for another six weeks, when it united firmly with half an inch of shortening.

He was discharged on November 6 with the wound healed, but some separation of the fibres of the left rectus at the site of the scar.

During the three months of his stay in hospital his blood was frequently examined and differential counts were made: it showed the usual changes, viz. a diminution of the red corpuscles, which, however, rose to normal in a month, and a leucocytosis up to 44,000, which fell to normal in three weeks. The unusual amount of leucocytosis I explain by the occurrence of suppuration.

No enlargement of his lymphatic glands was noticed during the first three months, but since then his left axillary and inguinal glands have several times enlarged sufficiently to be easily palpated, and have again subsided.

At no time has he complained of pains in his bones, nor has there been any particular pain on percussing them; nor has he shown that curious group of symptoms described by Mr. Ballance and Mr. Bernard Pitts (to which I shall again refer), though no prophylactic treatment was adopted, such as the exhibition of arsenic, sheep's spleens, etc.

With the exception of the first fortnight after operation, his pulse-rate has always been normal. The only after-consequences that he shows are—first a ventral hernia, and second a loss of nerve, which prevents him from following his former occupation of builder's joiner, an occupation which involves much climbing about roofs.

He has, however, taken up the work of an insurance agent, and tells me that he is doing well.

The last blood-count was done on September 14, 1905, and showed: Red corpuscles, 4,762,000; white corpuscles, 6,500.

Blood-counts.—August 13, 1904 (three days after admission): Red corpuscles, 3,376,000; white corpuscles, 10,000; hæmoglobin, 60 per cent.

Differential count.—Polynuclear leucocytes, 75 per cent.; small leucocytes, 13·3 per cent.; large leucocytes, 10·6 per cent.; eosinophiles, ·5 per cent.; nucleated red corpuscles, ·6 per cent.

August 18, 1904 (eight days after admission).—Red corpuscles, 2,592,000; white corpuscles, 16,000; hæmoglobin, 60 per cent.

Differential count.—Polynuclear leucocytes, 81 per cent.; small leucocytes, 12 per cent.; large leucocytes, 5 per cent.; eosinophiles, 1 per cent.; nucleated red corpuscles, 1 per cent.

August 21, 1904 (eleven days after admission).—Red corpuscles, 3,480,000; white corpuscles, 44,000; hæmoglobin, 60 per cent. No differential count.

August 28, 1904 (eighteen days after admission).—Red corpuscles, 3,360,000; white corpuscles, 16,000; hæmoglobin, 60 per cent.

Differential count.—Polynuclear leucocytes, 73·6 per cent.; small leucocytes, 13·6 per cent.; large leucocytes, 11·2 per cent.; eosinophiles, ·4 per cent.

September 4, 1904 (twenty-five days after admission).—Red corpuscles, 4,200,000; white corpuscles, 8000; hæmoglobin, 75 per cent. No differential count.

September 11, 1904 (one month after admission).—Red corpuscles, 4,920,000; white corpuscles, 8,000; hæmoglobin, 90 per cent.

Differential count.—Polynuclear leucocytes, 65·5 per cent.; small leucocytes, 27·5 per cent.; large leucocytes, 5 per cent.; eosinophiles, 2 per cent.

September 25, 1904 (six weeks after admission).—Red corpuscles, 4,912,000; white corpuscles, 12,000; hæmoglobin, 90 per cent.

Differential count.—Polynuclear leucocytes, 73·5 per cent.; small leucocytes, 23·5 per cent.; large leucocytes, 2·5 per cent.; eosinophiles, ·5 per cent.

October 1, 1904 (seven weeks after admission).—Red corpuscles, 4,288,000; white corpuscles, 12,000; hæmoglobin 80 per cent. No differential count.

October 8, 1904 (eight weeks after admission).—Red corpuscles, 4,800,000; white corpuscles, 12,000; hæmoglobin, 90 per cent. No differential count.

September 14, 1905 (thirteen months after operation).—Red corpuscles, 4,762,000; white corpuscles, 6,500.

Differential counts.—Neutrophiles, 57·66; transitionals 1·21—58·87 per cent.; large mononuclear, 15·32 per cent.; small mononuclear, 21·14 per cent.; eosinophiles, 3·89 per cent.; basophiles, 0·73 per cent.; Mastzellen, erythroblasts 0.

My thanks are due to Dr. R. J. Bethune, who assisted me at the operation, did most of the blood counts, and also gave me some valuable advice.

From the various English sources I have collected 100 cases of rupture of the spleen: most of the cases recorded before 1891, however, are so scantily reported as to be of little value.

In the following remarks I have chiefly relied on 70 cases recorded since 1891.

From the point of view of diagnosis, *sex* and *age* are not of much importance, as in severe accidents generally males are more often injured than females; so in these cases four-fifths of the number were males. The age distribution is most impartial; the oldest patient was sixty-five, and the youngest was in the act of being born. This last was a case of precipitate labour, in which the mother was standing at the time and the child fell to the floor.

Age distribution (arranged in decades):

Years.	No. of cases.
1–10	11
11–20	18
21–30	15
31–40	15
41–50	6
51–60	11
Over 60	2

Three points must be considered in making a diagnosis of ruptured spleen:

(1) *The history of the accident.*—The commonest cause is a *sharp blow* or *kick* on the abdomen or side. Under this heading must be included most of the cases of *falling from a height,* as it will usually be found that the side was struck during the fall. This accounts for 44 per cent. Next in order of frequency is a *crush* or *squeeze,* such as cases of *run-over* and *buffer* accidents. This accounts for 32 per cent.

Twelve per cent. are described as due to a *sudden movement* or *strain*. These are usually grouped as spontaneous ruptures, and are nearly always found to be cases of large, soft, malarial spleens. One, however, was congested from a twisted pedicle.

The remaining 12 per cent. are unclassified.

(2) The second point in the diagnosis is the signs of internal hæmorrhage.

Shock is present in the majority of cases, either at once or within a few hours.

Pallor, thirst, restlessness, and *retention of urine* are usually stated to have been present when they are mentioned in the reports.

(3) The *localising* signs, *abdominal pain and tenderness,* are very constant; they are usually most marked in the region of the spleen, and I have found four cases only where these signs are stated to have been absent. *Rigidity of the abdominal wall,* in some cases limited to the upper half of the left rectus, is a most valuable sign when present; but I was surprised to find that out of nineteen cases where this physical sign was mentioned, in six it was stated to have been entirely absent, and in another case the abdominal wall was described as slightly rigid. This initial rigidity of the abdominal wall is succeeded in from six to twenty-four hours by *distension of the abdomen.* The demonstration of *dulness in the flanks* is the sign which will most surely lead one to a correct diagnosis; if, as described by Mr. Ballance, on changing the position of the patient the dulness of the right loin disappears, but not that of the left, a diagnosis of rupture of the spleen or left kidney can be safely made. I feel sure that if my attention had been drawn to Mr. Ballance's paper before I saw my case I should have been able to diagnose it correctly. *Diminution of the liver dulness* has been noted in a few cases and can be explained by the distension of the abdomen or by a concomitant rupture of the stomach or small intestine. *No external marks of injury* are present in most cases.

From the point of view of treatment I propose to divide the cases into four groups.

(1) The patient dies at once or within a few minutes of the accident. These cases hardly come within the range of surgery, and I can find no cases of successful operation within the first hour.

(2) The opposite extreme; the symptoms are greatly delayed; I have found instances of delay from twenty-four hours to fifteen days; this can be accounted for by the tem-

porary arrest of the bleeding by clotting or, in some cases, by the hæmorrhage being at first subcapsular and later bursting through the capsule.

(3) The majority of cases; here the initial shock of the accident, when present, is recovered from, and after from one to twenty-four hours symptoms of hæmorrhage show themselves.

(4) A very few cases where the symptoms of rupture of the spleen have been present and have gradually passed off without operation.

Now, which of these groups of cases require operative measures? After careful consideration, my answer is *all.*

In the first group the only chance is immediate laparotomy, though I fear there is not much hope of saving the patient.

The cases in the second group—viz. those of delayed bleeding—are in great danger. The clot may become displaced, or the capsule may rupture from distension, and in some of them, at any rate, the secondary bleeding is very severe.

I think it may be laid down as a sound surgical rule that, if after showing the signs of an intra-abdominal hæmorrhage a patient recovers, but on examination the spleen is found enlarged, an exploratory laparotomy is strongly indicated.

I do not think any surgeon will dispute that the cases in the third group should be explored.

The last group, where the patient recovers after showing the signs of a ruptured spleen (but without obvious enlargement of the organ), I propose to include as suitable for operation for the following reason: that in two cases the effused blood has become auto-infected—in one case leading to a subdiaphragmatic abscess and a fatal result, and in the other to signs of sapræmia, which necessitated opening and washing out the abdominal cavity.

One question that I should very much like to hear discussed is, May one operate simply on the strength of the history of the accident? I am sure that two fatal cases of rupture of the intestine that I have seen would have recovered if that had been done. The objections to such a proceeding are sufficiently obvious.

As to the operation, a vertical incision through the rectus muscle is probably the best to start with; one is not always certain about the diagnosis, and, if there are no adhesions and the spleen is not enlarged, everything can be done through this incision. If, on the contrary, there are adhesions between

the spleen and the diaphragm, the operation becomes at once one of the most hazardous in the range of surgery; in that case a transverse incision below the left costal margin will be necessary.

Of the methods employed to stop the bleeding, *ligature of the pedicle* alone has been performed in one case where it was found impossible to excise the spleen.

Suture has not, as a rule, been found satisfactory, though a successful case has recently been published. The splenic substance is so friable that this method is likely to be employed only in tears limited to the capsule.

Gauze-packing and tampons.—These are not always trustworthy, and are likely to cause extensive adhesions which may lead to subsequent obstruction. This method will, I think, be the best for cases where, owing to adhesions between the spleen and the diaphragm, excision of the former is too risky a proceeding.

Excision of the spleen will usually have to be performed, first, because the injury is often so severe (the organ has, in many cases, been found torn into two or more pieces and portions have been washed out of the pelvis), and secondly, because of the frequency with which the vessels of the pedicle are involved in the injury.

Moreover, clamping the pedicle at once controls the hæmorrhage.

The *mortality* of the operations for rupture of the spleen that I have collected is as follows:

Of 70 cases recorded since 1891, 42 were operated on. Of these 27 lived, 15 died—a mortality of 36 per cent. (all those not operated on died).

This mortality is probably much too favourable, as some cases that have been operated on and died may not have found their way into the literature.

The causes of failure after operation are: (1) Peritonitis. (2) Complications, such as rupture of other solid or hollow abdominal viscera, especially the left kidney; injuries of the left pleura, as hæmothorax; other injuries, as fracture of base of skull. (3) Operation performed too late. Out of 28 cases where it is stated how long after the accident the operation took place 3 operations were performed within the first two hours; all 3 died (probably very severe cases); 14 operations took place from three to twenty-four hours after the accident; 11 lived, 3 died; 6 operations were done "the next day";

5 lived, 1 died; 5 operations were done two to eight days after accident, only 1 of which lived.

The sequelæ of the operation of splenectomy present a most interesting problem.

The majority show no abnormal effect except a transient anæmia and leucocytosis which swing back to normal in about a month, and an enlargement of the lymph-glands, most often the left axillary and inguinal; otherwise the patients are healthy.

In two cases the patients, though pregnant at the time of operation, have gone on to term. Another patient was successfully operated on for a resulting ventral hernia. A fourth recovered from an attack of typhoid fever after losing his spleen.

In five recorded cases (viz. those of Messrs. Ballance, Bernard Pitts, Rutherford Morison, Heaton and Burrows) a curious set of symptoms supervened on or after the tenth day; these were progressive emaciation (one case lost three stone), attacks of epigastric pain, pyrexia, thirst, rapid pulse and respiration, headache, drowsiness and irritability of temper.

These cases have cleared up on the exhibition of arsenic and sheep's spleens; in one case the patient relapsed when the treatment was discontinued.

Mr. Ballance has suggested that these symptoms may be due to the fact that it takes some time for the other organs of the body to take over the functions of the spleen, and that it is less likely to occur in children, in whom the tissues are said to be less specialised. The latter part of his theory is not supported by the ages of the five cases which I have just referred to; they were 4, 9, 16, 36, and 45 years.

VI.—*A Case in which the Pleura contained several Pints of Calcareous, Mortar-like Fluid.* By Samuel West, M.D. *Read November* 24, 1905.

EDWARD J—, a printer's labourer, æt. 32, was sent into the hospital with the diagnosis of empyema. He stated that he was well until four weeks ago, when he had pain in the left side. He went to his doctor subsequently, who on March 5 drew off 15 oz. of whitish fluid and then sent him into hospital. The doctor subsequently stated that he had known of the fluid in the chest for at least twelve years. The patient walked into the ward and appeared in no discomfort. He had spinal curvature and consequent deformity, but otherwise was well developed and seemed well. Examination revealed no physical signs except in the chest. The spinal curvature was lateral, with the convexity to the right in the mid-dorsal region. On percussion the whole left side was dull back and front from top to bottom, the vocal vibrations, vocal resonance, and breath-sounds being everywhere completely absent. The heart was slightly displaced to the right, the right limit of the cardiac dulness reaching about one inch beyond the right edge of the sternum. The area of stomach resonance was absent. The upper border of the liver dulness on the right side was in its normal place. The other lung was apparently healthy.

The diagnosis made was that of pleuritic effusion. Accepting the doctor's diagnosis, it was noteworthy that the temperature was not raised.

On March 9, two days after admission, an exploring needle was inserted in the middle of the left axilla, and a thick whitish fluid like Devonshire cream was obtained. A rough examination made in the ward showed that it contained no cholesterin crystals, and very little fat, and no cells of any kind. Numerous bright refractive globules were seen, some of them staining with Sudan iii. No organisms were found, and the culture was sterile. On March 14 another puncture was made in the same position and an ounce of similar fluid obtained with difficulty.

The chemical report made by Dr. Hurtley was as follows: "The material submitted contains a large quantity of calcium phosphate, a small amount of fat, and a little sodium chloride.

There is no cholesterin; there is, further, some organic sub-substance the nature of which is not yet made out."

The substance obtained on exploration so much resembled what might have been found in a tuberculous gland which had undergone calcareous degeneration that it was carefully examined for tubercle bacilli but with negative results. It was possible also that the needle might have reached such a cavity, and that the fluid in the pleura was of a different character. Further exploration was made with the needle, which was passed in different directions, but no different fluid was obtained. It was evident, therefore, that the pleura was full of this substance, and the question arose whether it should be evacuated by operation. Such an effusion must have been of long standing (we did not at the time know that its existence was of twelve years' duration or more). The lung must, therefore, be in all probability completely collapsed and incapable of re-expansion. To empty the pleura of this fluid would have left an intractable cavity, which would probably become septic. As the patient was well in himself, and suffering no distress, it was decided to leave well alone and not interfere. The patient went on well till April 18th, when he caught a cold. Bronchitis developed and the breathing became difficult. A week later he had become very ill, with severe dyspnœa and a failing pulse. An exploring needle was again inserted in the hope that the fluid might in some way have changed in character and become more easy of removal, but no change had occurred. On May 1st the patient died of acute bronchitis. The temperature throughout was normal until the bronchitis developed, when it became irregular, reaching 102° or 103° in the evening.

The *post-mortem* examination showed that except for the condition in the thorax, the body was healthy. The curvature of the spine was not due to any disease of the bones, which were perfectly healthy. There was no sign of tubercular disease in any part of the body, unless two small calcareous glands in the mesentery not larger than peas were to be referred to this cause. The right lung was congested and œdematous and perhaps a little emphysematous. The right pleura was free from adhesions; it too was free from evidence of tubercle. The heart was slightly displaced to the right. The left pleura contained about four pints of cream-like fluid, similar to that which had been withdrawn during life. On excavating this the pleura was found to be generally thickened and to measure about one eighth of an inch all over. It was covered with a

white chalky lining which could be easily peeled off, leaving the pleural surface smooth. This lining varied in thickness from one sixteenth of an inch to about half an inch in the most dependent parts. In this lining were found very numerous irregular, flat, calcareous masses of various sizes and shapes. Most were free but a few adhered to the pleura. Some were quite tiny, the largest about an inch square, but most of them were about half this size or somewhat smaller. The greatest number lay in the posterior and lower part of the pleural cavity, near the spine. The pleural cavity was compared in appearance to a chalk-pit.

The left lung had to all intents and purposes completely disappeared. By tracing the bronchi of the left lung a small residue of somewhat pigmented fibrous tissue was found surrounding them, which possibly represented the lung, but this was all. The main bronchi themselves were natural and not dilated.

On the right side of the trachea, just above the bifurcation, a large calcareous gland was found the size of a small walnut, and two similar glands the size of peas were found in the mesentery. The spleen came down below the ribs but was not enlarged.

Microscopic sections were cut of the pleura and lung residue, and a bacteriological examination made of the pleural contents. No evidence of tuberculosis was found in them.

The following report of the chemical examination of the pleural contents was made by Dr. Hurtley:

"Water, 83 per cent.; dry residue, 17 per cent. (7·5 inorganic, 9·5 organic)."

Analysis of the inorganic material showed that it consisted of calcium phosphate with a little sodium chloride. The organic material was in part soluble in ether and consisted of fat and cholesterin. The part not soluble in ether was nitrogenous in character.

The interest of the case lies in the character of the pleural contents. So far as I am aware this case is unique. I have certainly never seen anything at all similar myself, nor have I succeeded in finding any case like it recorded.

When I saw the fluid first I thought it would prove to be an empyema which had undergone fatty change. The colour was against this, for in most of such cases the effusion has a distinctly yellow tinge and this was white. The rough examination made in the wards also disproved this, for little or no fat was found. The substance resembled most that

found in partially softened calcareous gland. On this analogy it might be referred to an empyema of very long standing, the cells of which had disintegrated and the products been absorbed in great part, while the residue became infiltrated with lime-salts. I have, however, never seen anything of this kind even in small, long-standing, localised empyemata.

Another point of great interest is the complete disappearance of the lung, the only trace of this organ left being apparently the small mass of pigmented fibrous tissue surrounding the bronchi at the root of the lung. I do not know of any other instance of such complete disappearance of a compressed lung.

Another question arises, whether the fatal result of the bronchitis could have been avoided by paracentesis. A patient with one lung only runs great risk with any affection of it; but the bronchitis was a primary one of an acute inflammatory character as shown by the fever, and not dependent in any way upon the condition of the opposite pleura, nor could evacuation have given any relief, for the parts were fixed by adhesions in the mediastinum and there was no lung left on the affected side to expand.

VII.—*Periodic Respiration.* By Samuel West, M.D.

Read November 24, 1905.

THE respirations under normal conditions follow one another with great regularity, as they do also when the breathing is accelerated or slowed. If under the influence of emotion or other causes, they become irregular; these irregularities are themselves irregular in their recurrence.

Sometimes, however, the respirations are grouped together in periods or phases, which recur with greater or less regularity—i. e. at more or less regular intervals; this is called "periodic respiration." Of "periodic respiration" there are two special forms; the best known is Cheyne-Stokes breathing.

In this form the groups of respirations are separated by long pauses, lasting 20, 30, or even 45 seconds, after which the respirations begin again, small at first, gradually increasing in range up to a certain maximum, and then gradually decreasing until they cease and the next pause begins. The rate of the breathing is much accelerated, so that the number of respirations may easily be 40 in the minute, even when there is a pause of forty seconds, so that while the breathing lasts it may be at the rate of 120 in the minute. These three features—(1) the long pauses, (2) the *crescendo* and *diminuendo* of the respirations, and (3) the rapid rate—are the essential characteristics of Cheyne-Stokes' breathing. The attacks come and go, may last a few hours or many days, with intervals of normal breathing, and are often more marked at night or possibly present only then. As a rule they generally increase in duration the longer the patient lives and may at last be continuous.

Cheyne-Stokes breathing, though met with occasionally in cerebral or bulbar affections, is much more frequent and characteristic with a failing left ventricle, and is then practically of fatal omen. Cases are recorded in which Cheyne-Stokes breathing has occurred in perfectly healthy persons and lasted for years or even for the whole of life. It is seen also in the aged during sleep without any other symptom. But the existence of these cases does not affect the general significance of the pathological group with which alone I am now dealing.

The second form of "periodic respiration" is called

"grouped respiration," for the respirations occur in groups of 2, 3, or 4 at a time. Each respiration is slow and deliberate and of approximately equal depth, while the intervals are rarely longer than ten or perhaps fifteen seconds, so that the rate of respiration is not more than 8 to 10 or 12 in the minute.

The difference between the two forms is well shown in the following diagrams, reduced from tracings.

These two forms stand in marked contrast with one another not only clinically, but also in prognostic significance.

Cheyne-Stokes breathing is a very serious symptom and

FIG. 6.

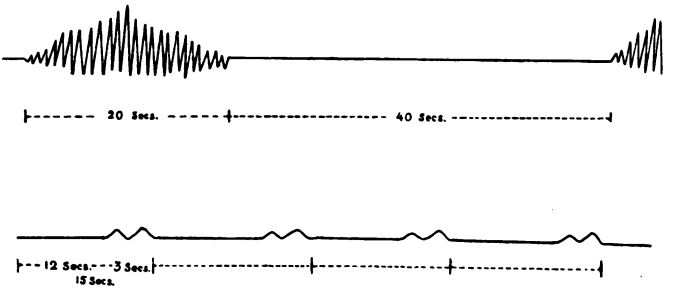

may be regarded as practically of fatal omen. In nervous affections it develops only in the last stages of a fatal disease, when the patient is moribund. In heart disease it may occur when there are no other signs of grave import observable, but its significance is the same and death will follow ere long, though it may be deferred a few weeks sometimes or even months. In heart disease, then, it is of the highest prognostic value.

Grouped respirations occur so far as I know only in meningitis and generally with the posterior basic form. It has, however, not the same prognostic value, for if the disease runs a favourable course the phenomenon will disappear.

VIII.—*On a Case of Relapsing Tetany associated with Dilatation of the Sigmoid Flexure.* By F. Langmead, M.D. (introduced by Dr. Garrod). *Read November* 24, 1905.

THE case is that of a boy, æt. 6 years, who was under the care of Dr. Garrod at the Hospital for Sick Children, Great Ormond Street, to whom I am indebted for permission to use these notes. He first came under observation in November, 1903, when he was admitted with a history of having always been thin and weakly and of having had frequent diarrhœa. His abdomen had been noticed to be unusually prominent. There had been rapid wasting for the preceding three weeks. He was found to be a thin, ill-developed, rickety child, having a strikingly aged appearance. His abdomen was very much distended, showing obvious intestinal coils. There was no evidence of ascites, nor could any masses be felt, yet in spite of these negative signs the general abdominal fulness, the wasting and the presence of enlarged glands seemed to favour abdominal tuberculosis as the most probable diagnosis.

While in the hospital he developed well-marked tetany of both the upper and lower extremities, accompanied by marked facial irritability. Associated with this there were very unhealthy motions, which were large and pultaceous and greyish-green in colour. Intestinal antiseptic treatment by means of bismuth salicylate was ineffectual, and improvement was only started by irrigating the lower bowel every morning. Under this treatment he steadily gained weight and his tetany disappeared synchronously with the appearance of healthy motions. His abdominal condition remained the same.

In February, 1904, three months after admission, he was discharged.

He was re-admitted in March with another attack of tetany, which was said to have started soon after he had left the hospital. The disease had now assumed a very severe form. His hands and feet were in an exaggerated tetanic position (Pl. IV), the hands being flexed on the fore-arms at an acute angle. The spasm was sufficient to cause him to cry out from pain, and it was found necessary to use chloroform to give him relief. His motions had the same appearance as on the first admis-

PLATE IV.

Illustrating Dr. Langmead's Case of Relapsing Tetany associated with Dilatation of the Sigmoid Flexure.

Bale and Danielsson, Ltd.

UofM

sion. Nothing fresh was noted about the abdomen. Three weeks later he was again discharged, free from spasm.

A fortnight after he was admitted for the third time, with a history of increased abdominal distension, offensive stools, and tetany for a week. On this occasion the abdomen, as before, was tense and distended, but now in addition a definite viscus could be seen standing out in the left hypochrondriac and lumbar regions. This at first was thought to be a dilated stomach, and the condition to be that of gastric dilatation with tetany, occurring at an unusually early age, but while washing out the stomach its limits could be clearly defined

FIG. 7.—A. Sigmoid flexure. B. Liver. C. Suspensory ligament of the liver. D. Coils of small intestine.

by palpation and percussion and were found to be normal. The viscus was consequently considered to be the transverse colon. He was discharged free from tetany in June and had no recurrence until January, 1905, seven months later. Then he was admitted for the fourth time with very severe tetany and porridge-like stools. As before, a viscus could be plainly seen standing out above and to the left of the umbilicus. Careful dieting, gastric lavage, and intestinal antiseptic treatment were tried for a month, and did no good. Rectal irrigation was then tried as on the first occasion, and from that time he improved rapidly, losing tetany and quickly gaining weight.

He was redischarged very much better in March, 1905, three months after admission. A fresh symptom had occurred which was very puzzling, namely hæmaturia associated with slight albuminuria. He had been outside the hospital only a fortnight before he was admitted for the fifth time with diphtheria and tetany, which proved rapidly fatal.

Post mortem.—I found the body to be that of a very poorly nourished undersized child. There was severe faucial and laryngeal diphtheria and secondary broncho-pneumonia. With regard to the previous symptoms and signs the abdominal condition was of greatest interest. Here it was at once evident that there was an unusual arrangement of intestines. The sigmoid loop occupied the greater part of the left side of the cavity, reaching up to the costal margin and hiding the stomach from view. No coils of small intestine could be seen except those which lay to the right of the mid-line, the others being displaced by the sigmoid. The rectum too was much ballooned, whilst at the junction of the rectum and sigmoid was a more constricted zone, but even here the lumen was certainly as large as normal. The rectum and sigmoid together held about eleven ounces of fluid. This distended loop was attached to the posterior abdominal wall by a long mesentery, measuring six inches from the centre of the loop. There was a second peritoneal attachment by a fold which ran from this mesentery close to the gut to the hepatic flexure of the colon, forming a crescentic, sharp edge, crossing the mid-line about the level of the umbilicus. The walls of the sigmoid appeared slightly hypertrophied. Neither the rest of the intestine nor the stomach was dilated. The hæmaturia found its explanation in the presence of two calculi in the pelvis of the right kidney. One was a coral calculus weighing sixty-three grains, the other a smaller, smooth calculus occupying a single calyx, and weighing five grains. Chemical examination proved them to be uric acid. There was no apparent destruction of kidney-tissue. There was no change in the neuro-muscular system detectable by the unaided eye.

Dr. Graham Forbes kindly examined the sigmoid histologically and reported that there was necrosis of the cells of the glands and of the lymph-follicles. The muscularis mucosæ was thickened. There was no change in the circular or longitudinal muscular coats. His report of the median and ulnar nerves was that there were evidences of early neuritis such as was compatible with fatal diphtheria. The anterior cornual cells were, unfortunately, not examined, but in view of

the periods of complete recovery no great change was possible, and a slight change would have been obscured by the action of the diphtheria toxins.

The interesting features of this case were its association (*a*) with dilatation of the sigmoid flexure (*b*) with renal calculus.

(*a*) The concurrence of gastro-ectasis with tetany is, of course, now thoroughly established, nearly ninety cases having been put on record, but in a fairly exhaustive search in the literature of this subject I have only been able to find one other case where local dilatation of intestine occurred. This is one recorded by Dudley Greenfield (1) in 1903. In this fatal case there was local dilatation of the upper part of the jejunum.

(*b*) Abnormal renal conditions have been occasionally found. Imbert-Gourbeyre (2) and Hoffmann (3) each described a case of tetany with acute nephritis, and Blasicek (4) Trevelyan (5), Wick (6), and Moorhead (7), each cases with cirrhosis of the kidneys. Gumprecht (8) found the urotoxic equivalent increased, while Jacobson (9) and Ewald (10) isolated a poisonous albumose from the urine but in quantities too small for animal experiments. I can find no record of the association of tetany with renal calculus, yet in the *post-mortem* books of the Hospital for Sick Children there are ten fatal cases of tetany and in three of these renal calculi were found. This gives a percentage of thirty, which is altogether beyond the average proportion of renal calculus *post mortems*, these being only about 0·45 per cent. The explanation of this association is problematical; but taking into consideration the urinary changes which have been found, it seems feasible, as has been suggested in the case of nephritis, that the calculi are the product of the irritative effect of toxin-laden urine.

There seems no doubt that the tetany in this case was due to the dilatation of the sigmoid flexure. The invariable association of abdominal distension and pain and of foul, pultaceous motions with the attacks and the immediately beneficial effect of irrigation of the large intestine point definitely in that direction. The actual pathogeny of tetany in cases of gastric dilatation is still a much disputed point, but the trend of opinion is now in favour of regarding it as the result of the action of a poison produced in the stomach on nerve-cells. An important experimental evidence of this is the work of Bouveret et Dévic (11), who in three cases of tetany associated with gastric dilatation isolated a substance from the stomach

contents which produced the picture of tetany when injected into animals. As far as one case can go, this one shows that the stomach element is not essential and that the toxin, whatever it is, can be equally well formed lower in the alimentary tract, for in this case there was no evidence of any gastric abnormality.

This would bring gastric tetany more closely into line with the tetany of infants, for in these there is almost invariably something to point to an abnormal condition of the alimentary tract. Out of 22 cases of children with tetany under observation as in-patients at Great Ormond Street in the last ten years, 12 had diarrhœa, 3 had unhealthy motions and 11 vomiting. Of only 2 is there no record of either diarrhœa or vomiting.

This case, I think, is one more witness in favour of the toxæmic origin of tetany, but a toxæmia produced under variable circumstances and probably due to a variety of toxins.

References.

1. Dudley Greenfield, *Lancet*, vol. ii, 1903.
2. Imbert-Gourbeyre, *Art. Med. Paris*, 1861, vol. xiv, and 1862, vol. xv.
3. Hoffmann, *Deutsches Arch. f. klin. Med. Leipsic*, 1888, vol. xliii, 53.
4. Blasicek, *Wien. klin. Woch*, 1894.
5. Trevelyan, *Lancet*, 1898, vol. ii, 796.
6. Wick, quoted by Risien Russell, Clifford Allbutt's *System of Medicine*.
7. Gilman Moorhead, *Practitioner*, July, 1904.
8. Gumprecht, *Centralblatt für klin. Med.*, 1897, No. 25.
9. Jacobson, quoted by Risien Russell, *loc. cit.*
10. Ewald, quoted by Risien Russell, *loc. cit.*
11. Bouveret et Dévic, *Compt. Rend. Soc. de Biol.*, 1891, vol. ii, 823.

LIBRARY

Bale and Danielsson, Ltd.

PLATE V.

Illustrating Mr. J. Jackson Clarke's paper on the Present Position of the Treatment of Congenital Dislocation of the Hip-joint.

IX.—*The Present Position of the Treatment of Congenital Dislocation of the Hip-Joint, illustrated by an Account of the Results in two Series, each of ten consecutive Cases.* By J. Jackson Clarke, M.B.Lond. *Read December* 8, 1905.

On a previous occasion before this Society I have expressed the opinion that a just appreciation of the value of Lorenz's manipulative method of treating congenital dislocation of the hip can only be arrived at by the study of the results obtained in a considerable number of consecutive cases, the patients being within the prescribed limits of age—*i.e.* up to eight years in bilateral and up to ten years in unilateral cases.

The results of two such series of cases have already been published in this country by Burghard * and Openshaw; † the former had one success in ten, the latter three "good results" in twenty cases.

These results were so unsatisfactory that both surgeons relinquished the method, reverting to the open operation, which Lorenz, after an unrivalled experience of it, had definitely abandoned in 1896 in favour of his manipulative method. My own results with the latter had up to the year 1903 been as unsatisfactory as those of Burghard and Openshaw, only an occasional success being obtained. This had led me to try the open operation in one instance; and it might have led me to abandon manipulative methods had I not been convinced, by some dissections I made some fifteen years ago in a case of double congenital dislocation, that this deformity ought to be curable by manipulation if the right way could only be found. Lorenz's visit to this country in 1903 and his patient demonstration of every technical detail of his method enabled me to see wherein lay the sources of failure.

The two series of cases the results of which are detailed below comprise all the patients under the age of ten years whom I have treated for congenital hip-dislocation since the beginning of 1903.

In the first series the ages of the patients varied from three to nine years and two of them were cases of bilateral dislocation, thus there were twelve joints. Of these nine are cured. In three the head of the femur was "anteverted," as it is termed, at the operation. Of these anteversions one has

* Burghard, *Brit. Med. Journ.*, October 19, 1901.

† Openshaw, *Clin. Soc. Trans.*, 1903, p. 146.

relapsed, one is doubtful, the third is firmly established, the head of the femur being placed beneath the anterior superior spine, and the new joint having a full physiological range of movement; this patient is a girl æt. 8, who had bilateral dislocation; she now walks as firmly with this "anteverted" joint as she does with the other, which is completely cured. In the second series, also of ten cases (ages of patients being from two to nine years), there were three double dislocations. Complete anatomical reduction has been effected in every one of these thirteen joints. In neither series of cases was there any kind of operative mishap.

In connection with one of the cases belonging to Series 1 that I showed before this Society (October 28, 1904) Mr. Tubby expressed a vigorous scepticism as to the patient being on her way to be cured, and suggested the need of a committee of this Society to inquire into the method. Since that occasion, in replying to a paper that I read at a provincial meeting, Mr. Tubby has accepted * my view and expressed himself as being grateful for my description of the method; more lately, from a study of results obtained by surgeons other than himself, he has written † that "The results of the last two years' work seem to show that in the future the irreducible cases will gradually diminish to a vanishing point." It is a pleasure to me to find Mr. Tubby agreeing with this view, which I have previously held on the basis of pathological study and personal clinical work. I venture to submit that this view is now proved to be correct by the second of the two series of cases that I bring forward to-night.

The accompanying plates (V and VI) are from photographs of the patient, Amy T., of the first series. Pl. V shows the profile on the date of her second appearance before the Society early in 1905, that is, when the "sub-pubic" position of the head of the femur had been corrected and the head of the femur placed upon the acetabular surface. At this time the degree of flexion of the hip shown in Plate V was rigidly maintained by muscular spasm, and it was no doubt due to want of harmony between the joint-surfaces. There was also a fixed abduction of about 30°. The remaining two illustrations show the condition about a year later. In Pl. VI A the left thigh is seen to fall naturally into hyper-extension, and in Pl. VI B the degree of voluntary flexion is shown. This restoration of normal function to the reduced hip was aided by the simple exercises recommended by Lorenz.

* A. H. Tubby, *Reports of the Society for the Study of Disease in Children*, 1905, p. 294. † A. H. Tubby, *Practitioner*, November, 1905, p. 683.

PLATE VI.

Illustrating Mr. J. Jackson Clarke's paper on the Present Position of the Treatment of Congenital Dislocation of the Hip-joint.

A

B

Bale and Danielsson, Ltd.

MTSU

X.—*A Case of Typhoid Fever with Peritonitis but no Perforation in which Laparotomy was performed.*

By E. W. Goodall, M.D. *Read December* 8, 1905.

THE patient was a boy, æt. 10, who was admitted to the Eastern Fever Hospital on August 21, 1905, certified to be suffering from typhoid fever. The history was that he had been quite well on August 12, on which day he had been taken from his home in Hackney Wick to Caterham on a visit. The next day he felt poorly and had a headache, and on the 14th he had diarrhœa. As he became worse he was brought home on the 17th, and he then complained of abdominal pain. He was sent to the hospital on the ninth day of the illness.

The previous history, subsequently obtained from the mother, was that at the age of six weeks the boy suffered from "consumptive bowels"—that is, diarrhœa, vomiting, and cramps; he was very ill and not expected to recover. At four and a half months he had pneumonia. While teething he again suffered from diarrhœa. He had always been subject to looseness of bowels, some articles of food being especially prone to cause this; at times he had passed blood. On admission the patient did not appear to be very ill, his temperature was 103° F. and his pulse 108. He complained of pain in the lower part of the abdomen, but the pain was not severe. The abdomen was slightly distended and its walls tense. The spleen could just be felt below the ribs. The liver dulness extended from the fifth rib to the costal margin. The tongue was furred, but moist. There were a few suspicious, faded, rose spots on the trunk. There were no adventitious sounds in the lungs, and save for a slight systolic murmur, heard best at the apex, the heart was normal. There was no albumen in the urine, which gave Ehrlich's diazo-reaction. Next day there were definite spots, and the diagnosis of typhoid fever was made. The serum reaction was not investigated till September 16, when a 1 in 50 dilution gave a positive result. From the day of admission to August 31 there was nothing eventful in the history of the case. The temperature ranged from 97·8° to 103°, oscillating considerably, and being lowest in the morning and highest in the evening. The four-hour chart was like that usually seen at the commencement of convalescence. From mid-day on the 28th to the morning of the 31st the highest recorded temperature was 100·2°. The pulse and res-

piration varied with the temperature, from 72 to 114 and from 20 to 28. The bowels were moved only by enemata. There was no abdominal pain during this period. When the medical officer went his round in the forenoon of the 31st, the nineteenth day of the illness, the patient was complaining of abdominal pain, but it was not severe. He noted that there was slight distension and slight general rigidity of the abdomen, which, however, moved well on respiration. The liver dulness was as on admission. The pulse was 100, slightly irregular, but of fair volume. At 6 a.m. the temperature had been 101·6°. It fell to 99·8° at 10 a.m. and 98·6° at 2 p.m. The pulse varied from 100 to 112, whereas it had seldom been so frequent as 90 during the previous two days.

At 3.40 p.m. the medical officer was sent for by the nurse because the patient was crying with pain in the abdomen. He could not detect any sign that was markedly different from what he had found in the morning. The patient's appearance was neither anxious nor distressed. He gave the boy some morphia. I saw the case at 4 p.m. and noted that the abdomen was slightly distended and rigid all over. There was some impairment of resonance all over the right side. The pulse was 102 and of good volume. At 5 p.m. the pulse was 112, the patient had no pain except on percussion, and then only in the right iliac region; he was drowsy. At 6.45 p.m. the pulse was 104, rather smaller, the patient was still drowsy, the abdomen was more distended and rigid. At 6 p.m. the temperature went up to 104°; there was no vomiting; on palpating the abdomen the patient flinched only when the right iliac region was touched. It appeared most probable that perforation had occurred, so, the consent of the parents having been obtained, operation was decided upon. After 5 o'clock nothing had been given by the mouth. The patient having been put under chloroform at 8.10, the abdomen, which had become more distended, was opened by an incision in the middle line below the umbilicus. A little dark red serum escaped. The coils of intestine were considerably distended; one or two were soon found which had small patches of lymph on them. The small intestine joining the cæcum was found and the whole of the small intestine was examined without a perforation being detected; in fact, the lower two or three feet were examined three times most carefully. The cæcum appeared normal, as did the sigmoid flexure and the portion of the descending colon adjoining it. Scybala could be felt in this part of the bowel. But though

no perforation could be found there was a good deal of peritonitis. This was limited to the last foot or so of the small intestine, though some coils further away but lying against the former were also affected. The peritonitis near the valve was most intense, the peritoneum being most acutely inflamed and covered with many large and thick patches of lymph. Some of this lymph could be wiped off and was evidently quite recent; but a good deal of it could not, being very firm to the touch and firmly adherent to the bowel. These patches of lymph were mostly situated on the bowel close to its mesenteric attachment, but some were found on the mesentery. In some places there were small hæmorrhages beneath the peritoneum, and some of the adhesions, on being separated, bled a little. The serum and lymph were not at all offensive. The mesenteric glands were much enlarged. Three or four small yellow nodules were seen, looking like glands about to break down. I incised one about the size of a pea and expressed it from its capsule. The little mass was microscopically examined afterwards and found to consist of lymphoid tissue only. None of the glands were fluctuating, though they were very soft. I could feel ulcers, or what seemed to be ulcers, in the last few inches of the small intestine, but the situation of the thick patches of lymph did not correspond to ulcers or the usual sites of ulcers. The appendix could be felt, but as it was adherent to the peritoneum over the psoas I could not bring it into view. I could not find any recent lymph about it, and it felt normal. As the peritonitis was limited to the neighbourhood of the ileo-cæcal valve and the gut became healthy further away, no more examination was made than what I have stated above. I got out two or three good-sized masses of lymph which appeared to be free in the peritoneal cavity. The pelvis and flanks were swabbed dry and the abdominal wound stitched up with silkworm gut. It was nearly 9.30 before the boy was put back to bed, as the search for a perforation had taken up so much time.

With the exception of abscesses in connection with the two upper stitches the patient made an uneventful recovery, and I do not think that these would have occurred if the boy had not on the night following the operation pushed his fingers under the dressings and picked at the sutures. The temperature never again rose above normal nor the pulse-rate above 120. By September 7 the distension quite subsided. The patient was discharged from the hospital on October 21 in excellent condition; he had grown quite fat. The abdomen

appeared to be a little prominent in its lower half, but I could not make out anything amiss with it. The boy was brought to see me a week later, because he had passed a little blood in his stools, as he had done occasionally before the attack of typhoid fever; but he did not seem to be any the worse for this occurrence.

The signs which induced me to operate in this case were abdominal pain and rigidity, coming on somewhat suddenly; tenderness on pressure in the right iliac region; increase in the pulse-rate; and the rise of temperature to 104°. These signs are, in my opinion, sufficient to justify the diagnosis of perforation, yet undoubtedly in a few instances the abdomen may be opened when signs even more suggestive than these are present, and no perforation will be found. It is difficult to arrive at certainty in diagnosis at an early stage, yet an early operation is most desirable in the majority of cases. Consequently he who has many opportunities of operating early for perforation in typhoid fever is certain now and then to meet with a case in which no perforation has occurred; sometimes, indeed, there may be not even peritonitis. In 3 out of 21 laparotomies at the Eastern Hospital no perforation has been found. In the first case the peritoneal cavity was normal; the patient had been admitted with symptoms pointing to perforation; possibly they were due to a right basal pleuro-pneumonia which was subsequently found. In the second case severe peritonitis was present, the patient died two and a half days after the operation, and a perforation was discovered at the autopsy. The third case is the subject of this paper.

The slightness and short duration of the symptoms are remarkable compared with the intensity of the peritonitis, which must have existed for several days. But I have observed in two or three cases of perforation in which I have operated that the peritonitis has been much more intense than the symptoms had led me to expect. I have no doubt that peritonitis may precede perforation by several days. The distribution, however, of the peritonitis in the present case suggests that it was not due to a perforation which had been almost immediately sealed with lymph.

The patient's history suggests that he was the subject of disease of the bowels or mesenteric glands in early childhood; possibly some morbid condition resulting from this former illness may have determined the peritonitis during the attack of typhoid fever.

XI.—*Septic Peritonitis occurring early in the Course of Typhoid Fever apart from Perforation (with a Temperature Chart).* By W. G. Spencer, M.S. *Read December* 8, 1905.

ACUTE septic peritonitis may occur early in the course of typhoid fever and prove rapidly fatal. Four cases recorded during the first months of 1905 may be cited.

(1) By Mr. Gordon Watson, *Lancet*, 1905, i, 1197, March 6. A boy, æt. 9, was seized with fever and headache attended by shivering. From the sixth day of the illness abdominal symptoms supervened. On the seventh and eighth days he had abdominal pain, vomiting, and delirium. On the tenth day he was admitted to the Metropolitan Hospital on the diagnosis of general peritonitis following appendicitis. He was operated upon at once, and the peritoneal cavity was found distended with thin, white, odourless pus and there were flakes of fibrin in the intestines, but there was no gas. The mesenteric glands were enlarged, but the appendix was unaffected. The patient died seven hours after the operation. At the *post mortem* the intestines were found congested, especially in the ileo-cæcal region; in the small intestine were several early typhoid ulcers and some swollen Peyer's patches, but no sign of perforation. The spleen was much enlarged and both from it and from the heart's blood pure cultivations of the typhoid bacillus were obtained. The enlarged mesenteric glands showed no active inflammation nor tendency to break down, and were considered tuberculous.

(2) M. Courtois Suffit et M. Beaufumé, *Bull. et Mém. Soc. Med. d'hôp de Paris*, 1905, 3 s. xxii, 238, March 17. A youth, æt. 18, was admitted on the eleventh day of his illness. Widal's reaction was well marked and the temperature about 104° F., at which it remained in spite of treatment by cold baths (61° F.) until the twenty-first day. Suddenly the patient was seized with acute pain in the *left* iliac fossa, followed by collapse, hiccough, and vomiting. The face was pinched but there was no tympanites, and the liver dulness was unaltered. The abdomen was opened eight hours after the commencement of the acute symptoms. About 1½ litre of brownish-yellow odourless fluid containing whitish particles

of fibrin escaped from the peritoneal cavity. The intestinal coils were congested and adherent, but there was no gas nor sign of perforation, and the appendix was healthy. The mesentery contained enlarged glands, but none of these had broken down. The patient died about seven hours after the operation. At the *post mortem* about half a litre of yellowish-brown fluid was found in the pelvis. The ileum and the ascending colon were congested, and the intestines were covered with fibrin for two metres above the ileo-cæcal valve. In the ileum were numerous typhoid ulcers from which some hæmorrhage had occurred into the bowel. But the absence of any sign of perforation, as also of disease of the appendix, was confirmed.

Two other cases may be more briefly mentioned.

(3) Josias, *Rev. d'Hyg. et de Méd. Inf.*, Paris, 1905, iv, 1; also *Pediat. prat. Lille*, 1905, iii, 61. In a child an acute onset of typhoid fever simulated at first appendicitis, then general tuberculosis. Death occurred on the tenth day. At the *post mortem* there was no sign of appendicitis nor of meningitis, but the lesions of typhoid fever, with septic peritonitis, without perforation.

(4) Thirion, *J. de Sc. Méd. de Lille*, 1905, i, 496. In the course of typhoid fever suppurative peritonitis supervened without perforation and death followed.

Fortunately, the case to be related which came under my observation I was able to operate at an early stage, so that the peritonitis was checked, and the patient ultimately recovered after passing through a severe course of typhoid fever.

A boy, æt. 12, previously in very good health, travelled from America and immediately on arrival was seized with pain in the abdomen, followed by vomiting and distension. I saw the boy on the third day in consultation with Dr. Davidson, of Uxbridge. He looked ill, with a thickly furred tongue, a temperature which had reached 105° F. and was then 104·2° F., a pulse of 110, and tympanites, which had not been relieved by free movement of the bowels. Pain was complained of in the right ileo-cæcal region where there was an impaired percussion note and a sense of resistance. No rash was present. The only point differing from an appendix case was that the motions were pale, pasty, and odourless. I operated at once on the diagnosis of acute septic peritonitis. The appendix was found bent at its middle and its peritoneal coat, along with adjacent surfaces of the ileum and cæcum, congested, but not otherwise altered. There were four mesen-

teric glands enlarged to the size of filberts, which formed the resistance felt beforehand. The intestines were smeared with greasy fluid, without fibrin or adhesions, and in the pelvis was a pool of reddish turbid fluid. This was sponged away until the peritoneal cavity was quite dry, and the fluid was squeezed out into a dish, but I forgot to preserve it for examination. A drainage-tube was passed down into the pelvis and the rest of the ileo-cæcal incision sewn up. After the operation I felt doubtful whether the case was one of streptococcal peritonitis, so the next day some antistrepto-

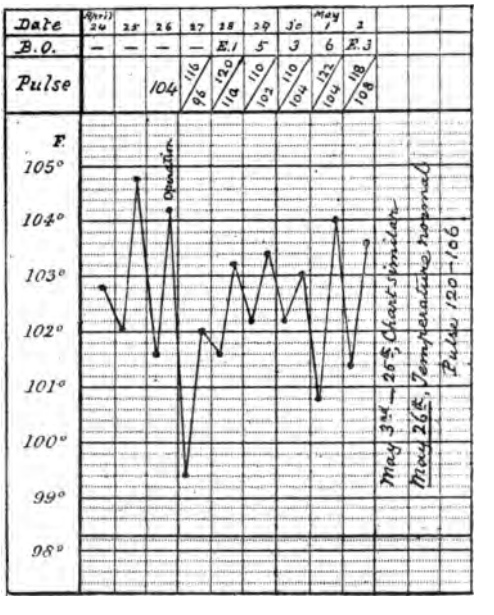

coccal serum was administered without affecting the patient either way.

Four days after the operation Dr. Davidson informed me that a positive Widal's reaction had been obtained. From the time of the operation the peritoneal symptoms subsided, but the patient suffered severely from typhoid fever which was complicated by delirium and violent screaming fits, during which the patient was seen by Dr. Cheadle. The temperature chart kept by the nurses shows that the temperature continued at about 103° F. for five weeks and when it became normal the

pulse was still between 110 and 120. The wound was somewhat disturbed by the patient's restlessness, but ultimately healed soundly without any sign of hernia. The boy is now in good health again.

Such cases presumably are due to a specially virulent infection which extends through the intestinal wall at a period preceding the time when the floor of the typhoid ulcer approaches the peritoneal coat. There is an exudation of brownish turbid fluid, and in the later stages fibrinous exudation, but the organisms present in the exudation have not yet been reported. Gas is absent. The mesenteric glands are enlarged but not breaking down. The cases above noted clearly differ from those of perforation, or even of those in which the floor of the ulcers have reached the peritoneal coat. Also they differ from those in which the appendix is diseased and perforated, such as are mentioned by Dr. Rolleston in the Society's *Transactions*, 1898, vol. xxxi, p. 234, as occurring in the course of ambulatory typhoid fever. Dr. Cushing's statistics showed that 9·6 of all perforations in typhoid fever occurred in the appendix. Typhoid fever has also determined the rupture of a pyosalpinx or of a gall-bladder.

The important point to recognise is the existence of acute septic peritonitis, upon which it is necessary to operate at once. The diagnosis of the typhoid fever may not be possible for days. The signs of acute septic peritonitis with pain and resistance in the ileo-cæcal fossa naturally give rise to the diagnosis of appendicitis. But the cause of the peritonitis is for the moment immaterial.

A second case, a boy æt. 12, had signs of acute septic peritonitis with extreme tympanites in the third week of an obscure fever. I had operated on his younger brother a year before for acute perforative appendicitis. The conditions found at the operation were practically identical with the case above described. Soon afterwards the temperature became normal and convalescence set in. The case was supposed to be one of masked typhoid fever, but the repeated examination of the blood, also of the peritoneal fluid, only resulted in the finding of colon bacilli in the latter. Convalescence was slow; the boy began to walk about two months after the operation.

XII.—*A Case of Traumatic Pancreatic Pseudo-Cyst.*

By Thos. H. Kellock, F.R.C.S. *Read December* 8, 1905.

J. H., æt. 20, a groom, was admitted to the Middlesex Hospital under the care of Mr. Henry Morris on January 22, 1904, with the following history:

His family history was quite good and he had never suffered from any serious illness. On the day of admission, whilst following his occupation, he was kicked in the lower part of the front of the chest by a horse to which he was attending. He was not knocked down by the blow, but felt dazed and described his sensation as "having all the wind knocked out of him."

On admission he was described as a healthy-looking young man in a somewhat collapsed condition, complaining of a dull pain about the region of the umbilicus. His temperature was 96·4° F., pulse 60, intermittent in character.

On examination the mark left by the horse-shoe could be plainly seen in the middle line over the lower part of the thorax and upper part of the abdomen extending downwards to within about two inches of the umbilicus; no fracture of ribs or costal cartilages was found; the abdomen was not distended and moved freely with respiration; nothing abnormal was detected on palpation, which did not seem to cause much pain. A soft, systolic bruit was heard at the apex of the heart.

The urine was acid, s. g. 1030; it contained some urates and a faint trace of albumen, no blood or sugar. After admission he vomited repeatedly. The vomit is described as bilious, but there was no hæmatemesis. In the evening the temperature rose to 100·4° F., the pulse remaining irregular. He still complained of pain about the umbilicus.

On January 25 the vomiting continued, the temperature was irregular, pulse 72. Some dulness was found in the left axilla, reaching forwards to the mid-axillary line and backwards in a curve to the base. He complained of pain in this side in addition to that in the epigastrium.

During the following three weeks the vomiting ceased, but was succeeded for a time by retching, the temperature was

irregular, often reaching above 100° F. in the evening; the pulse regained its regularity, the pains in the side and abdomen continued, and were made worse by taking food; on one occasion he had slight diarrhœa, but as a rule the bowels acted regularly, and there was nothing abnormal noticed in the stools. The dulness in the left chest remained unaltered.

On February 18 Dr. Kingston Fowler saw the patient and examined the chest. He thought there was a small pleural effusion at the left base, but did not advise any interference.

On February 23 dulness was noted in the left hypochondriac region extending forwards to the middle line, and slight bulging of the lower ribs on the left side. A small quantity of albumen was present in the urine, but no blood or sugar. He complained of a little difficulty and pain on micturition, which he performed frequently, passing small quantities at a time; the total quantity passed was about normal. The temperature was still markedly irregular. Four days later he complained of a great deal of pain and tenderness in the abdomen, which was found to be tense and rigid about the upper part. He had a little cough, with some muco-purulent expectoration, in which no tubercle bacilli were found on examination. He was getting very weak and losing flesh rapidly.

On March 1 the pain was still great and vomiting recurred. The pulse rate had risen to 120; respirations 36, almost entirely thoracic. An exploratory puncture was made in the ninth left interspace in a line with the vertebral border of the scapula; 1¼ oz. of turbid fluid was withdrawn, which on examination was reported to be sterile. Very little relief of the symptoms followed.

On March 3 Dr. Kingston Fowler again saw the patient and agreed with Mr. Morris that the chief trouble was subdiaphragmatic, but thought that it was best to watch the case a little longer before operating.

Three days later the patient was manifestly worse, the pain was great, vomiting troublesome, and respiration laboured. The rigidity and fulness of the upper part of the left side of the abdomen were more marked, reaching from the costal margin to the umbilicus, a fluid thrill being obtainable over it. The heart's apex beat was displaced upwards to the third interspace.

The urine contained no fresh abnormal constituents, but had very considerably lessened in quantity. The patient had become very white, thin, and weak.

In Mr. Morris's absence I was asked to see the patient, and thought it advisable to operate. An anæsthetic having been given, a three-inch incision was made over the ninth rib in the anterior axillary line, the periosteum reflected, and about an inch and a half of the bone removed. On incising the inner side of the periosteum, the diaphragm was at once seen pressed tightly against the chest wall. An incision made through this opened a large cavity, from which clear fluid escaped at considerable pressure. A finger passed through the opening was found to be in the lesser sac of the peritoneum; the posterior wall of the stomach was felt and a soft movable mass, which, when drawn into the wound, proved to be a piece of omentum, normal in appearance, except for some injection of its vessels. The finger could not reach all the limits of the space containing the fluid, which was then allowed to escape slowly. In all 88 oz. were collected. A drainage-tube was inserted and the edges of the skin wound closed round this by one or two horse-hair sutures. The immediate relief to the embarrassed respiration on the escape of the fluid was very marked.

The fluid was straw-coloured and odourless. The report on its nature from the Clinical Laboratory was as follows:

"The fluid contains a small quantity of fresh blood, reaction alkaline. It contains 7 parts per 1000 of proteid material precipitated by picric acid. It contains an active diastatic ferment and also a peptonising ferment, which acts in an alkaline medium. No micro-organisms have been found in it either by microscopical examination or by culture."

On the morning following the operation the patient expressed himself as very much easier, but complained of tenderness and shooting pain on the right side of the abdomen and of pain on micturition. The dressings, when removed, were found very wet. The urine was acid, contained a large trace of albumen, but neither blood, pus, nor sugar, the quantity still small (28 oz.).

For the next three days considerable difficulty was experienced in keeping the cavity drained, as something seemed to obstruct the inner end of the tube, and even when this was taken out and replaced very little fluid came away. The general condition was unaltered. The pain in the abdomen continued and necessitated an anodyne at night. The temperature kept about normal, but the pulse was rather fast (100–108). The bowels acted regularly, the stools being apparently normal.

On March 12 the swelling in the left hypogastrium was found to have re-formed, and respiration was again interfered with. An anæsthetic was given, the wound explored, and 70 oz. of fluid of the same nature as before liberated. Another opening into the cavity was made further back below the ribs, and a large drainage-tube inserted into both openings. For a few days these drains acted satisfactorily, the dressings being soaked when renewed twice a day. The patient seemed considerably better and had less pain.

Seven days later the fluid had again accumulated in the cavity, and on passing a Boudin's glass tube into it through the upper wound 100 oz. of fluid were drawn off. A glass drainage-tube was tied into the opening and acted well for two days, when the discharge of fluid ceased rather suddenly and the patient seemed worse again and complained of a good deal of pain.

On March 22 there was again an accumulation of fluid, which was drawn off by means of a gum elastic catheter (28 oz.). The catheter was left in position and a rubber tube attached to it leading into a bottle at the side of the bed, and this for some time acted well. The average quantity of fluid which passed into the bottle was just 28 oz. a day, and whilst this was passing the patient was in comparative comfort and improved in condition. A temporary block in the tube on April 7 brought about a fresh attack of pain and a little rise of temperature, which had been keeping practically normal. The amount of fluid discharged became much less, and on April 17, as there was some difficulty in re-inserting the catheter, it was left out. A very little fluid came from the wound after this, but the cavity did not appear to be filling, and the patient seemed quite comfortable. There was great epigastric pain on April 22 but no obvious distension; a catheter was passed into the wound but no fluid escaped; a fomentation applied to the front of the abdomen relieved the pain. The urine at this time was normal. From this date the patient steadily improved. There was no further discharge of fluid and the wound healed; the abdominal pain only troubled him slightly and at intervals. He was discharged to the Convalescent Home on May 12.

Dr. Kingston Fowler kindly examined the chest previous to his discharge. He found feeble breath sounds and diminished vocal fremitus over the lower lobe of the left lung. He considered the expansion of that part of the lung was probably hampered either by the old pleurisy or by diminished

descent of the diaphragm. The heart had returned to its normal position.

I saw the patient one month after his discharge and found he had improved very considerably, and said he had increased 28 lb. in weight. The wounds were perfectly sound, and he complained of no pain or tenderness in the abdomen, in which nothing abnormal was to be detected on examination. Five months later, at my request, he came to see me, and said he was in excellent health and at work as a gardener.

The condition in this case seems to have been that described as pancreatic pseudo-cyst; for the presence in it of a piece of omentum and the dysuria and tenderness over the lower part of the abdomen would seem to show there was no definite cyst wall to limit the distribution of the fluid. A fair number of such cases have been recorded, but few in which posterior incision and drainage have been employed. The result in this case would seem to indicate that this method is as good as that generally advised through the abdominal wall in front.

Points of interest in this case are: The comparatively little irritation set up in the peritoneum by the presence of the fluid; the large quantity of the latter that escaped whilst the drainage was going on, although this may have been diluted by serous exudation from the peritoneum; and the somewhat abrupt way in which the fistulous opening into the substance of the pancreas or its duct must have eventually closed.

A case which in many respects closely resembled this one, but which terminated fatally, was reported to this Society by Dr. Sidney Phillips in 1901. His patient was a young man who had also received his injury by the kick of a horse in the upper part of the abdomen, and some months later developed a very large pancreatic cyst. In that case, too, there was at the same time some effusion of fluid in the left pleura. The report of the *post-mortem* examination describes a cyst wall varying from one sixteenth to three eighths of an inch in thickness, and coated inside with material resembling coagulated lymph, but from the report of the operation performed it would seem probable that the cyst wall was of secondary formation, brought about by the presence during several months of a quantity of pancreatic fluid free in the peritoneal cavity.

Volume XXV of the *Transactions* of this Society contains a paper on the same subject by Mr. H. Littlewood, with the

report of a case under his care, and he has collected there the records of five other cases that had been treated by operation, all successfully; in his case and in one of those to which he refers (Mr. Jackson's) the injury had been inflicted by the kick of a horse, so that in four out of eight cases this form of injury has been the cause of the affection.

XIII.—*Transverse* versus *Iliac Colotomy, with Notes of three Cases.* By Lawrie McGavin, F.R.C.S.Eng. *Read January* 12, 1906.

THE operations designed for the relief of conditions giving rise to chronic ulceration and permanent obstruction of the large bowel, or for the cure or relief of intestinal fistulæ, belong to that class of surgical procedure which, like those for œsophageal cancer, stenosis of the larynx, and extroversion of the bladder, leaves the surgeon and the patient no better alternative than a "Hobson's choice." Surgery, which in recent years has advanced by leaps and bounds, seems at present to be faced by a blank wall of unsurmountable proportions in the face of these conditions; and its march has been retarded by the feeling, so commonly expressed, that death itself is an alternative preferable to the after-condition of a patient who elects to undergo the operation of colotomy. Now, at first sight this may appear to be so, and for lack of serious consideration of the question many patients have been permitted to drag out a miserable existence unrelieved, while others have even been allowed to die racked with pain and poisoned by their own fæcal matter. The old saying that it is "better to bear those ills we have than to fly to others that we know not of" has perhaps been permitted too long to influence us with regard to an operation which should rather fall into the category of merciful alternatives than be branded, as I once heard it, and that by one of my professional brethren, as "the gateway of a living death, which makes a man a curse to himself and a nuisance to his friends."

Such an idea must be held, in the light of modern surgical knowledge, to be misleading and based on insufficient experience of the purposes of the operation and of its after-effects; and in this connection I cannot do better than direct attention to the remarks of the late Mr. Allingham,* who says: "Such remarks are positively wicked and absurd, and probably proceed from men who have rarely seen the operation performed, and who know nothing of the suffering which it saves and the relief which it gives. Views of this

* *Diseases of the Rectum*, chap. xxv, p. 357.

kind must have been handed down by tradition from professional ancestors who were as ignorant as the present holders of such opinions."

On the other hand, there is little doubt that in recent years the operation of colotomy has been resorted to with a readiness which is much to be regretted. Even at the present time one sees cases in which this operation has been performed where judicious dieting and careful purgation would have enabled these patients to end their days in comparative comfort. And here I may state a case in point.

A patient was recently admitted to the Hospital for Women under my care; she was thirty-five years of age, and had suffered for some years past from a tubular stricture of the rectum, involving the whole of the second part, the result of a tertiary lesion. I first saw her in the out-patient room, to which she was brought in a cab, extremely ill, with the foulest breath, a thickly furred tongue, intensely anæmic, and an abdomen distended and tender. She had suffered from constipation for two or three years, and on admission had passed no motion for more than a fortnight. On examining the abdomen the distended coils of intestine stood out clearly, peristalsis was active, and the whole length of the colon was easily traced, being crammed with masses of solid matter which could be moulded readily by the fingers through the abdominal wall. A rectal examination revealed a stricture commencing at the upper edge of the anal canal, which, *per vaginam*, could be felt to involve the rectum as above stated. The little finger could be passed into this tube as far as the last interphalangeal joint, further attempts at introduction causing considerable pain. This case certainly seemed to demand early colotomy, but I preferred to carry out first of all the treatment I have always adopted when time and the patient's condition have permitted it, and accordingly the colon was flooded with copious enemata, the patient being in the Trendelenburg position and the abdomen being thoroughly massaged at the same time. This resulted in the daily passage of enormous quantities of very foul disintegrated fæcal matter, and so marked was the result of the treatment that in a fortnight her condition had become almost normal. At the time of writing, five months since I first saw her, she has gained a stone in weight, her colour is healthy, her tongue clean, and her breath sweet. She has now returned to active employment, and by the help of hydragogues, nux vomica, the daily use of enemata, and the regulation of her

diet, she leads a healthy, active life, and declares herself perfectly comfortable. The stricture is in exactly the same condition as when I first saw her, and has never been dilated.

The indications for the performance of colotomy, clearly set forth in most text-books, may, I think, be summed up in very few words: when no other medical or surgical procedure is available for the relief of suffering or for the saving of life, the time has come, and not till then, for the bowel to be opened. That is to say that colotomy should be an operation, not of election, but of compulsion; at the same time, it should be done, like gastrostomy and gastro-jejunostomy, before the patient has become worn out by chronic pain, sleepless nights, and toxæmia; for the tardy performance of such operations is like snatching the bread from the lips of a starving man. But the question as to whether the time has actually come is one which has perhaps been too lightly considered; the disinclination to waste time in lavage, massage, dilatation, and other non-operative measures, in what often seems a hopeless case, is apt to lead to the performance of colotomy when such is not absolutely necessary, and this is more likely to happen when the constant increase in the number of those who are genuinely in need of and patiently awaiting operative treatment is so often a compelling factor in hospital practice. On the principle that "if a thing is worth doing, it is worth doing well," it should be the duty of every surgeon in charge of cases such as these to satisfy himself by every means in his power that the time has actually come when colotomy of some form is the only card left to play. Having done so, a question of importance remains to be discussed, viz. Which of these forms, presuming that there is any room for choice, is the most likely to offer the patient the least discomfort, the greatest command over the new anus, and the least unpleasantness to himself and his friends? The operation by the lumbar route, although it has even now its advocates, has not displaced the older one by the iliac. That this is so is not to be wondered at when the inconvenience of the wound from the patient's, and the greater difficulty of the operation from the surgeon's point of view, is considered. The difficulty of obtaining a useful spur, with which to guard the distal stoma of the bowel, is probably one of its greatest disadvantages; and that of finding the bowel in the case of obese subjects; the danger, usually slight, but in certain cases

very real, of causing damage to other structures; and the much more extensive nature of the wound, are points which combine to place lumbar colotomy in a sphere of usefulness inferior to that of the iliac operation. In only one point can it be said to have a distinct advantage over the latter, viz. in the almost complete immunity to prolapse of the bowel. This, however, seems to me to be almost a disadvantage at times, since only by a moderate degree of prolapse can a deficiency in the spur be compensated for in this operation.

That iliac or so-called inguinal colotomy should have replaced the methods of Callisen and Amussat is but natural in view of these objections, but here too disadvantages are none the less obvious. Thus the tendency to prolapse is very marked; indeed, in some patients it seems almost impossible to prevent, even by the repeated removal of the prolapsed bowel; the close proximity to the rectum, when this organ is extensively diseased, may at times render the meso-sigmoid so short that the bowel can only be brought into the wound by the exercise of considerable tension, with the result that the iliac region is depressed and a good spur is not formed. The yielding nature of the abdomen in this situation destroys the efficiency of a belt of any kind, thus rendering the condition of the patient, especially in the event of laxity of the bowels, one of great unpleasantness and discomfort; and in very thin patients in whom the iliac spine is prominent this may lead to the formation of a sore which will vie with a bedsore in its intractability to treatment. Should it be considered advisable to close the distal and bring out only the proximal end of the bowel, some difficulty is often experienced in determining the identity of the same; and in support of this I may mention that on one occasion I witnessed the occurrence of an accident, in which a leader of our profession in operative surgery had the misfortune to close the proximal end of the bowel by mistake, with disastrous results. Again, in this operation, as in the lumbar method, the material at our disposal is little adapted to the formation of any kind of sphincter, and lastly, but by no means of least moment, the position of the wound renders it very difficult to accommodate any kind of receptacle to the part when the patient desires to empty the bowel.

The contention that colotomy in this region gives greater solidity to the fæces may be to some extent true; but it is not always so, nor is this matter one of such great importance as has been stated, the regulation of the diet having so large an

influence on the consistence of the motions. Thus it will be seen that colotomy, whether it be performed by the lumbar or by the iliac route, leaves much to be desired in several directions. Why is it, then, if these points are true, as I believe them to be, that the third form of the operation, that dealing with the transverse colon, has been comparatively neglected?

Firstly, the idea, old as it is, that there is some danger, in short-circuiting the large bowel so high up, of producing malnutrition is still credited in some quarters; secondly, an impression also prevails that the fæces in this portion of the bowel must necessarily remain fluid, and therefore are difficult to control; thirdly, there is a belief that prolapse is more likely to occur here; and, fourthly, the objection has been put forward that the position of the new anus in the subcostal space is an unpleasant one for the patient.

Now, all these objections may be frankly denied, and were the operation of transverse colotomy to be accorded a more extended trial, I believe it would be found to compare most favourably with the present iliac operation. That no such trial has been given it is clear from the almost complete absence of the subject from the best known text-books. Of the two greatest British authorities on operative surgery, one only makes mention of the operation, saying that "this is the most rarely performed of all the colotomies."

With regard to three of the so-called objections I have mentioned, viz. those referring to malnutrition, prolapse, and fluidity, I may be pardoned for quoting three references to well-known authorities. Discussing the question of possible malnutrition after cæcostomy Messrs. Goodsall and Miles * say: "This contention has not been confirmed in our experience. There is at the present time a patient (a male) under our care, upon whom the operation was performed nine years ago. During this long interval there has been a most marked increase in weight (twenty-five pounds) and moreover the patient has been enabled to lead a far more active life than he was capable of doing before the operation of cæcostomy was performed. In another case, a female, also under observation, the operation was performed six years ago, since which date there has been marked improvement in her general health, and her weight has increased by ten pounds."

If such results are to be obtained in the case of cæcostomy, there need be little fear of malnutrition when the stoma is made

* *Diseases of the Anus and Rectum*, Part II, p. 206.

at a level so much lower in the colon, as is the case in transverse colotomy. That this is so is shown by my own cases as reported below, the second of which is especially of interest in this, that although the patient was suffering from chronic dysenteric ulceration of the rectum and sigmoid, he yet increased markedly in weight from the time the colotomy was performed. And it is hardly reasonable to suppose that the loss of two feet and a half, or indeed rather less, of the *large bowel*, of which the duties are chiefly those of lubrication and excretion and only secondarily of absorption, should vitally affect the nutrition of the body, when we know by experience that much larger sections of the *small intestine* have been removed without the occurrence of any very grave symptoms in this respect.

Writing on the subject of transverse colotomy, Mr. Allingham* said: "Prolapse might happen, but I have not yet seen it, and it would scarcely be so likely to occur as in other places, for the transverse colon is in a way fixed at its hepatic and splenic flexures, and would thus tend greatly to prevent any prolapse of the gut through the transverse opening." The three chief causes of prolapse are, the influence of gravity, the absence of a good sphincter, and the presence of constipation. Now, in transverse colotomy gravity has no influence, and a sphincter is more easily made, and constipation is more easily avoided than in iliac colotomy.

On the subject of fluidity of the fæces in cæcostomy, the first mentioned writers † say: "This, we do not deny, occurs during the first four or five weeks after the anus has been established, but our experience of twenty-seven cases of the operation has shown that after that period, in the majority of those cases, the fæces become firm and are voided in the semi-solid or even solid consistence. We have observed, too, that diet has much to do with the frequency of the actions of the bowels." My own experience, slight, it is true, in comparison with the above, certainly leads me to the same conclusion. The last of the objections, that referring to the unpleasantness of the position of the new anus in transverse colotomy, seems to me to bear criticism no better than the others. The difference in position by measurement from the iliac site to that proposed is on the average four inches higher on the abdomen, and three inches nearer the median line; this is very little, and it must be remembered

* *Op. sup. cit.*, chap. xxx, p. 432.
† *Op. sup. cit.*, Part II, p. 205.

that the contents of the transverse colon are hardly so offensive as those of the sigmoid, where bacterial action has produced more profound changes. The subcostal space, even in the stoutest patients, rendered firm as it is by the proximity of the costal cartilages on either side, by the support afforded by the liver, and by the existence of the thick rectus muscle, here reinforced by the lineæ transversæ, has a decided advantage over the iliac region; because, firstly, the resistance provided in this way permits of the much more accurate and comfortable fitting of a belt and plug; secondly, if the wound be made, as it should be, through the rectus muscle instead of through the linea alba, a fairly efficient sphincter is obtainable; thirdly, a very important matter, the force of gravity being here almost inactive, prolapse, as already mentioned, is little likely to occur; and lastly, the patient by simply bending slightly is able to evacuate the bowel into a receptacle with much greater ease and cleanliness than in the case of the iliac operation. As regards mortality, there is practically no difference in the two methods; in ease of performance the transverse method has the advantage that the bowel can always be brought well out of the wound, a matter which is not always easy in stout patients with a short meso-sigmoid.

There remains another point in which transverse has a distinct advantage over iliac colotomy. Should it at any subsequent time become possible to reconstitute the large bowel, as, for instance, after the successful closure or spontaneous healing of a recto-vaginal, recto-vesical, or other fistula, such an operation is of comparative simplicity in the transverse colon, where the binding down, such as occurs at times in the iliac fossa as the result of colotomy here, and the presence of the bony prominence of the iliac spine, and of the iliac vessels, has not to be reckoned with.

Although I have seen patients in the past four years who might have been considered by many surgeons to be suitable subjects for colotomy, I have only been obliged to operate upon seven. Four of these were done by the iliac route and three were transverse colotomies. Of the former little need be said; they were all done for inoperable carcinoma of the rectum, two being for the relief of pain, and two for threatening obstruction. The first lived six months after operation; the second died shortly after operation as the result of complete absence of plastic adhesions, permitting of the invasion of the peritoneum by fæcal matter

on the bowel being opened on the fifth day; this I attribute to the presence of extensive cancerous deposits on the peritoneum, with resulting ascites, a condition I have more than once observed to be adverse to the formation of good adhesions. The third case lived nearly a year and the fourth nine months from the date of operation. All of these patients who survived expressed themselves as being greatly relieved, and were able to get about well after their operations, but all confessed to some difficulty in controlling their motions in spite of the belt and plug, and all of them exhibited a considerable degree of prolapse.

But it is to the three cases of transverse colotomy that I wish to draw attention: they are as follows:

Case 1.—E. P., a girl æt. 18, was transferred to my care in the Hospital for Women in July, 1901. Eighteen months previously she had undergone an operation for the removal of both uterine appendages for tuberculous salpingitis. Fæcal matter had appeared on the dressings on the eighth day, and from that time all her motions had been passed by the wound. I opened the abdomen, hoping to be able to short-circuit the bowel and so exclude the fistula, but finding the pelvis occupied by an indistinguishable mass of matted intestine, the sigmoid being completely buried, I brought the transverse colon out in the subcostal space by Maydl's method, washed out the abdomen, the walls of which, with the intestines, I found studded extensively with tubercles, and closed the wound, hoping to be able at some later date, should the fistula close, to remake the bowel. The colotomy, which was completed on the fifth day, answered admirably; the motions soon became of the consistence usual in the sigmoid, no prolapse took place, and the patient began rapidly to put on flesh, the fistula being soon reduced to a mere sinus. About three months later, the patient being then up and convalescent, acute intestinal obstruction unfortunately occurred as the result of an adhesion band consequent on her chronic peritonitis, and, her parents refusing any further operation, she died.

At the autopsy the tubercles had entirely disappeared with the exception of one or two on the parietal peritoneum. The colotomy wound was sound, the adhesions showing no signs of stretching. Two fistulæ were present, one recto-sigmoid, and one (unsuspected) recto-cæcal. The band which caused her death was quite unconnected with the

colotomy, and stretched from the anterior abdominal wall to the psoas muscle, encircling the middle portion of the jejunum.

Case 2.—F. D., æt. 25, a seaman, was transferred to my care in the Seamen's Hospital, Royal Albert Dock, in November, 1902, for chronic dysenteric ulceration of the rectum, of two years' history. All medical means having failed to effect a cure, I proposed transverse colotomy, with the object of affording rest to the descending colon and rectum. The area involved was very extensive, reaching up into the sigmoid and giving the mucous surface of the bowel the appearance of raw beef covered with ragged ulcers of the size of a threepenny-piece. The man was intensely anæmic, and suffering agony on the passage of motions over this surface and on the administration of injections. Transverse colotomy was performed by the same method as in the first case; the result was very satisfactory; he gained a stone in weight, controlled his motions with ease at the end of six weeks, experienced no unpleasantness from the position of the new anus, and although there was at one time the slightest suspicion of prolapse, it was temporary, caused him no trouble, and eventually disappeared. Six months later I saw this patient again; he had developed phthisis with slight hæmoptysis, but his weight was maintained and he expressed himself as being comfortable and as having no trouble with the colotomy wound. The rectal condition was better, but by no means cured, but the pain for which the operation had been done had left him.

Case 3.—The last case is that of a woman, æt. 45, who was transferred to my care in the Hospital for Women in September, 1904, suffering from a fæcal fistula of a year's standing, following the removal of a very adherent ovarian tumour. About three months after this operation she developed a red, hot, tender swelling in the abdomen, pointing midway between the umbilicus and the left iliac spine. This had apparently been opened under the impression that it was a pelvic abscess, when gas and fæcal matter escaped. Since that time a large fæcal fistula had existed, although fæces were also passed *per rectum*. The abdomen was opened, and a condition almost identical with that described in the first case (with the exception of the tuberculous lesions) was found, the sigmoid being buried. The transverse colon was accordingly

brought out. This patient has since that time been gradually improving. Her condition is one of comfort; she controls her motions and voids them with ease, has no signs of prolapse, and the fistula is now represented by a very fine sinus through which nothing passes. As motion was passing in fair quantity *per rectum* prior to the performance of colotomy, I am in hopes that it may yet be possible to re-establish the continuity of the bowel at no very distant date. She tells me she suffers no inconvenience whatever from the presence of the anus in the subcostal space.

These cases are, I think, a satisfactory answer to the objections referred to at the commencement of this paper, as being made by those who entertain nothing but disgust for the operation of colotomy; and, indeed, so struck have I been with the results obtained, especially in cases of the prognosis of which I was myself extremely sceptical, that I am compelled to think that the operation of transverse colotomy as a routine practice promises more to surgeons and patients than the present operation by the iliac route has as yet been able to perform. That the former operation may still be improved upon is, I think, possible, and the idea had occurred to me to endeavour to form a permanent sphincter to the stoma by dividing the bowel, closing the distal end, and drawing the proximal through a broad band of fibres taken from the rectus muscle in a plane parallel to the surface of the abdomen, and suturing it there, but as yet I have not had an opportunity of putting this idea into practice.

XIV.—*Further Cases of Torsion of the Omentum.* By H. Irving Pinches, M.A., M.B., B.C. (Cantab.), and Edred M. Corner, M.B., F.R.C.S., etc. *Read January* 12, 1905.

In this communication two new cases are brought before the Society; in one torsion of the omentum was seen; in the other there was every indication of its presence, though, owing to the difficulties at the operation, its actual occurrence was not seen. We have briefly reproduced two other cases which have been published since we communicated our paper to the Royal Medical and Chirurgical Society early in 1905.

The first example of torsion of the omentum was described by Oberst in the year 1882, since when only 55 other cases have been recorded.* Clinically, torsion of the omentum can be divided into three main classes:

(1) *Abdominal.*—In this type there is no hernia present, the torsion being intra-abdominal.

(2) *Hernial.*—The torsion occurs solely within the hernial sac.

(3) *Hernial and abdominal.*—The torsion is not limited to the hernial sac, but extends into the abdomen. This last variety is by far the most common.

The diagnoses usually arrived at are: in the first or abdominal class, appendicitis; in the second or hernial class, strangulated inguinal hernia; in the third class, most frequently strangulated inguinal hernia, and next appendicitis.

Clinical etiology.†—Torsion of the omentum occurs about twice as frequently in males as in females, taking place about middle life. With the exception of the purely abdominal cases, a hernia is always present. In 70·2 per cent. the hernia has been a right inguinal one. In no instance has torsion occurred in connection with a femoral hernia, and only once in an umbilical. The hernia is usually of long standing, 67 per cent. having been present from ten to thirty years.

In only a very few instances is there any statement made concerning a previous illness which is at all referable to the omental torsion; although the twisting is a slow process. The

* *St. Thomas's Hospital Reports*, 1904, pp. 435-475.

† *Amer. Journ. of the Med. Sciences*, 1905, vol. cxxx, pp. 314-329.

clinical onset is as a rule sudden. Pain is the most constant of all the symptoms, usually being said to be most intense over the situation of the hernia (when it is present) and over the lower abdomen. Vomiting is not at all a constant symptom. The bowels are usually open; in a few instances absolute inaction was present. The temperature and pulse-rate are frequently slightly raised.

Clinical signs.—In practically all instances a tumour can

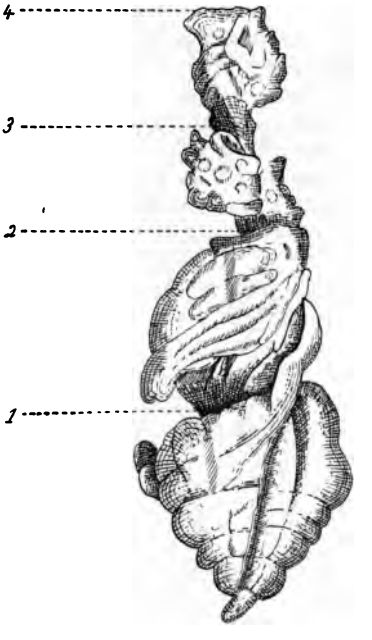

FIG. 8.—Portion of omentum removed. 1, 2, and 3 mark the three sites of torsion; 4, cut end of omentum.

be felt. In the abdominal class the tumour is situated in the abdomen; in the hernial class, in the inguinal region; in the hernial and abdominal class the situation varies, the tumour being felt most frequently both in the inguinal region and in the abdomen, the two parts being continuous with each other; sometimes the tumour is felt only in one of these situations.

The following is a brief summary of the conditions which should lead to a suspicion of the existence of torsion of the omentum. The subject is usually a man of middle age with

an inguinal hernia of some years' standing which has recently become troublesome and has now given rise to certain symptoms which can be summed up as those of subacute intestinal obstruction. Vomiting may be absent and both fæces and flatus may be passed. On examination, the hernia will most probably appear to be painful and irreducible, incarcerated or strangulated. Usually, a tumour can be felt both in the scrotum and in the abdomen; they may be continuous.

Case 1.—For permission to publish the following case we are indebted to Mr. L. A. Dunn, who operated upon the patient in St. Thomas's Home.

H. M., male, æt. 48. A right inguinal hernia had been present for thirty-seven years; he had worn a truss for thirty-three years. The tumour was about the size of a fives ball, in the right side of the scrotum; it was easily reduced and gave rise to no pain. Whenever the truss was removed the hernia came down, reaching the upper part of the scrotum. As a rule the hernia was down every morning when the patient got up; he reduced it and then put on the truss. It never caused any pain.

On September 11, 1905, the patient felt slight pain in the inguinal region he took the truss off and lay down; the hernia was down and he was unable to replace it. When the truss was put on the pain increased. The patient went to bed and applied ice, but the tumour increased in size and the pain became more severe. A doctor who saw him was unable to reduce the hernia. No vomiting, bowels open two days after onset. On the third day the temperature was 99° F., pulse 102, respiration 20. On examination there was a tumour about the size of a hen's egg in the inguinal canal; it was extremely tender, soft and doughy to the touch. It was irreducible and conveyed no appreciable impulse on coughing. When standing up the tumour entered the scrotum. The lower part of the abdomen and the inguinal region were extremely tender, and the skin was reddened over this area. Over the tumour the tissues felt thickened, as if there was some inflammatory lesion present. Diagnosis: Torsion of the omentum. Operation: An incision was made over and in the direction of the inguinal canal. It was noted that the tissues were in a subacute inflammatory condition; the hernial sac was thickened and contained a small quantity of odourless fluid; in the sac was a small mass of friable

omentum, having a dark and congested appearance resembling that seen in a strangulated epiplocele; the omentum was not nipped at the internal ring and could easily be pulled down. The stalk was ligatured at a healthy part and the tumour removed. On examining the portion removed, it was seen that the omentum had been twisted upon itself, three half-turns being present. The highest twist was situated within the inguinal canal, just below the internal ring. It was this twisting which had given rise to the inflammatory appearance of the omentum.

This is a typical example of what is the most frequent class of torsion of the omentum.

Case 2.—Operated on in St. Thomas's Hospital, September, 1905.

Male, æt. 45, a left inguinal hernia was present, which had only been noticed a few days. A small, tender, hard, rounded lump of omentum was felt outside the external abdominal ring. Although it had only been tender a few days, it had undoubtedly been present far longer, but owing to the patient's stoutness, was not noticed. The hernia was irreducible. There had been no injury to the inguinal region. Diagnosis: Left direct inguinal epiplocele. Operation: A direct hernia was found, which, owing to the large quantity of subperitoneal fat, was not easily defined. The sac was difficult to identify, not only from this cause, but also because the omentum was adherent within. The omentum was about the size of a walnut, and had a stalk. It contained a hæmorrhagic cyst. It was irreducible, but not strangulated; there had never been any injury, and though a twist of the pedicle may have been overlooked in the profusion of fat and adhesions, there was every physical and symptomatic reason for its presence. It would explain the hæmorrhagic cyst, the inflammation or epiploitis, the adhesions to the sac, the pain, etc., of which the patient complained.

The hernia must have been present a great deal longer than the patient knew in order for the omental "ball"* and the stalk to be formed. This is the only possible example of torsion of the omentum in a direct inguinal hernia.

As two cases have been recorded since we published our long papers on this subject, we briefly reproduce them.

* "Torsion of the Omentum," *Med.-Chir. Trans.*, 1905.

CASE 1.—Reported by Dr. Cullen at a meeting of the Johns Hopkins Hospital Medical Society, April, 1905.*

Male, æt. 47. Onset of illness with discomfort in region of stomach; on the following day pain over the appendix. When seen about three days later all abdominal rigidity had disappeared; there was, however, a temperature of 101·5° and a pulse of 100. Diagnosis: Appendicitis. Operation: The appendix, which was slightly thickened and adherent, was removed. On the right side a large area of induration was found, extending half way between the anterior superior spine and the ribs. This indurated mass was entirely separated from the omentum and was attached near the junction of the ascending and transverse colon; it had a pedicle 1 cm. in breadth which contained two small blood-vessels. The mass was twisted upon itself several times, and was becoming gangrenous. After removal the mass was found to be 14 cm. long and 12 cm. in breadth; it consisted of omentum. This is the only case recorded of torsion of an accessory omentum. Recovery uneventful.

CASE 2. — Recorded by Dr. Stewart in the *Annals of Surgery*, October, 1905, pp. 624, 625.

The patient was a man æt. 34, who had had a right reducible inguinal hernia for fifteen years. Three months ago he began to suffer from indigestion. He was admitted to hospital for an attack of abdominal pain which was more severe than the others. There was both pain and tenderness to the right of the umbilicus. The hernia sac was empty. Temperature normal, pulse 90; no sickness; bowels open the previous day. A diagnosis of acute appendicitis was made. Operation thirty hours after the onset. The appendix was found to be normal. The whole omentum was twisted upon itself three times just below the transverse colon. It was removed. Recovery.

It is noteworthy in this case, the second recorded by Dr. Stewart, that there were never any symptoms referable to the hernia, though the very frequent presence of a hernia sac in these cases makes it certain that when present it has an important share in the production of the twists.

These cases bring the number of known cases of torsion of the omentum to fifty-seven.

* *Johns Hopkins Hospital Bulletin*, Dec., 1905, p. 801.

XV.—*A Review of* 59 *cases of Cancer of the Stomach treated by Operation.*—By B. G. A. Moynihan, M.S., F.R.C.S. *Read February* 9, 1906.

DURING the last few years (since my first case on August 23, 1897, up to July 1, 1905) I have operated upon 59 cases of cancer of the stomach. The operations practised have been as follows:

	Cases	Deaths
Gastro-enterostomy	35	5
Anterior (all with Murphy's button)	7	2
Posterior (all with suture)	28	3
Gastrectomy	10	3
(Complete)	1	1
(Partial)	7	1
(Partial with resection of transverse colon)	2	1
Gastrostomy for carcinoma at the cardiac end of the stomach	5	0
Jejunostomy	3	0
Exploratory laparotomy (operation not necessary or not possible)	6	1

During the same period I have seen eleven patients suffering from cancer of the stomach in so advanced a stage that I have advised against operation. One of these patients was operated upon elsewhere, and died six hours after gastro-enterostomy had been performed; of the remaining ten, nine lived for periods varying from three weeks to fourteen weeks, in one no further history was obtained.

I propose to discuss the cases in the order already given.

(1) Gastro-Enterostomy. Thirty-five Cases, Five Deaths.

In the earlier cases I used the Murphy button and performed the anterior operation. There were seven cases and two deaths, one from shock and exhaustion in a very enfeebled and wasted patient, one from continued vomiting and exhaustion.

In the later cases I have performed the posterior operation, by simple suture, in the manner I have described in detail in

my work on *Abdominal Operations*. There were twenty-eight cases with three deaths, one from pneumonia, one from shock or exhaustion, and one from septic peritonitis.

The value of the operation of gastro-enterostomy in malignant disease of the stomach has been variously estimated by surgeons. Recently a well-known London surgeon pronounced unhesitatingly against it in all cases; other surgeons are accustomed to practise it in all cases in which irremovable malignant disease is encountered. It has seemed to me that the indication for the operation is perfectly clear; it should be performed when obstruction to the food is caused by, or is likely to be caused by the increase of, an irremovable growth at the pylorus or in the body of the stomach near the pylorus. If no obstruction is caused, gastro-enterostomy is not indicated, and will not give if performed a degree of relief commensurate with the risks of the operation, though some temporary improvement may be noticed. If there is obstruction due to a growth which can be removed, gastro-enterostomy alone should not be performed unless the condition of the patient is such that the more serious operation of partial gastrectomy is not permissible. In such circumstances gastro-enterostomy may be performed, and two or three weeks later, when the patient's condition may be much improved, the removal of the growth can be safely undertaken. A growth is considered irremovable when it is adherent over a large area to the pancreas (the result of injury to which is most serious) or when extensive adhesions, the presence of many enlarged fixed glands, or secondary deposits in the liver or parietal peritoneum or elsewhere, make its complete eradication quite impossible. The extent of the growth in the stomach only, and the enlargement of the glands along the curvature, are negligible factors so far as the question of removal is concerned, for both are conditions surmountable by the operation which I now adopt.

A tumour growing on the lesser curvature well away from the pylorus may by its increase in size cause obstruction to the food. Gastro-enterostomy in such cases gives some measure of relief, though by no means so much as when the obstruction is due to an invasion of the pylorus.

The contrary to the rule mentioned is also in need of emphasis: it is that if obstruction is not caused, or is not likely to be caused in its extension, by the growth, the operation of gastro-enterostomy should not be performed. For the absence of obstruction implies that there is a free passage

through the stomach to the duodenum; the making of a new opening is therefore clearly not necessary.

Duration of life after gastro-enterostomy.—I have not been able to trace the final stages in the history of all my cases. Of the thirty patients who survived operation, twenty have been traced to the time of their death; six are alive and well; of four nothing is known. The earliest death among these occurred in the fourteenth week after operation, the latest two years and four months after operation. The length of life in the series is as follows: fourteen weeks, fifteen weeks, eighteen weeks, five months, five and a half months, six months, one between six and seven months, two between seven and eight months, two between eight and nine months, three between nine and twelve months, two between twelve and eighteen months, two between eighteen months and two years, two over two years. The patient who survived longest was a woman on whom I operated on June 13, 1902, with Dr. Norman Porritt, of Huddersfield. Writing to me on October 27, 1904, Dr. Porritt said:

"You found pyloric enlargement and enlarged glands, and at the operation expressed the opinion that the case was one of malignant disease. The immediate recovery from the operation was very satisfactory, but convalescence was slow, and œdema of the legs coming on seemed to confirm the correctness of your opinion as to the nature of the case. But the patient went to Blackpool and came back a different woman, and has been in first-class health until about five or six months ago. The leg œdema quite disappeared. About five or six months since she began to lose flesh and condition, a tumour appeared in the middle of the lower part of the epigastrium, and the patient went downhill and died, from malignant disease of the stomach, two days ago."

Of the six patients who are still alive, one was operated upon thirteen months ago and five within the last twelve months.

A question in reference to these patients that has to receive an answer is this: Is it worth the patient's while to have the operation done? I should answer, without hesitation, yes. For in all such cases death is imminent, and the remnant of life would be intolerable from constant vomiting, gastric intolerance, and the complete inability to take or enjoy food in satisfying quantities. By the operation of gastro-enterostomy life is undoubtedly prolonged, and, what is of far greater consequence, the last weeks or months of life

are rendered tolerable. Food can be taken in fair and sufficient quantity, and can be enjoyed; there is no stasis of food, and there is no vomiting. Death occurs from gradual exhaustion; and ascites, with or without jaundice, may be a feature of the terminal condition.

(2) Gastrectomy. Ten Cases, Three Deaths.

In the nine cases in which partial gastrectomy was done the growth was either "pyloric" or "prepyloric" in all. The tumour was largest at or near the pylorus, and thence had spread to the curvatures—to the lesser curvature in seven, to the greater curvature in two. In the seven former the lesser curvature was palpably affected in a considerable part of its extent, and the coronary glands were also enlarged; in the two latter the growth had spread very much more extensively along the greater curvatures, and had puckered up the transverse mesocolon and invaded the transverse colon, or caused its stenosis by kinking. In all the cases partial gastrectomy was performed, in the first two by the method I described before the Clinical Society of London in November, 1901, in the remaining seven by the slight, but important, modification of it suggested by Hartmann. Of the nine cases, two died within a week of the operation, one in a few hours, one in three and a half days. Of the remaining seven, one has lived four and a half years, and is quite well and free from recurrence, one died in eleven months with ascites, one in fourteen months with secondary growths in the liver and jaundice and ascites, and four are still alive, the operation having been performed at dates distant between two and a half years and five months.

I have been perhaps rather conservative in my application of the operation of partial gastrectomy, and I am strongly disposed to think that if some of my earlier cases were to do again I should perform this operation in preference to gastro-enterostomy. With the method of operation described in my work on *Abdominal Operations* there is but little loss of blood, there is no undue exposure of viscera, there is no soiling of the peritoneum, and the risks are accordingly much reduced from what they were even five years ago. We should, therefore, be emboldened to a free removal of cancer of the stomach in all cases where secondary deposits are not obvious. My cases are too few to afford a profitable comparison with those in which gastro-enterostomy has been

performed, in so far as concerns the duration of life, but there is clearly a very decided gain in length of days after the removal of the growth. Indeed, the question may well be raised as to whether in selected cases the operation of gastrectomy is not more satisfactory as a palliative operation than gastro-enterostomy, for its risk is very slightly greater, and by it the patient is rid of a growth which is giving rise to a continuous lymphatic infection. By removal of the growth the dose, so to speak, of cancer is temporarily lessened.

In one patient complete gastrectomy was performed with a fatal result. I have elsewhere described this case in detail, and need not do more now than express my opinion that the operation is one which has a legitimate place in surgery, and is not merely a brilliant piece of surgical gymnastics. There is no doubt whatever about the fact that the whole of the stomach may be involved by a growth which has given rise to no secondary deposits—a growth which can, therefore, be entirely removed. In my paper in the *British Medical Journal*, 1903, vol. ii, p. 1458, all the recorded cases are collected.

(3) Gastrostomy. Five Cases, no Deaths.

In all cases the growth was at or near the cardiac orifice of the stomach and was causing stenosis. It is possible that in three of these, at least, the growth was primarily œsophageal, the cardia being affected by extension downwards of the disease. The operation was performed by Senn's method in four, by Frank's method in one. The patients lived five months, five and a half months, seven months, eight months, and seventeen months after operation.

(4) Jejunostomy. Three Cases, no Deaths.

The method adopted was a modification of Witzel's described by me in the *British Medical Journal*, 1902, vol. i, p. 1599. The patients lived four and a half weeks, eight weeks, and eleven weeks after operation.

In all these cases the stomach was so extensively involved that gastro-enterostomy was impossible, and the presence of secondary nodules in the liver or in the peritoneum put away any thought of excision.

The prolongation of life for eleven weeks in one case was a matter of considerable moment, the man being able to settle some affairs of the highest importance with his son, who, at

the time of the operation, was in South Africa. But for the operation the patient could hardly have lived a fortnight.

(5) Exploratory Laparotomy. Six Cases, One Death.

The opinion is, I fear, too often expressed that an exploratory operation in suspected cancer of the stomach "to confirm the diagnosis" is almost entirely devoid of risk. This is far from being the case. In order to determine with accuracy the extent of the growth, and to know with certainty the possibility or otherwise of its removal, an incision three or four inches in length is necessary, and the hand must be passed within the abdomen. People who have obvious cancer of the stomach are often enfeebled, advanced in years, and possessed of but little reserve of strength. An exploratory operation is, therefore, in itself, a matter of some gravity, and must not be heedlessly performed.

The incision which admits one finger only is enough for the very late or for the very early cases, but there are many cases lying between these extremes where a close scrutiny of the parts is necessary before an accurate decision for or against operation is possible.

Duration of life after exploratory operations.—The exploratory operation has had, in two cases, a very marked and unexpected result. The symptoms of pain and distaste for food or inability to take food disappeared almost entirely for periods of two months and two and a half months respectively. The patients expressed themselves as feeling much relieved by the operation, and were able to take food better. The longest duration of life after exploration was just under seven months.

In addition to the cases already discussed I have operated three times for growths (in two at the pylorus, in one at the centre of the stomach) which I considered to be malignant, but which have been proved by their subsequent course to be simple in character. One of the cases was operated upon in June, 1900 (a patient sent to me by Dr. Clarke, of Doncaster), and the other in January, 1901 (a patient sent by Dr. La Touche, of Ossett). A case of hour-glass stomach due to supposed malignant growth in the body of the organ was operated upon in June, 1901 (sent to me by Dr. Crawford Watson, of Harrogate, subsequently under the care of Dr. Selkirk of Boston Spa). These are three cases, therefore, in which simple inflammatory masses were mistaken for can-

cerous growths. In one case I have made the opposite mistake, a malignant growth being looked upon as a simple one. This patient lived fourteen months after operation and died with ascites. A *post-mortem* examination was made, and a large mass of cancer at the pylorus, with many secondary masses in the liver, discovered.

A study of this series of cases has elicited several interesting facts.

(*a*) With regard, first, to the position of the growth. In all the cases of gastrostomy for disease of the stomach, five in number, the growth was at the cardiac end, and had spread thence to a varying extent towards the body of the stomach, chiefly along the lesser curvature, where the glands also were implicated.

In one case of partial gastrectomy the growth was in the body of the stomach and had caused the organ to be of an hour-glass form.

In all the remaining cases of partial gastrectomy, and in all the cases of gastro-enterostomy, the growth was situated within 3 inches of the pylorus. Two types of growth were here recognised which may be called "pyloric" and "pre-pyloric." In the pyloric growths the disease had begun in the pylorus (or at least within a very short distance of it) and had early caused a constriction at that part. The tumour as a rule was comparatively small, was largest at the pylorus, and gradually tailed off along the curvatures, chiefly along the lesser curvature.

The growth along the lesser curvature in two of the cases extended almost to the œsophagus. In all the cases there was enlargement of the glands; in the earlier records there is no exact statement as to their position, "enlarged glands" only being written; in the later records it is said that the glands were chiefly along the lesser curvature.

In two cases the extension of the growth, which involved both curvatures, had affected the greater to a more marked degree, and as a result the transverse colon and its mesentery were involved in the growth. Such involvement is not specially serious from the point of view of removal of the growth, for a resection of the colon can be performed at the same time as the removal of the stomach.

The "pre-pyloric" form of growth began almost always at the same point, on the lesser curvature about 1½ inch to 2½ inches from the pylorus. The growth seems to spread from here along the curvature in both directions, but chiefly

towards the pylorus, drifting along into the lymphatic stream. It was, therefore, some little time before the pylorus itself was involved, or before there was such increase in the size of the growth as to determine obstruction. This form of growth presented in almost all cases the same features. Its origin, as indicated by the thickest part of it, was at the lesser curvature; from here the growth spread along the curvature, and, to a less extent, down both anterior and posterior walls. Two wings of growth, as it were, were hinged on to a body which was longer than either, thicker in the middle and tapering towards each end. The centre of the growth was often deeply puckered, white, and "gritty"; the rest of it was smooth, but intensely hard.

The symptoms in the two forms of growth, "pyloric" and "pre-pyloric," differ to a degree which should make their recognition before operation a matter of little or no difficulty. In the pyloric form the symptoms from the outset are of an obstructive character: there is stasis of food, inability to take solids, and vomiting in quantities which increase with the increasing capacity of the stomach. In these cases the stomach is obviously dilated, and waves of peristalsis are easily seen or easily elicited by slight inflation of the stomach. A growth placed as these are need not be of large size to cause the most marked symptoms. It does not require a large mass to block the pylorus effectively.

In the "pre-pyloric" form the symptoms are not obstructive in the earlier stages; it is only when the pylorus is invaded, or the large size of the growth blocks the narrow pyloric antrum, that there is any impediment to the onward passage of food. Before this time the symptoms are loss of appetite, intolerance of solid food, uneasiness after meals, occasional vomiting of a turbid watery fluid in small quantities, and loss of weight. These symptoms are all mentioned in the history of my cases, though any one or more or even all of them may be absent in any individual patient. In two of the cases a diagnosis of "anæmia" had suggested the treatment that was adopted for two and three months. An anæmia without obvious cause in a patient æt. 50 or thereabouts should create a suspicion as to its dependence upon malignant disease somewhere within the abdomen.

In the cases where an exploratory operation only was performed the growth was, with one exception, most marked along the curvatures—on the lesser curvature in three, on the greater in two, in one the greater part of the stomach was

involved. In all the mass was large, very much larger than had been supposed before the abdomen was opened. The reason in these cases for not performing gastro-enterostomy was that no obstruction was caused and therefore such an operation could not afford much relief; the reasons against the performance of partial gastrectomy were that there were many enlarged glands, which were irremovable, or secondary deposits in the liver, or intimate adhesion to the pancreas.

(*b*) With regard to the previous history of gastric ulcer. In the last twenty-two cases of gastro-enterostomy by simple suture, a close inquiry was made into details of previous history in respect of gastric ulcer; of the earlier cases I have very few historic details; the interest of the notes then taken lies chiefly in the details of technique. The result, I find, is that of the twenty-two patients sixteen either gave a history of an illness which had been called "ulcerated stomach" or "gastric ulcer" by the medical man who then attended, or they spoke of having "always had indigestion." In two cases a history of chronic indigestion extending over more than twenty-five years was given. In one of these an operation had been performed eighteen years before by Mr. McGill for a perigastric abscess; from the condition disclosed by the operation I performed, it was quite clear that there had been a subacute perforation of an ulcer near the pylorus and on the lesser curvature.

The evidence, then, in this last series of cases goes to show that in sixteen out of the twenty-two patients (equivalent to 72·1 per cent.) there had been gastric ulcer many years before. The shortest interval between the "attack" of gastric ulcer and the onset of the symptoms which led to my seeing the patient for a condition which proved malignant was three years, the longest interval was twenty-six years.

On the other hand, there were two patients who gave a history of less than three months' duration; in both malignant disease, already far advanced, was discovered. Up to the time of the somewhat brusque onset of symptoms there had never been any suspicion or hint of abdominal disease. One of these cases offered an undoubted instance of ulcus carcinomatosum, one edge of an ulcer being affected by a large mass of exuberant carcinomatous growth.

With regard to the existence of gastric ulcer as a precursor of malignant disease in the remaining cases, my records show that in nine cases of gastrectomy there were six with such a history, in three cases of jejunostomy one case, in six cases of

exploration three cases, and in five cases of gastrostomy one case.

Thus in the whole series of cases a previous history of gastric ulcer was noted as follows:

Of gastro-enterostomy there were twenty-two cases, with sixteen giving such a history; of gastrectomy there were nine cases, with six giving such a history; of jejunostomy there were three cases, with one giving such a history; of gastrostomy there were five cases, with one giving such a history.

Inquiry was either not made in the earliest cases, or no mention is recorded of any such history being elicited.

I have elsewhere (*Practitioner*, September, 1904), dealt with the subject of "ulcus carcinomatosum" in detail.

The sequence of gastric ulcer and carcinoma so far as clinical evidence can support it, seems to be definitely established in more than half the total number of cases that come to surgical treatment. Analogy is perhaps the worst argument in surgery, but one cannot refrain from citing the similar circumstances occurring in the case of the tongue. Carcinoma rarely develops in a tongue which is otherwise healthy. In almost every instance cancer is only a local exaggeration of, or a later change in, an unhealthy condition of things distributed over other parts, or over the whole, of the tongue. Evidence of present chronic superficial glossitis, of former ulceration or "cracking" of the tongue, are frequent, if not constant.

Evidence of a like kind to this is difficult to obtain in the case of the stomach; by the time the specimen is submitted to examination after removal by operation, or after death, the growth is so extensive as to obliterate or at the least to hide, the scars of older lesions. Nevertheless, a not inconsiderable number of specimens have been obtained showing a chronic ulcer which at its edge is undergoing a cancerous transformation, the cancer being clearly of later date than the ulcer. This condition of "ulcus carcinomatosum," the grafting of cancer upon ulcer, is recognisable pathologically in but a small proportion of cases; the clinical evidence suggests that it is not unlikely that it is the most common form of cancer of the stomach. This is assuming, of course, that the term "ulcus carcinomatosum" is held to include all cases in which chronic inflammatory conditions are the local precursors and excitants of carcinomatous changes.

It is interesting to note that the two conditions ulcer and cancer affect the various portions of the stomach with

approximately the same frequency. The "ulcer-bearing area" of the stomach is the pylorus, with the pyloric antrum, and it is here that cancer is most commonly found. This part of the stomach is certainly that upon which the greatest stress is thrown during digestion. It is the most muscular part of the stomach, the "grinder" as it has been aptly called, and it is, therefore, more subject to the pressure and irritation of passing food than any other part of the organ.

(*c*) The third point, a most lamentable one, is this: Of all the cases, seventy in number, that I have seen, only one has survived a period of four years from the time of the discovery of the disease. The records of cancer in any of the organs of the body surgically accessible are saddening enough, but I doubt whether a statement more deplorable can truthfully be made about any of them. Now, it cannot be said that there is anything specially vicious in cancer of the stomach as contrasted with that occurring in other organs. For we know that the *post-mortem* examination of one dead of cancer of the stomach sometimes discloses the fact that the disease has not spread beyond the stomach, that there are no secondary deposits in the liver or elsewhere, and that there is no involvement of other parts, such as the pancreas or colon, by direct extension. The origin and early development of cancer of the stomach are certainly insidious, but the growth is not usually rapid and the involvement of the parts to an extent which excludes the possibility of removal by operation is probably tardy. What are the conditions, therefore, which make our treatment of the disease so ineffective?

I believe that the faults in our attitude towards this disease lie in two directions. In the first place diagnosis is not made at a sufficiently early stage, and in the second we have too often been contented with merely palliative operations instead of attempting the removal of the growth; and further, when removal has been undertaken, the operation practised has not been based, as successful operations in malignant disease, wherever occurring, must be based, upon a knowledge of the anatomy of the organ involved, especially so far as its lymphatic distribution is concerned.

We have heard much in recent years of the problem of the early diagnosis of cancer of the stomach; but in spite of much labour and much discussion, no significant advance has been made in our power of a timely recognition of the disease. A close study of the history of the patients in my series and in the other records with which I have made myself

acquainted leaves me convinced that even with our present methods earlier recognition, and radical surgical treatment based thereupon, should be far more frequent than at present.

The type-history of a case of carcinoma is as follows: A man or woman of middle age has suffered for a few or for many years from indigestion, pain after food, vomiting, and inability to take the ordinary food in ordinary quantity; these symptoms have, it may be, come on in "attacks," in the intervals of which there has been comparative or complete freedom from suffering. At last an "attack" comes that is more rebellious than the other, vomiting is more persistent, and the loss of weight is unusual. The remedies which before gave relief are now without effect. If in such a patient there be gastric stasis, food being retained for ten or twelve hours, if there be persistent absence of free HCl after a test meal, if lactic acid be present, and if in the test-meal when removed blood is found on microscopic examination, then there is a very strong warrant for a diagnosis of carcinoma, and an exploratory operation is not only justified, it is demanded. What I have said already with regard to exploration applies only to the late case; for the discovery of the early condition exploration would be of insignificant risk. In discussing this question of exploration it is well to be clear. There can be no question that an exploratory operation is a confession of diagnostic failure; we do not explore the abdomen for conditions which we can now diagnose with certainty—conditions, it may be, which twenty years ago we were not capable of recognising with precision, conditions such as duodenal ulcer or stone in the common duct. But no one would hesitate to say that positive recognition of cancer of the stomach in its early stage—in the stage, that is, when it could be completely eradicated—is, with present clinical methods, almost impossible. If so, it should be frankly admitted, and the only certain method, exploratory operation, vindicated. If the clinical history of a case is such that suspicions created at the first are not quickly allayed, then the abdomen should be opened to enable a diagnosis to be made. Exploration should be used for the purpose of *making*, not with the object of *confirming*, a diagnosis. It is probable that, as in other matters, the comparison of the history and of the conditions revealed at operation will lead by degrees to greater assurance in our diagnosis. Before an exploratory operation is sanctioned, however, the clinical investigation should be as complete as it is possible to make it.

XVI.—*Stricture of the Small Intestine causing Acute Intestinal Obstruction.* By JAMES SHERREN, F.R.C.S. *Read February* 23, 1906.

THE following case of acute intestinal obstruction, the result of stricture of small intestine, seems to me to be of sufficient interest to bring before this Society.

S. S., a Russian Jew, æt. 36, on the evening of June 15, 1904, ate fifteen raw potatoes for a wager.

He suffered no inconvenience until 2 a.m. the following day, when he awoke with severe general abdominal pain, followed in a short time by vomiting. The pain continued and he was admitted to the London Hospital during the morning as a case of perforated gastric ulcer.

I saw him twelve hours after the onset. He gave a definite history of pain after food for two years, and of an attack of hæmatemesis three months previously.

His vomiting since admission had been gushing in character, and his face presented the appearance typical of a severe abdominal lesion. His temperature was 97° F. and his pulse 72. The abdomen was a little distended, there was no superficial tenderness, and deep tenderness was present just above the umbilicus to a slight degree only.

I diagnosed acute obstruction and operated at once.

On opening the abdomen, distended coils of small intestine protruded; on tracing the gut downwards it became suddenly collapsed about eight feet below the duodeno-jejunal junction. On looking closely the gut was seen to be a little constricted at this point, but all efforts to squeeze the intestinal contents onwards were of no avail. I then opened the intestine above the obstruction and removed large quantities of undigested raw potatoes, some of the pieces being the size of a small walnut. As the condition of the intestine above the stricture did not warrant immediate resection a Paul's tube was inserted. Before opening the intestine I examined the stomach and found a scar on its anterior surface.

He was a very refractory patient, and removed the Paul's tube the third night after the operation. However, he progressed satisfactorily and three weeks later I excised the

damaged portion of gut, performing end-to-end anastomosis by suture. The wound healed well and he left the hospital on August 8. I saw him several times during the next two months, after which he went to America.

Cases of stricture of the small intestine are rare; those leading to acute intestinal obstruction, in adults, are rarer still.

The stricture in this patient was situated about the junction of the jejunum and ileum. Externally there was no thickening to be felt and no alteration in the appearance of the peritoneal coat. It involved the whole circumference of the intestine. Unfortunately, I was unable to obtain any further information after resection.

I came to the conclusion that the stricture was probably of congenital origin, although the position was an unusual one. But Rolleston (1) has recorded a case in which diaphragmatic stricture was present in the jejunum, and two lesser marked ones lower down, in a man æt. 25, who died of nephritis and had presented no intestinal symptoms. Turner (2) has recorded a case in an infant, in which the jejunum was occluded. Although congenital strictures are most often met with in the duodenum and lower ileum, yet these and other cases lead one to suppose that they may be met with in any part of the small intestine.

In this instance it is probable that the condition would have given rise to no symptoms if the lumen had not been blocked by a mass of indigestible food.

References.

1. *Path. Soc. Trans.*, 1891, p. 122.
2. *Path. Soc. Trans.*, 1887, p. 145.

XVII.—*A Case of Strangulated Left Duodenal Hernia.*

By James Sherren, F.R.C.S. *Read February* 23, 1906.

Narath (1), writing in 1903, reported a case of left "duodeno-jejunal" hernia which he had successfully operated upon. He was able to collect 7 instances of "duodeno-jejunal" hernia submitted to operation, with 2 successes, those recorded by Neumann and Tubby.

Recently Lawford Knaggs (2) has reported a case of left duodenal hernia operated upon with success. This with the case I am reporting this evening brings the number of recorded operations to 10, with 4 successes.

Narath considered that Rose's was the only previously recorded instance of operation on a left "duodeno-jejunal" hernia. But Moynihan (3) in his exhaustive treatise considers the cases of Ridge and Hilton and Tubby to have been of this variety, and also mentions the infrequency of acute symptoms in cases of left duodenal hernia. Following Moynihan, this gives us six records of cases of left duodenal hernia submitted to operation (Ridge and Hilton, Tubby, Rose, Narath, Knaggs, Sherren); of these 4 were successful, but in 2 cases only were their symptoms those of acute intestinal obstruction.

M. S., a girl æt. 13, was admitted into the Poplar Hospital under my care on July 11. 1905.

She had been taken suddenly ill with abdominal pain of a colicky nature at 7 the same morning while in bed; this was followed shortly by vomiting. On direct questioning she gave a history of slight abdominal pain a week previously; this was not accompanied by vomiting and was not known to her mother. There was no history of any other abdominal trouble.

I saw her seven hours after the onset of the symptoms. She had vomited frequently since her admission to hospital, and her pulse-rate had risen from 96 at 9 a.m. to 120 at 2 p.m.

The correct diagnosis was at once suggested by the examination of her abdomen. A rounded swelling about the size of a cocoanut was visible in the umbilical region, extending more to the left than to the right; it was resonant on percussion and fixed.

I operated at once and found a coil of collapsed ileum which led upwards to the hernial opening. This was situated to the left side of the lumbar spine and looked upwards, backwards, and to the right. After division of the neck of the sac in a downward direction I easily pulled out about two thirds of the small intestine. No adhesions were present; the sac contained a little turbid fluid. On closer examination of the neck of the sac I found that its free border looked upwards and to the right and that the inferior mesenteric vein was in relation to its upper and left border for a short distance only. The inner end of the peritoneal fold was lost on the duodenum and left side of the root of the mesentery. I completed the division of the fold in a downward direction and removed as much as possible of the peritoneal reduplication, suturing the edges with catgut. I closed the abdominal wall in layers and the girl made an uneventful recovery. I saw her a few days ago, in perfect health.

This hernia appears to have started in a combined inferior duodenal and paraduodenal fossa. That described as duodenal-jejunal by Treitz and figured on p. 20 of Moynihan's work (2), or depicted by Sir Frederick Treves (3), resembles the fossa which I imagine was the starting-point of this hernia.

REFERENCES.

1. *Archiv f. klin. Chir.*, Bd. 71, S. 935.
2. *Brit. Med. Journ.*, December 2, 1905.
3. *Retro-Peritoneal Hernia*, p. 20.
4. *Intestinal Obstruction*, p. 108.

XVIII.—*A Case of Volvulus of the Cæcum.* By James Sherren, F.R.C.S. *Read February* 23, 1906.

VOLVULUS of the cæcum is also among the less common causes of acute intestinal obstruction. Corner and Sargent (1) were able to collect 57 cases from the literature and described 5 cases that had come under their own observation.

Most of the cases seem to have come under the care of the surgeon too late to admit of successful treatment; the following case appears to have been operated upon earlier than any previously recorded.

A. S., a waterside labourer, æt. 31, was aroused from his sleep at 3 a.m. on October 16, 1905, with severe abdominal pain localised to the umbilical region; he vomited "three minutes later" and frequently up to the time of operation.

I saw him at the London Hospital seventeen hours after the onset of the symptoms. I could obtain no history of any previous abdominal trouble and he stated that he had not suffered from constipation.

He looked extremely ill, his temperature was 101° F. and his pulse 108. The abdomen was a little distended, was rigid and deeply tender in the umbilical and hypogastric regions. A rectal examination revealed no further signs and enemata were given without result. A definite diagnosis seemed to be impossible, and I inclined to the view that he was suffering from gangrenous appendicitis because of the marked rigidity and deep tenderness present.

On opening the abdomen turbid fluid at once came out and a coil of distended gut presented. On tracing this upwards I found a mass in the umbilical region. This proved to be a volvulus of the cæcum; the gut had taken one complete turn from right to left along the axis of the superior mesenteric vessels. In the region of the hepatic flexure were some adhesions on the outer side of the colon. After untwisting the volvulus I found that the outer pouch of the cæcum was gangrenous. I resected, therefore, the cæcum and lower eight inches of ileum. The condition of the gut above was so good that I decided to do immediate anastomosis. After closing the ends of the ascending colon and ileum, I did lateral anastomosis of ileum to ascending colon by suture. After

flushing out the abdomen with hot normal saline solution, I closed the wound without drainage. He made an uneventful recovery and left the hospital on November 15. I saw him a few days ago; he appeared quite well and had had no further abdominal trouble.

I have been unable to make an exhaustive search, but so far I have found no case of volvulus of the cæcum which the surgeon was fortunate enough to see at such an early date after the onset as this, and in which primary resection was followed by recovery.

This case appears to fall into the first of the three groups into which Corner and Sargent divided cases of volvulus of the cæcum, that in which the lower part of the ascending colon is provided with a mesentery, and resembles the case reported to this Society by the late Mr. Walsham (2), and one recorded by Wood (3) in which thirty hours after the onset resection was performed with a fatal result.

References.

1. *Annals of Surgery*, January, 1905.
2. *Clin. Soc. Trans.*, 1888, p. 19.
3. *Amer. Journ. of Med. Sci.*, December, 1905.

XIX.—*Two Cases of Appendicitis due to Oxyuris Vermicularis.* By H. W. Carson, F.R.C.S. *Read February* 23, 1906.

THE first case was that of a single girl, æt. 19, who gave the following history. She had had excellent health until one month before admission to hospital. She then had pain after food, "like indigestion," and occasional vomiting during the last week.

On August 15 early in the morning she was seized with violent pains in the right side of the abdomen, accompanied by vomiting—the vomiting continued during the day, but ceased at night and did not recur. In the evening she was seen by a medical man, who reported a rapid pulse-rate and a temperature of 103° F.

On August 16 she had a rigor and was admitted to hospital.

Condition on admission.—Temperature 103·8° F., pulse 116, respiration 32. Patient anæmic, tongue moist, but slightly furred. She complains of severe pain and tenderness on the right side of the abdomen. The bowels were opened on the day before admission.

On examination.—The abdomen moved with respiration, and was not distended. There was no rigidity of the abdominal walls. Superficial tenderness was marked over a large area of the right side of the abdomen, extending from the edge of the ribs to the iliac fossa, with tenderness in the right loin, most marked above the crest of the ilium. There was much tenderness on deep pressure over McBurney's point. There was no swelling, but an area of dulness could be made out under the right rectus muscle extending two inches above and one inch below the level of the umbilicus. The rectum was full of fæces, but after these had been removed by enema nothing abnormal was found on rectal examination.

The heart and lungs were healthy.

The abdomen was opened and the appendix found to have a bulbous tip and slight recent adhesions between its proximal half and the cæcum. It was removed. The mucous membrane of the distal half-inch was deeply congested but not

ulcerated. A single female oxyuris vermicularis was found in the congested area.

Subsequent history.—The patient at once lost all pain, and on the day following operation expressed herself as feeling quite comfortable. The temperature and pulse-rate, however, returned to normal very gradually, the evening temperature reaching normal only on the ninth day. Repeated examinations of the lungs were made, but nothing was discovered. The bowels were confined, but daily evacuations were obtained by enemata. The wound healed perfectly, stitches being removed on the ninth day, and at no time was there any distension or abdominal discomfort. On August 30, after the temperature had been normal for six days, patient complained of headache and drowsiness. The temperature rose to 102·6° F. at 7 a.m. and was 104·4° F. at 7 p.m. Pulse-rate 120. Examinations of the abdomen and chest were negative. The temperature reached normal again on September 2, no physical signs having developed during this time.

On September 6 the temperature rose again to 102·6° F. (7 a.m.) reaching 104·8° F. at 7 p.m., patient feeling drowsy, but not otherwise uncomfortable. Nothing was found to account for the temperature, which fell to normal on September 9, and the patient left the hospital a few days afterwards. At no time during her stay in hospital did she pass any worms, and as far as she was aware she never had passed any. She writes to say that she has a "very sharp pain with the changes of the weather and cannot have action without medicine." She has not passed any worms.

The second case was that of a married woman, æt. 24, who gave the following history. Her health had been good except for an attack of abdominal pain, occurring one year before, which lasted for three weeks.

On November 29 patient was seized with a severe pain in the lower part of the abdomen, accompanied by slight vomiting. She was seen by a medical man, who diagnosed appendicitis and advised her removal to hospital.

She was admitted on November 30.

Condition on admission.—Patient's general condition was good, but she was apparently in considerable pain. Tongue moist, but slightly furred, temperature 100·6° F. Pulse 118, regular, respiration 28. The heart and lungs were healthy.

The patient complained of severe pain in the lower part of the abdomen, most marked in the left iliac fossa. The abdomen moved well with respiration; there was no rigidity

of the abdominal wall and no tumour could be felt. Percussion gave a tympanitic note. There was tenderness on deep pressure in the right iliac fossa, but this was at a lower level than is usual in appendix cases and resembled the tenderness occurring in pyosalpinx cases. *Per rectum* there was some general tenderness, *per vaginam* there was acute tenderness in both fornices, but nothing abnormal was discovered, though bimanual examination was difficult owing to the pain elicited. There was not at the time, nor had there been, any vaginal discharge.

A provisional diagnosis of pyosalpinx was made, and as the patient was in great distress immediate operation was decided on. The abdomen was opened in the middle line. The uterus and appendages were found to be normal and the appendix was apparently normal. Mindful of the case three months before, I removed the appendix, and found three thread-worms in the distal end of it. There was no injection or ulceration of the mucous membrane.

The temperature fell to normal on the evening of the day of operation, but the pulse-rate was somewhat rapid for two days. Stitches were removed on the eighth day, the wound being soundly healed. At 11 a.m. on that day the temperature rose to 100·8° F. with a pulse-rate of 98. There were no symptoms, and both temperature and pulse were normal next morning; but on the eleventh day after operation the patient complained of headache and abdominal pain and the temperature rose to 102° F. with a pulse-rate of 112. Nothing could be found to account for this. The bowels were not confined. Next morning the temperature and pulse-rate were normal again and from that point convalescence was uninterupted. She writes to say that about a month ago she had severe pains, lasting about one week. She has not noticed any worms in her motions.

Both cases present certain features in common. In each case the patient was an adult woman in whom there had been no previous signs of thread-worms. In each case subjective signs were more marked than the objective—that is to say, that though tenderness and hyperæsthesia were well marked, there was no abdominal distension, no rigidity, no tumour. In both cases also the convalescence was interrupted by attacks characterised by elevation of temperature and pulse-rate and headache. Compared with ordinary cases of appendicitis, these two cases present certain unusual symptoms.

Onset.—The only point of difference with regard to the

onset is that in the first case a temperature of 103° F. occurred on the first day and a rigor occurred on the second day. As far as my experience goes a temperature of 103° F. on the day of onset is unusual, and the occurrence of a rigor at an early stage in appendicitis is quite a rarity.

Symptoms.—The most striking symptom was the degree of hyperæsthesia in both cases. In the first case the tenderness was limited to the right side, but extended far back into the right loin. In the second case tenderness was complained of in both iliac fossæ, worse on the left side, but the most acute tenderness was felt on vaginal examination, especially in the left fornix. Indeed, so much pain was caused that a thorough bimanual examination of the uterine appendages was impossible.

The general condition of both patients was also misleading. The first patient was apparently seriously ill, the temperature approaching 104° F. with a weak pulse of 116. In fact, the case resembled one of those severe gangrenous appendix cases without marked physical signs such as one sees occasionally in children. The second patient, though not apparently so seriously ill, was in great pain, with a pulse-rate of 118, and as this condition had lasted for twenty-four hours and was increasing in severity, it was looked upon as an indication for immediate laparotomy. In the second case there was a history of abdominal pain occurring one year before and lasting for three weeks, but whether this was appendicular or not it is, of course, impossible to say.

Signs were practically absent in both cases. There was no abdominal distension, no rigidity of the abdominal wall, no interference with the respiratory movements, and no tumour. In the first case an area of dulness was found under the right rectus at the level of the umbilicus, but this had no relation to the position of the appendix. Had one met with this hyperæsthesia with absence of physical signs in a child, especially if associated, as in the first case, with a temperature of 104° F., I think one would have suspected that the case was one of pneumonia with referred abdominal pain, but repeated examinations of the chest failed to find any pulmonary complications. The occurrence in both cases during convalescence of a sudden rise of temperature with headache is curious. It may, of course, have been merely a coincidence resulting from a sudden chill or a slight attack of influenza, or it may conceivably have resulted from the irritation of thread-worms in the cæcum or colon, though no more were

seen during the patient's stay in hospital or since. The after-history of these two cases is unimportant except that the second patient has had an attack of abdominal pain since leaving hospital which lasted one week.

The question as to whether intestinal parasites do or do not cause appendicitis has given rise to very different opinions. On the one hand Dr. G. F. Still, in the *Practitioner*, February, 1905, quotes Heller as saying that there is no evidence that thread-worms give rise to appendicitis; on the other there are a definite number of published cases in which thread-worms have been found in diseased appendices. Metchnikoff in the *Bulletin de l'Academie de Medicin*, March 12, 1901, p. 301, writes on "Worms as a Cause of Appendicitis"; von Moty in the *Echo Médical du Nord*, 1902, p. 217, goes so far as to say that oxyuris and trichocephalus give rise to chronic appendicitis, while ascarides give rise to gangrenous appendicitis. There is no doubt that thread-worms may exist in the appendix without giving rise to symptoms. Dr. Still (*British Medical Journal*, 1899, vol. 1, p. 848) reports that in 200 necropsies on children under twelve he found the oxyuris in the appendix twenty-five times and in six instances they were found in the appendix alone. In only one apparently were there any signs. This was the case of a boy æt. 9, who died of pericarditis and in whose appendix 111 worms were found. He had complained of pain in the appendix region without tenderness.

I have been able to find only a few reported cases where thread-worms have been found in an appendix removed during life for the cure of appendicitis, and unfortunately, in only a few of these are any details of the symptoms given. All seem to be cases of relapsing appendicitis. Frazier (*University Medical Magazine*, 1900, vol. xiii, p. 65) reported a case of a female æt. 2, in whom there had been a five months' history of appendicitis. Thread-worms were found in the appendix without ulceration. In the discussion which followed Dr. H. D. Beyea gave details of a case of a married woman æt. 22, who had suffered for two and a half years, since the birth of a child, with backache, headache, and nervousness. Six weeks before operation she had severe pain, lasting for one week, in the appendix region. Three weeks before operation a "convulsion" occurred, followed by others of an hysterical type. There was extreme tenderness but no tumour. A single oxyuris was found in the inner third of the appendix without hyperæmia. Erdmann reported in the

New York Medical Journal, March 19, 1902, four cases containing between six and thirty thread-worms. He gives no account of the symptoms. In *Pediatrics,* May 15, 1900, p. 411, there is a report of a case occurring in a boy æt. 8, but no details are given. Guinard (*Traité de Chirurgie. Le Dentu et Delbet,* tom. vii, p. 476) reports a case of thread-worms giving rise to symptoms which occurred in Routier's practice. A case is reported by Professor Bégouin (*Gazette Hebdomadaire des Sciences Médicales de Bordeaux,* July 27, 1902) of a woman æt. 24, who had had for four or five years attacks of right iliac pain, occurring at long intervals and lasting three or four days. There was a slight tender tumefaction the size of an almond at McBurney's point. The appendix was slightly turgid; fifteen thread-worms were found, with four small ulcerations.

In the *Intercolonial Medical Journal* of Australasia, commented on by the *Lancet,* 1902, vol. i, p. 539, Mr. R. Hamilton Russell reports the case of a boy in whom the chief symptom was severe pains. Some correspondence followed in the *Lancet,* 1902, vol. ii, p. 58, and a case was reported by Mr. Bolton Carter, *Lancet,* July 2, 1902, as having occurred at the Leicester Infirmary; the patient was a boy. In September 1902, Mr. Jonathan Hutchinson, junr., reported a case in the *Lancet,* 1902, vol. ii, p. 837, of a young woman operated upon for relapsing appendicitis in whose appendix many live thread-worms were found. Morkovitine in the *Russky Vratch,* February 28, 1904, reports a case of a man æt. 22, in whose appendix twelve live thread-worms were found.

This makes a total, with my two cases, of 15, of which 6 were females, all, with one exception, young adults, 4 were males, all except one boys, and in 5 cases the sex was not stated. In the few cases where symptoms are given severe pain and tenderness without local signs seem the rule and in only one case was there any ulceration of the appendix. While it is certain that thread-worms may exist in the appendix without giving rise to recognisable signs, it seems that we must believe either that thread-worms may cause appendicitis or that the presence of the parasites is a pure coincidence. The latter theory is, I think, untenable in view of the fact that the symptoms in these cases are much more severe than the lesions found would warrant, and I prefer to believe that thread-worms may cause appendicitis, and that the attack is characterised by exaggeration of symptoms and absence of physical signs.

XX.—*A Case of Appendix Abscess with Profuse Hæmorrhages; Recovery.* By JOHN D. MALCOLM, F.R.C.S. *Read February* 23, 1906.

THE subject of the following history was an unmarried woman, æt. 36, who had a long record of indefinite discomfort, rather than pain, in the appendix region. The symptoms were always attributed to indigestion, and were for the most part made light of. In the summer of 1905, when it was noted that the patient was particularly well, she was suddenly seized with severe abdominal pain. The temperature rose, and after three days was 102·8° F., the pulse being about 100 at this time. The temperature then fell very gradually during six days to 101·6° F.

I saw the patient in consultation on the ninth day of the illness. She had then a tender swelling in the region of the vermiform appendix, with impaired resonance on firm percussion to the inner side of the right anterior superior iliac spine, but there was no complete dulness. The pulse was from 80 to 90, the general condition was good, the abdomen was not distended, and the bowels were easily evacuated by laxatives. I agreed with the diagnosis already made, that pus had formed around the vermiform appendix, and it was decided that an immediate operation for its evacuation should be undertaken. At noon I cut down upon the parts by an incision parallel to and about three quarters of an inch from the outer portion of Poupart's ligament. Although I separated the peritoneum deeply from its attachments and prolonged the incision towards the loin, I did not seem to get in touch with an abscess wall. The parts were everywhere soft, as if adherent bowel intervened between my fingers in the wound and the pus which I believed to be present. To make certain of the relations, I opened the abdominal cavity in the middle line and found that the head of the cæcum was everywhere surrounded by adhesions. Behind and rather to its inner side I made out a very soft fluctuating swelling about the size of a tennis-ball between a finger in the peritoneal cavity and one in my first wound. By pushing the cæcum further forwards and inwards I was

able to insert a pair of forceps through the lateral incision into an abscess behind the bowel and to evacuate four or five ounces of exceedingly foul, thin, and rather dark-coloured pus. As the appendix was not at once felt, no search was made. The cavity was washed out with weak iodine and water solution, rubber tubes with a lumen of about half an inch in diameter and also a small sized one were put in. The posterior part of the wound was closed by sutures. The median incision was sewn up also, it gave no trouble at any time, and although the bowels required laxatives and enemata there was never any cause for anxiety in connection with the peritoneum.

The patient's condition was satisfactory for three days, the temperature falling gradually, but the discharge continued to be very offensive. In the early morning of the third day, after sleeping off and on for nearly four hours, the patient felt something liquid running over her side, and, on examination, the dressings were found to be soaked with fresh blood. In a short time the temperature dropped a degree to 99·4° F., and on changing the dressings it was obvious that there had been a very considerable hæmorrhage. Although the discharge was still foul the blood appeared quite healthy, and by means of a pair of forceps a complete cast of the smaller tube was withdrawn. Blood then welled up freely through this tube with a distinctly pulsating action, but it gradually ceased to flow. The region to the inside of the wound was firmly padded, and the syringing with weak antiseptic solution, which had been performed twice daily, was stopped. An oozing of dark blood continued, but the patient seemed fairly well. The temperature rose to 101·4° F., and then gradually fell until the sixth day, when there was another hæmorrhage, so free that the patient fainted and became cold, her condition for a little while being very alarming. Strychnia and ergotin were injected before I arrived, and the condition of collapse was quickly recovered from.

The part of the side wound which had been sewn up appeared to heal well until the fourth day, when some of the stitch-holes were red and inflamed and the sutures which had caused the most irritation were then taken out. After the second hæmorrhage it was obvious that blood had been forced along the deep layers of the incision, and that all the scar-tissue was breaking down, whilst some of the suture-holes were suppurating. It was also obvious that an attempt

must be made to find and to tie the bleeding point. Before reopening the wound it was thought desirable that a consultation should be held and Mr. Clutton saw the patient. He agreed that the wound should be opened up, and it was conjectured that a sloughing appendix might be found in the abscess cavity and that the hæmorrhage arose from some vessel in its mesentery. On the seventh day I reopened the lateral wound and made a larger communication between the abscess cavity and the superficial parts by tearing the peritoneum freely. The deep cavity was distended by blood, and although there was still a very foul odour from the discharge, the clot was so firm that more than once I thought I might be pulling out the sloughed appendix. When all the clot was cleared away, however, no appendix was discovered. It was impossible to see the abscess walls, but some protruding tissues on their inner surface were removed and these were obviously appendices epiploicæ. My knowledge of the position of adhesions, obtained by having had my fingers in the peritoneal cavity at the first operation, enabled me to make a thorough exploration with safety. There was no fresh hæmorrhage and no bleeding point was discovered. On the raw surface made by my incision there were several black, well-defined sloughs, of small size, not more than about one third of an inch in length and not extending deeply. The wound was lightly packed with gauze, and from this time convalescence was steadily progressive. In three days the discharge was not offensive, but there were still some sloughs to separate. When these came away union by granulation was very rapid. For a considerable time after the second operation there was a discharge of mucus, which must have come from the remains of the appendix, but the parts healed completely and the patient was able to leave London, with a practically closed wound, just over seven weeks from the date of the second operation. Six weeks later the incision was firmly healed and the scar was almost linear. The patient complained of a slight tenderness over the cæcal region, which might have been due to the condition of the appendix or possibly to the presence of adhesions. From the fact that the wound healed rapidly although there was a free discharge of mucus, it seemed certain that the communication between the appendix cavity and the cæcum was fairly free, whilst the flaccid condition of the abscess at the date of operation also favoured the view that a partial discharge was taking place through the

appendix at that time. Its proximal part, and possibly the whole of the appendix, would therefore seem to be still in the body. The most recent account of this patient is that she has not suffered any pain, whilst the general health and the powers of digestion are improving.

Hæmorrhage in connection with appendicitis is a rare complication, which may, however, occur in various ways.

Dr. Kelly and Dr. Hurdon * quote a case of fatal hæmorrhage from the epigastric artery which had been clamped, but not ligatured, in a child, and another in which six days after the resection of an appendix which was in a quiescent condition the patient passed an enormous quantity of blood *per rectum* and vomited between 300 and 400 c.c. of blood mixed with the contents of the stomach. "The patient recovered with no more serious disturbance than the great fright." The hæmorrhage in this case was attributed by the operator to the slipping of a ligature.

The same authors, in describing the "symptoms of acute appendicitis," said that "Hæmatemesis has been described by Treves, by Dieulafoy, and by Matheson and others, and is attributed generally to a toxic degeneration of the gastric mucous membrane, with erosion of small blood-vessels." † They also stated that "in a few instances the erosion of a large blood-vessel occurring during the course of an appendicitis or as a post-operative complication has led to a fatal termination. Osler (*Montreal Hosp. Gaz.*, 1880) mentions an instance of fatal hæmorrhage into the intestine, Matheson (*loc. cit.*) a fatal hæmatemesis, and Lendet (*Arch. Gén. de Méd.*, vol. civ, p. 140) a case of hæmorrhage into the arachnoid space. The symptoms are those commonly produced by internal hæmorrhage, and as a rule positive evidence is found in the passage of blood by the mouth or by the rectum." ‡

Mr. W. H. Battle and Mr. E. M. Corner described hæmorrhage from the bowel in these cases as usually arising either near the site of the appendix or at the hepatic flexure of the colon. In the former situation they attributed the bleeding to causes arising within the bowel and in the latter to mischief coming from outside it. They said, however, that the connection between the appendix mischief and the hæmorrhage was

* *The Vermiform Appendix and its Diseases*, by Dr. Howard A. Kelly and Dr. E. Hurdon, p. 662.

† *Loc. cit.*, p. 391.

‡ *Loc. cit.*, p. 404.

not clear.* Three of the following cases are mentioned by these authors.

Dr. Charles B. Box and Mr. Cuthbert S. Wallace have published a case of "appendicitis with profuse hæmorrhage closely resembling typhoid fever."† After the patient had been ill for sixteen days there was a discharge of bright red blood from the bowel to the extent of half a pint. A similar discharge recurred twice, and on each occasion the bright blood was followed by some darker material. Death followed on the twenty-first day. An abscess round the appendix was found at the autopsy, with a secondary focus of suppuration in front of the right kidney and communicating with the adjacent colon.

A case resembling mine, but in which the hæmorrhage was a less urgent symptom, was published by Mr. Langton and Sir Dyce Duckworth.‡ A boy, æt. 16, had an appendix abscess opened six days after his illness began, two thirds of the appendix being found gangrenous and the pus being very fœtid. The appendix with a concretion was removed and the parts were drained. On the eighth day after the appendix abscess was opened the patient complained of some pain and at the next dressing a large clot was found over the wound. The patient recovered and the hæmorrhage did not recur, although a secondary intra-peritoneal abscess formed on the left side of the abdomen and had to be evacuated and drained.

A much more severe case, as regards the hæmorrhage, has been recorded by Mr. F. Ramsay of Tasmania. The patient's age was ten years, and about a month after the first symptoms occurred between three and four ounces of pus were evacuated from an appendix abscess and the cavity was drained by means of gauze and a rubber tube. On the ninth and on the eleventh days after the operation there were severe hæmorrhages, and the bleeding was not stopped until the external iliac artery was tied from the inside of the peritoneal sac and its distal end from inside the abscess, there being a large opening in this vessel. The patient recovered.§

Another, a fatal case, was put on record by Dr. John O'Connor of Buenos Ayres. A middle-aged man who refused

* *Diseases of the Vermiform Appendix and their Surgical Complications*, by Mr. W. H. Battle and Mr. E. M. Corner, p. 177.

† The *Lancet*, vol. i., 1903, p. 1588.

‡ *Med.-Chir. Trans.*, vol. lxxii, p. 433.

§ The *Lancet*, vol. i, 1903, p. 1590.

to be operated upon had his cæcal region poulticed for six weeks. No discharge took place, and the medical attendant was then allowed to make "a little cut just big enough to let out the matter." Toxic symptoms rapidly disappeared and the purulent discharge had almost ceased after ten days. The patient then felt his side wet, the dressings were found to be saturated with blood, and he "rapidly succumbed." There was no *post-mortem* examination.*

There can be little doubt that in the last three cases and in my own case the hæmorrhage was exactly comparable to that which we read about as "secondary hæmorrhage," and which was quite common before the days of antiseptics, being due to sloughing of the wall of some vessel.

In those pre-antiseptic days the infection was frequently carried from case to case on the hands or instruments of the surgeon or by his assistants, and it would appear that sometimes the atmosphere was so full of microbes that wounds became infected by exposure alone at the time of the operation or of the dressings.

But by modern methods of surgery this complication is almost unknown. My practice is to have all the instruments and swabs sterilised by heat, and I am careful that the instruments are quite clean before they are sterilised, a point which I think is not always sufficiently insisted upon, but which is of great importance, for even small particles of blood-clot or tissue of any kind may remain infective in spite of much heating. My hands, after the nails have been made as smooth and clean as possible by means of a penknife, are washed in a liberal quantity of methylated spirit, soap and water, a nail-brush, sterilised by heat and new for choice, being vigorously used. When the hands are as clean as I can make them they are thoroughly soaked in 1 in 1000 corrosive sublimate solution and again scrubbed in this with a nail-brush. The patient's skin is treated in a similar way, turpentine being also used, and, when there is time, it should be prepared the night before the operation, a compress soaked in 1 in 40 carbolic acid solution being applied and kept moist by some impervious material. A second thorough cleansing, as if the first had not been carried out, is desirable shortly before the operation. It is, of course, remembered that some skins are more delicate than others; some surgeons, for instance, find that 1 in 1000 corrosive sublimate solution makes the hands rough and harsh.

* The *Lancet*, vol. ii, 1902, p. 428.

During dressings I am always careful not to expose the parts unnecessarily, as I believe that contamination by infection from the air is a possibility. Therefore an open wound, as soon as it is exposed, is covered by a sterilised swab wrung out of a weak antiseptic solution—1 in 60 carbolic or 1 in 3000 corrosive sublimate.

I state these details because the fact that in all the cases of secondary hæmorrhage above referred to the bleeding took place after the wounds had been repeatedly dressed—that is, from three to eleven days after the abscesses were opened—might be considered to point to infection from without as the cause of mischief. This view would be strengthened by the fact that in two of the cases I have quoted a month and six weeks elapsed between the onset of symptoms and the evacuation of pus, whilst in the other and in my own case there were respectively six and nine days, during the greater part of which suppuration had probably existed without causing hæmorrhage. Moreover, in the original accounts of the cases quoted, so far as I have seen them, I have not found it definitely stated in any that bleeding before an abscess was opened took place from within the abscess cavity.

The evidence that infection came from without would be of great importance if any ordinary, easily accessible infective organism could be held responsible for the mischief. But this was evidently not the case. There can be little doubt that the hæmorrhage depended on some peculiar micro-organism or on some particularly virulent effect of one of the common forms of micro-organism. The precautions detailed having been taken, and the source of infection from within being so obvious, it may, I think, be regarded as certain that the particular micro-organism which caused the sloughing of tissue in the case under discussion developed in the abscess by infection from the colon. Hence, as in the pre-antiseptic days, it would appear that we may still, in connection with an appendix abscess, have a development of some "germ" which gives rise to a local gangrene. It is exceedingly fortunate that this complication is a rare one.

It would seem that various pathogenic organisms may be found in the bowel, and may become the dominant factor controlling the phenomena which follow the development of an appendix abscess.

This accounts for the variety of consequences which may be observed. In one case a simple abscess forms, apparently with no tendency to spread except by distension, and rapid

healing follows if the pus finds vent either by rupture on to a surface or by incision. In another case there are hardly any defining walls to the abscess, and these are rapidly pushed away and replaced by others so that an indefinite extension of the pus cavity amongst the intestines takes place. In a third the abscess, whether localised or not, gives rise to secondary foci of suppuration, either in the immediate neighbourhood of the appendix, at some other part of the abdominal cavity, in the pleura, or elsewhere; and again, a sloughing effect, with or without hæmorrhage, may be produced.

Until I met with the case recorded above, I thought that a strictly localised, and especially a flaccid, abscess might be safely drained by means of tubes. It would appear, however, that the medical man and his patient are really to a great extent at the mercy of the dominant germ of each particular case; for, except perhaps in instances of colic of the appendix, and in some other rare conditions, certain cases of cancer, for example, septic complications always arise before professional aid is sought on account of disease of this part. The surgeon, in deciding the treatment to be adopted, should therefore take into consideration that one of the more unusual micro-organisms may possibly be present and effective for mischief. It would be well to provide for such a contingency, and apparently it would be wise, as I understand is already the practice of some surgeons, not to use any sutures for the external wound in evacuating appendix abscesses, but to open the deeper parts as widely as is consistent with safety in other ways, and always to pack the cavity with gauze. It is still possible, however, that hæmorrhage may arise under any method of treatment, and Mr. F. Ramsay's case above referred to was, in fact, drained by means of gauze and a rubber tube.

A defective power of clotting in the blood is sometimes put forward as a cause of hæmorrhage, and I would therefore again remark on the healthy, firm clots that were formed in my case.

It is to be regretted that a bacteriological investigation of the discharges was not made, but perhaps some member of this Society may be able to name the organism which appears to grow in the cæcum, which does not interfere with blood coagulation, which causes small black patches when enclosed between the raw surfaces of a wound after being exposed to the air and to weak antiseptic lotions, which may destroy the

walls of a vessel and induce severe hæmorrhages whilst the exposed parts of the wound are to all appearances healthy, which shows no tendency to induce secondary foci of suppuration, and which appears to grow freely when an abscess cavity is not fully drained, but ceases to be harmful if the wound is opened up thoroughly and packed with gauze.

XXI.—*A Note upon the Relation of Traumatic Diabetes Insipidus to Glycosuria.* By HERBERT FRENCH, M.D., and C. B. TICEHURST, B.A. *Read March* 9, 1906.

THE following is an addition to the history of that case which was published in Vol. LVII of the *Guy's Hospital Reports*, under the title "A Research upon the Metabolism of a Patient suffering from Diabetes Insipidus, following upon Fracture of the Skull."

The notes of the case at the time of the last publication are briefly as follows: William T., æt. 44, was in perfect health up to June, 1901. He then met with a bicycle accident, fracturing his basisphenoid. He was unconscious for fourteen days, cerebro-spinal fluid dripping from his nose. He recovered and became active and able to resume work, but suffered from bilateral temporal hemianopia, slight strabismus, polydipsia, and polyuria, all attributable to his head injury.

His condition was typical of diabetes insipidus. He was under close observation from September 12 to October 15, 1901, during which time all his food and drink were strictly measured and analysed, as were also his urine and fæces. He passed, upon the average, 7500 c.c. of urine daily, of specific gravity 1004. He drank fluid proportionately. The urine was daily examined for sugar, but on no occasion could any be found.

Not only did the man not pass sugar in his urine when he was taking ordinary diet, but he could not be made to pass sugar when his carbohydrate diet was abnormally increased. Upon different occasions he was given excess of lactose, of grape-sugar, of cane-sugar, and of starch. His daily consumption was pushed until he was taking over 700 grams of dry carbohydrate in addition to the ordinary amount of proteid and of fat, yet no sugar appeared in his urine at that time. His diabetes insipidus seemed then to be quite free from any tendency to glycosuria.

The history of the case subsequent to the metabolic research carried out in 1901 is interesting in that the patient has now spontaneously developed a glycosuria which at that

time could not be dietetically produced. During 1902 and 1903 the man remained actively at work as an insurance agent, suffering from no inconvenience except his impairment of sight and his continued polydipsia and polyuria. He ate well, and maintained his vigour and weight. In September, 1904, his medical attendant detected a small amount of sugar in his urine for the first time—three years and four months after his fractured base and the onset of diabetes insipidus. Notwithstanding treatment the glycosuria persisted. The man did not suffer any change of symptoms, and did not lose weight, nor relinquish his work. In February, 1905, he came into Guy's Hospital again, under the care of Dr. Beddard (Medical Report, No. 124). In his general condition he was much the same as upon his discharge in 1901. His weight had not altered, he had the same slight strabismus, the same bilateral hemianopia, the same polydipsia. His heart, lungs, abdominal organs, and general nervous system seemed perfectly healthy.

The condition of his urine is the main point of interest. Whilst upon ordinary diet analyses showed:

Date.	No. of oz. of urine passed in each 24 hours.	Specific gravity.	Reaction.	Percentage of sugar.	Total sugar in grains per 24 hours.	Diacetic acid (ferric chloride test).	Acetone (sodium nitro-prusside test).
Feb. 21	100	1016	Neutral	4·76	2080	Not found	Not found
„ 27	106	1016	„	2·63	1220	„	„
„ 28	172	1016	„	3·57	2687	„	„
March 1	243	1016	„	2·84	3020	„	„
Average	155	1016	Neutral	3·45	2252	Not found	Not found

The sugar was estimated by Pavy's method, and was shown to be glucose both by the fermentation test and by the formation of phenylglucosazone crystals.

The patient was then put upon the strictest diabetic diet, and the urine analyses for a week upwards were as follows:

Date.	No. of oz. of urine passed in each 24 hours.	Specific gravity.	Reaction.	Percentage of sugar.	Total sugar in grains per 24 hours.	Diacetic acid (ferric chloride test).	Acetone (sodium nitro-prusside test).
March 2	179	1016	Neutral	2·02	1580	Not found	Not found
„ 3	222	1014	„	0·83	809	„	„
„ 5	186	1010	„	0·87	706	„	Slight
„ 6	206	1010	„	0·54	483	„	„
„ 7	188	1010	„	0·27	219	„	Not found
„ 8	193	1010	„	0·25	209	„	Slight
„ 9	196	1010	„	0·35	270	„	„
„ 10	202	1010	„	0·48	489	„	„
Average	200	1011	Neutral	0·70	596	Not found	Slight

Thus the sugar fell to one quarter of what it was upon ordinary diet; but the man who in 1901 could not be made to pass sugar in his urine when he had carbohydrate pushed to nearly double what an ordinary man takes in 1905 failed to assimilate properly the minimal amount that a strict diabetic diet contains. The restricted diet was carefully continued for a much longer period, but sugar was persistently present in the urine.

It is not within the province of the present note to discuss whether or not there be a fundamental distinction between "alimentary glycosuria" and "true diabetes mellitus." The difference may be one of degree only. It is, however, recognised that some cases of glycosuria are simpler than others, and that in the simpler cases there is usually no diacetic acid or acetone in the urine, whilst the glycosuria disappears when the carbohydrate food is strictly limited. It was thought that the present case was possibly a simple alimentary glycosuria, and that strict dieting would cause a disappearance of the sugar from the urine. We were a little surprised that this did not turn out to be the case. We lay no stress upon the occurrence of acetonuria, because it has been found that a perfectly sound man will pass acetone in his urine if all the carbohydrate be eliminated from his food. Our patient's urine was by no means typical of diabetes mellitus; diacetic acid was never found; the specific gravity was low. Nevertheless the fact that the sugar did not disappear entirely upon careful dieting would seem to show that the condition was not "simple" nor purely "alimen-

tary," though the patient maintained his weight and felt quite fit for work.

Brouardel and Richardière (1) have written an exhaustive paper upon the relation of injury to diabetes mellitus, from a medico-legal point of view. They could find only thirty-three cases in which injury could be put down as a factor in the causation of glycosuria. The injuries in their cases were by no means always to the head. Of their 33 collected cases:

17 were secondary to head injuries.
5 „ „ injury to the spine.
11 „ „ injury to various parts of the body.

In regard to the time after the injury at which glycosuria was discovered:

In 8 cases there was glycosuria within 2 days of the injury.
„ 4 „ „ „ „ 7 „ „ „
„ 5 „ „ „ „ 3 to 6 weeks of injury.
„ 3 „ „ „ 2 months „
„ 2 „ „ „ „ 3 „ „
„ 1 „ „ „ „ 4 to 5 months „
„ 9 the intervals were longer still up to 4 years of injury.

They give examples of every degree of glycosuria secondary to injury. In some the condition was temporary, rapidly getting well by itself; in others careful treatment was required, but cure resulted; in others, again, the glycosuria persisted in spite of treatment but the condition seemed to be stationary, and did not seriously affect the patient; finally, there were those bad cases which ran the ordinary course of rapid diabetes mellitus with a fatal ending. Nevertheless they lay stress upon the rarity with which diabetes can be attributed to injury. Griesinger (4) holds the same view after analysing 225 cases, amongst whom he found only 20 in which trauma could by any possibility be put down as a cause. Senator (6), having collected 1090 cases of diabetes mellitus, could find but 11 cases, or 1 per cent., in which he could definitely attribute the condition to any injury.

The question of the relation of head injury to diabetes mellitus has been discussed in a previous paper (2) in which, and in a paper by Futcher (3) references to the literature are given. The conclusions drawn are, that head injury rarely causes either form of diabetes, but that diabetes insipidus is attributable to injury rather less infrequently than is diabetes mellitus.

The majority of cases of diabetes insipidus are not

associated with glycosuria. Some Guy's Hospital cases have had diabetes insipidus for many years without becoming seriously ill, and without developing glycosuria. When, however, it is so well established that Claud Bernard's puncture of the fourth ventricle leads to glycosuria, and when it is recognised that injuries and tumours of the base of the brain certainly may be a cause of polyuria, it is contrary to expectation that a head injury which is followed by persistent diabetes insipidus should not also lead to glycosuria. Nevertheless, we have been able to find only one case in the literature which exactly resembled our own. This is recorded by Brouardel (1). A man, æt. 45, met with a railway accident on July 18, 1884. He was generally concussed, but did not lose consciousness. Twelve days later, on July 30, 1884, it was noticed that his urine was "very much increased" in quantity, and that no sugar was present. He recovered, but continued to suffer from polyuria and excessive thirst. He was again examined on December 24, 1884, when the polyuria with absence of sugar was confirmed. The same condition persisted through the greater part of the next year, but on November 30, 1885, sixteen and a half months after the accident, he was found to be passing sugar to the extent of 47 grams per litre. The specific gravity of his urine was 1032, and the daily quantity "large." There is no mention of diacetic acid or of acetone having been tested for. The man's general health was good, and his condition appears to have been very similar to that of the present patient. In both cases polyuria immediately followed a severe accident affecting the brain; in both the polyuria persisted; in both there was absence of sugar for a long while after the accident; in both sugar ultimately appeared in the urine, in Brouardel's case $1\frac{1}{3}$ years, in our case $3\frac{1}{3}$ years, after the injury. In both cases the general health was excellent, notwithstanding accident, polyuria, and glycosuria.

In our search for other similar cases we have come across one which is almost the converse. Käemnitz (5) records it. A woman, æt. 17, met with an accident in which her head became severely compressed among the wheels of some machinery. She was comatose, and the same day passed 500 c.c. of clear, non-albuminous urine, free from sugar. Six days later, being then conscious again, she complained of great thirst, and passed much pale urine, of specific gravity 1023, and containing 1 per 100 of sugar. Two weeks later the urine had a specific gravity of 1029, and there were 2·3 parts of sugar

per 100. For one month the urine continued much the same, then the sugar began slowly to diminish. At the fourth month from the injury there was no sugar in the urine, but the patient passed from 4000 c.c. to 6000 c.c. daily, of specific gravity 1005. The polyuria persisted. Sugar did not recur. The condition seems to have been one of traumatic polyuria and glycosuria, which passed on to one of simple diabetes insipidus.

In our previous paper we drew the conclusion that the head injury which had caused diabetes insipidus in our patient had in no way diminished his power of metabolising carbohydrate. It is true that this was the case at that time, but it seems important to record the fact that in the course of a few years a complete change occurred in this respect. The patient in the early stage of his traumatic diabetes insipidus had been able to assimilate enormous amounts of starch, glucose, lactose, and cane-sugar, but after three and a third years ceased to be able to metabolise properly even quite small quantities.

A year later the glycosuria had as spontaneously ceased, the patient's weight had increased one stone, the polyuria and polydipsia persisted unchanged. The patient was shown personally to the Society on March 9, 1906.

Our best thanks are due to Dr. Hale White, under whose care, at Guy's Hospital, the patient was and is, and who has given us every facility in our observations.

References.

1. Brouardel and Richardière, "Du Diabète traumatique au point de vue des expertises médico-légales," *Annales d'Hygiène publique et de Médecine légale*, Paris, vol. xx, 1888, pp. 401–429.

2. Butler and French, "A Research upon the Metabolism of a Patient suffering from Diabetes Insipidus following upon Fracture of the Skull," *Guy's Hospital Reports*, vol. lvii, 1902, pp. 133–169 (for which see references to the general literature of diabetes insipidus).

3. Futcher, "Diabetes Insipidus, with a Report of five Cases," *Johns Hopkins Hospital Reports*, vol. x, 1902, pp. 197–247, (to which refer also for other general literature upon diabetes insipidus).

4. Griesinger, Brouardel, *Thèse d'agrégation*, 1869.

5. Käemnitz, *Archiv der Heilkunde*, 1873, xiv, 447.

6. Senator, *Monats. für Unfallheil.*, 1900, No. 1.

XXII.—*A Case of Post-Traumatic Hæmorrhage from the Superior Longitudinal Sinus without Fracture of the Skull; Operation and Recovery.*

By E. Farquhar Buzzard, M.D., and Joseph Cunning, F.R.C.S. *Read March* 9, 1906.

On April 1, 1905, a man, æt. 25, slipped and fell on the back of his head, inflicting a small scalp wound, which was dressed a few days later in the casualty room of the Royal Free Hospital. On the 14th he came to the hospital again, complaining of constant and increasing headache since the accident, and was seen as a medical out-patient. The scalp wound was clean and perfectly healed, and palpation of the skull revealed no lump, depression, or other abnormality. The headache was general, not limited to one side or any particular locality, and was not associated with any cranial tenderness. Examination of the function of the cranial nerves failed to show any alteration from the normal; the pupils were equal and active; there was no ocular palsy, nystagmus, hemianopsia, or optic neuritis. The power in all the limbs was unimpaired and co-ordination was well preserved. No disorder of sensation could be elicited anywhere on testing. It was noted, however, that the abdominal reflex on the left side was absent, that the left knee-jerk was more brisk than the right, and that an extensor response was obtained on stimulating the sole of the left foot. A tentative diagnosis of intra-cranial abscess was made and the patient was recommended for admission into the hospital. He did not come into the hospital until two days later, and in the meanwhile he had experienced several attacks of vomiting and had noticed some paresis of the left hand and the left leg.

On admission his state had altered considerably. He was rather drowsy but could be roused; his breath was offensive and his tongue was furred; his pulse varied between 60 and 70 and his temperature was generally subnormal. The headache was very intense, radiating from the back of the head and spreading over the vertex, more especially on the right side. Vomiting of the cerebral type took place at intervals. The urine was alkaline and gave a heavy deposit of phosphates but contained no albumen. There was now distinct

hemiplegia involving the lower half of the left side of the face, the left arm, and the left leg. Sensation was impaired over the left forearm and fingers and over the lower part of the left leg. An exaggerated knee-jerk, ankle-clonus, and extensor plantar response were obtained on the left side and the left abdominal reflex could not be elicited. There was no optic neuritis. On the 18th the patient was much more drowsy and examination revealed left hemiplegia, hemianæsthesia, and hemianopsia. Still there was no optic neuritis.

An exploratory operation was decided upon and was undertaken at 6.30 p.m. After the scalp had been shaved and cleansed, the upper end of the fissure of Rolando was marked by a small nick in the skin at a point half an inch behind the centre of a line joining the glabella with the external occipital protuberance. A large flap of scalp was turned down and the greater part of the bone covering the parietal lobe was exposed. A trephine opening one inch in diameter was made at a spot about one and a half inches below the mid-line and an inch behind the fissure of Rolando, and this opening was enlarged with Hoffmann's forceps. The skull was at least a third of an inch in thickness and was very tough. The bulging dura mater was of a dark purplish colour, which was found by incision to be due to a large mass of blood-clot lying on its internal surface. A considerable part of this clot was brownish in hue and gave evidence of having been present for at any rate some days. With the possibility of the source of the hæmorrhage being the middle meningeal artery in view, the opening in the skull was enlarged in a downward and forward direction, but during a pause in this undertaking the clot was removed from beneath the dura mater with a finger. Contrary to expectation, the fresh hæmorrhage which ensued came from the direction of the superior longitudinal fissure. The skull opening was accordingly enlarged upwards until the superior longitudinal sinus was exposed and found to be bleeding freely into the subdural cavity. The dura mater having been split up to the bleeding point, four pairs of Spencer Wells forceps were applied and gauze was packed round them. The latter manipulations were necessarily hurried owing to the condition of the patient's pulse, which had become increasingly rapid and feeble with the severe and continuous hæmorrhage. For the same reason no exact view could be obtained of the bleeding point, hence the necessity for several forceps and for leaving them *in situ*. While the dura mater and the scalp were being stitched an

assistant infused three pints of warm saline solution containing a drachm of brandy into the right median basilic vein. On the following morning the patient was conscious, but he complained of considerable pain. The hemiplegia, hemianæsthesia, and hemianopsia were still marked, and conjugate deviation of the eyes to the left was impaired. The pulse was 88, and the temperature between 99° and 100° F.

On the 20th the forceps and plugging were removed without any recurrence of hæmorrhage. No improvement had taken place in the condition of the left limbs, and it was noticed that the patient had complete loss of sense of position of them. On the 22nd improvement in the hemiplegic and hemianæsthetic condition was noted, and this steadily progressed. Fourteen days after the operation the patient was allowed to get up, and a fortnight later he was sent to a convalescent home, still exhibiting slight weakness and clumsiness in the left arm and hand. Since that time all has gone well, and his recovery has been complete.

The case is one of considerable interest for several reasons: (1) The occurrence of hæmorrhage from the superior longitudinal sinus without fracture of the skull may be attributed to the tearing away of a tributary vein from its junction with the sinus at the time of the accident. The unusual thickness of the skull was probably a causative factor by reason of its deficient elasticity. (2) The slow development of the symptoms may be explained by the fact that the hæmorrhage was a venous one, taking place from a small point and against the normal intracranial pressure until the skull was opened at the time of operation, when the bleeding rapidly assumed alarming proportions. (3) The long period, four days, which elapsed between the operation and the improvement in the hemiplegic state was probably due partly to the interference in the functions of the cortex caused by the preceding compression and partly to an extensive œdema of the brain-substance, resulting from the relief of pressure and from the extremely anæmic condition of the patient. (4) The diagnosis of cerebral abscess was one which appeared to be best justified and one which would probably be made in any similar case in spite of the fact that optic neuritis was not present. A gradually progressive hemiplegia associated with hemianæsthesia and hemianopsia, and unaccompanied by anything in the nature of convulsions, pointed strongly to the presence of a deep abscess exerting pressure upon the

optic radiations and internal capsule. The absence of convulsions must be attributed to the very slow accumulation of blood upon the surface of the brain in contrast to the more rapid hæmorrhage which obtains in cases of arterial rupture. (5) Lastly, the importance of a careful examination of the nervous system in a patient complaining of nothing but a headache following a slight injury to the head, and the absolute reliance which can be placed upon the discovery of an extensor plantar response and of the absence of the abdominal reflex on one side as evidence of an organic lesion, are well emphasised in the history of this patient.

Although we have searched the medical and surgical literature of the subject, we have been unsuccessful in tracing any similar case of hæmorrhage from the superior longitudinal sinus without fracture of the skull.

XXIII.—*An Unusual Case of Dilatation of the Stomach following Hour-glass Contraction.* By JOHN EVAN SPICER, M.B., introduced by PERCY KIDD, M.D. *Read March* 9, 1906.

PHŒBE B., a general servant, æt. 37. According to the history given by the patient she had suffered from "indigestion" more or less continuously for twenty years, that is to say since she was about sixteen years of age.

She was frequently under treatment, and on several occasions was told that she was suffering from "gastric ulcer."

In the year 1890, after a period of extra severe pain in the abdomen, she vomited up a large quantity of dark red blood. She was treated at home by her private doctor and quickly improved. But the dyspepsia recurred after a brief interval and continued with varying degrees of severity until three years later, when she had her second attack of hæmatemesis. She was again treated at home, but quickly relapsed, and eight months afterwards (on October 20, 1893) she was admitted to St. Thomas's Hospital.

The hospital records state that she was suffering from very severe pain in the chest and abdomen of some months' duration. This pain was invariably provoked by taking food, and lasted for about an hour, there being at the same time a feeling of distension in the stomach, but no vomiting. Hæmatemesis did not occur while patient was under observation. Gastric ulcer was suspected. With rest, careful diet, and bismuth a rapid improvement took place. But relapse after relapse followed. Four or five years ago a third hæmatemesis occurred.

In September, 1905, the patient attended at the London Hospital Out-Patient Department. At that time she was suffering from epigastric pain ensuing immediately after food, and from vomiting which considerably relieved the pain. The abdomen was tender, and splashing could easily be obtained. Again the condition improved under treatment, and the patient remained practically well until February, 1906.

On the evening of February 12, 1906, after going to bed, the patient was suddenly seized with a severe pain in the

epigastrium and across the back. It seems to have borne no relation to food, but was followed in a few hours by vomiting, the vomit being green. There was no hæmatemesis.

For four days the pain and vomiting recurred at intervals before the patient presented herself for treatment at the London Hospital. She walked up to the hospital and did not look very ill, but she was admitted under the care of Dr. Percy Kidd. She complained of but little pain, her temperature was normal, her pulse 108, and the tongue moist and clean. But on examination of the abdomen a soft fluctuating tumour was found occupying the whole central region, and

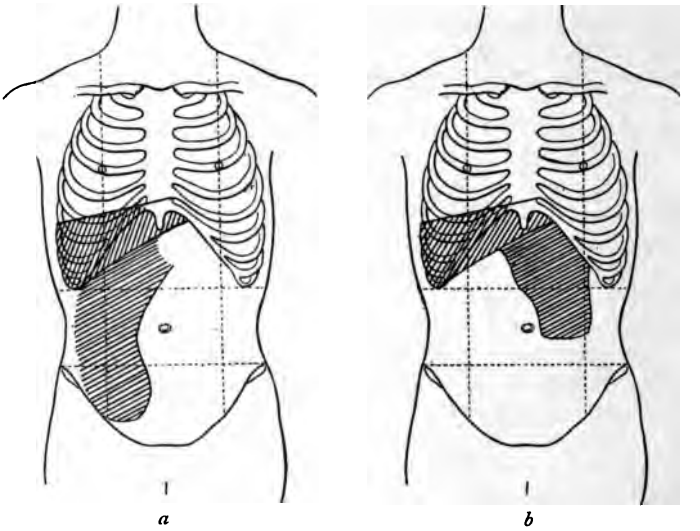

a *b*

FIG. 9.

extending almost to the pelvis on the right of the middle line. When the patient lay on her back the abdomen was resonant all over, but on turning her to either side an area of deep dulness appeared towards the corresponding flank (see Fig. 9, *a*, *b*). This "shifting dulness" was not that of free fluid in peritoneum, but appeared to be due to a localised and more or less movable fluid swelling. The latter certainly did not arise from the pelvis and could not be felt *per rectum*.

A fluid thrill and definite splashing were easily obtained, while at times during examination the tumour could be felt to harden up under the hand, as though a peristaltic wave were passing through it. On auscultatory percussion the

stomach note appeared to extend over the region of the tumour. There was no evidence of peritonitis. Examination of the urine showed the presence of a trace of albumen, but nothing else of importance.

The liver dulness was quite normal, the spleen not enlarged, and the heart and lungs sound.

The bowels had been freely opened shortly before admission after a period of four days' constipation.

A diagnosis of dilatation of the stomach was arrived at.

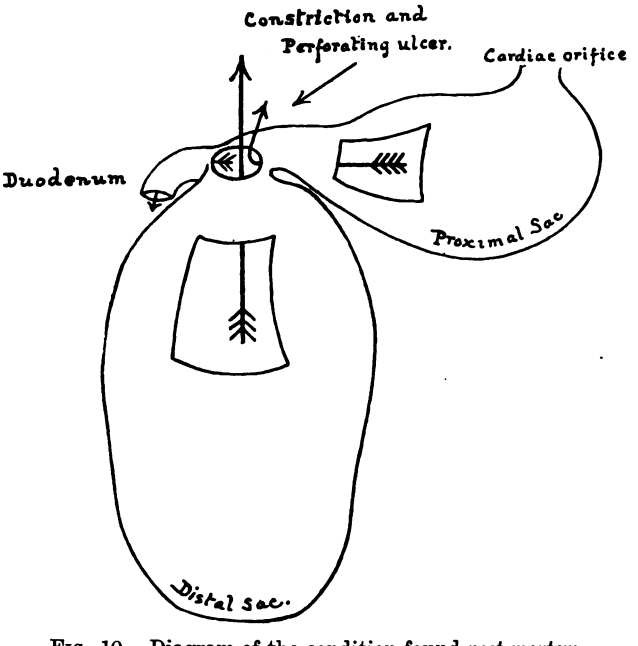

FIG. 10.—Diagram of the condition found *post mortem*.

Very little pain was complained of, but during the following day the patient vomited three or four times, a few ounces only at a time and of a greenish-yellow colour. There was no free HCl in the first specimen tested and it did not ferment on standing. In the evening an œsophageal tube was passed and the contents of the stomach drawn off. Only half a pint of fluid was found in the stomach and this of a dark-green colour resembling spinach. It contained free HCl.

The stomach was washed out with a weak solution of sodium bicarbonate in warm water. The lavage caused no

pain and the patient said she felt more comfortable after it. But it had no effect on the abdominal tumour either in increasing or decreasing its size.

A fairly good night followed and during the next day there was no vomiting at all and little pain.

Towards evening, however, the patient grew restless and the pain worse, and in the middle of the night she suddenly became "collapsed."

From this moment the pain entirely left her, the temperature fell, the pulse became rapid and feeble, the abdomen distended, tender, and immobile, and the symptoms of general peritonitis set in.

Three hours later the patient died.

Post-mortem examination.—On opening the peritoneum gas escaped. The peritoneal cavity contained between two and three pints of thick green fluid resembling liquid spinach which was oozing from a perforated gastric ulcer. The stomach (see specimen) was found to be "hour-glass" in shape. The proximal cavity (describing the conditions from the cardiac opening of the stomach to the duodenum) was much the smaller and contained about 10 oz. of partly digested milk. The constriction was due to scarring around an old ulcer situated at the pyloric end of the stomach close to the duodenal opening and apparently on the anterior surface. The passage admitted one's first finger only up to the middle joint. The ulcer was of a very chronic type and lay towards the distal end of the constricted portion. In its centre was a perforation, in size rather less than that of a threepenny-piece, with thick rounded edges. It had been closed over by a thin lip of the left lobe of the liver. The adhesions between the two had only recently been separated. An irregular cavity bounded by old adhesions of gastro-hepatic omentum to the under-surface of the liver was found extending up under the liver in direct communication with the ulcer, and at its extreme apex, wedged in under the liver, was an orange pip. The distal sac was much larger than the proximal and contained several pints of thick green fluid such as was found in the peritoneal cavity. Its axis lay roughly at right angles to that of the proximal cavity, with the perforation on the anterior wall of the connecting passage. The opening into the duodenum was found in the outer wall of the angle and admitted the little finger, as also did the mouth of the distal cavity. There was a slight hyperæmia only of the peritoneum.

XXIV.—*A Case of Associated Congenital Malformations, including Transposition of Viscera.* By A. E. Garrod, M.D., and F. Langmead, M.D. *Read March* 9, 1906.

THE case was that of a female infant, æt. 9 months, who was admitted into the Hospital for Sick Children, Great Ormond Street, in June, 1905, for constipation and wasting. From the mother we gathered that the child, when twenty-four hours old, had been operated upon for an imperforate anus, and that since then she had never thrived. Various foods had been tried, but nothing seemed to suit her. There had been no vomiting, no diarrhœa, and no fits. There was nothing more striking in the ante-natal history than that the mother had been in poor health during the last few months of pregnancy. The patient was the fifth of five children, of which the first was stillborn. Between the third and fourth children there had been a miscarriage. The patient was born at full term. There was no blood relationship between the parents.

On examination the patient was found to be a badly nourished, ill-developed child weighing seven and a half pounds and measuring twenty-two inches in length. She was pale, but showed no cyanosis or clubbing of the fingers. There were many features about her characteristic of the Mongolian type of idiocy. The face was flat, the eyes aslant, and the tongue, which was very long and pointed, was continually protruding from the mouth. The nose was broad and stunted, the hair thin, short and wig-like, and the lips thick. The epicanthic folds were well marked. The little fingers showed to a slight extent the incurving described by Dr. John Thomson. An important deviation from the strict type lay in the back of the head, which was not flat as usual, but sloped steadily towards the occiput. A small umbilical hernia was present. About the anus were the scars of the previous operation, which had provided a passage into the rectum, easily admitting a finger. Inspection of the chest revealed pulsation in the fifth and sixth interspaces just to the right of the sternum, and further examination showed the maximum impulse to be in the sixth space, half an inch to the right of that bone. A systolic murmur was heard, blowing in character,

and of about equal intensity at the normal mitral and aortic areas, and behind the sternum. It was also distinctly heard over the back. No thrill was felt. The cardiac dulness ended

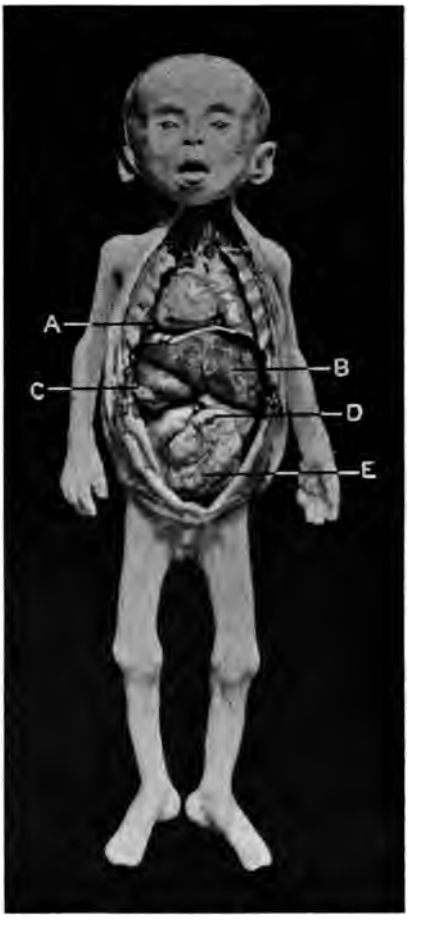

FIG. 11.—Showing malposition of viscera. A. Heart. B. Liver. C. Stomach. D. Cæcum. E. Sigmoid flexure.

to the right at the right nipple line, to the left at the mid-sternal line, whilst above it appeared to end normally. On abdominal examination the liver was easily made out pro-

jecting below the left costal margin. The spleen could not be felt. A skiagram plainly showed the alteration of position of the liver and heart. No other abnormality could be made out. The child had an acute attack of diarrhœa, wasted rapidly, and died ten days after admission.

Post mortem.—The diagnosis of complete transposition of viscera, associated with congenital heart disease, which had been made during life, was verified. The heart lay with its apex over to the right of the chest, with its right ventricle as usual in front, but with its apex formed by the left. The relation of the trunks of the great vessels to one another at their origins was normal, but the aorta curved so as to descend to the right of the vertebral column instead of to the left. The innominate artery was to the left, whilst the subclavian came off independently on the right side. The right auricle and ventricle were much more capacious than the corresponding cavites on the left side, but the walls on both sides were a good deal thickened. At the undefended spot was a perforation just large enough to admit a probe, which was screened over by the septal mitral flap, slightly thickened and puckered. The foramen ovale was patent, the interauricular septum being only represented by a single strand. The ductus arteriosus admitted a knitting needle. Otherwise the heart was normal.

The lungs presented only two lobes on each side, the upper lobe on the right side being absent.

The right lobe of the liver, with the gall-bladder, was on the left side of the abdomen, the left lobe, which was somewhat larger than usual, lying well over to the right. Behind the left lobe and completely hidden from view was the spleen, a small organ, little larger than a walnut. The stomach was also small and when inflated could be seen below the left lobe of the liver, the pylorus being about in the mid-line. The duodenum ran almost directly backwards, ending to the right of the vertebral column at the duodeno-jejunal flexure. In the loop of the duodenum lay the head of the pancreas, its body and tail being directed upwards and to the right to reach the spleen. The cæcum was situated just to the left of the middle of the abdomen, its blind end being directed upwards and to the left and the appendix vermiformis projecting from it across the mid-line to the right. The colon first ran downwards and to the right, then bent sharply upwards to the left, and finally descended in the right loin. The loop of the sigmoid flexure lay to the left. The rectum

began to the right of the sacrum. No deficiency of convolutions or other change could be made out in the brain. No other abnormality was found.

Remarks.—It must be acknowledged that the interest which attaches to this case is teratological rather than clinical. In it we find associated four distinct congenital malformations, viz. imperforate anus, a congenital heart lesion, complete transposition of viscera, and idiocy of the Mongolian variety. Of these the two first are definitely malformations by arrest, none of them are malformations by excess.

The association of congenital heart disease with other malformations is sufficiently common, and it is worthy of note that in the present instance the murmur was clearly due to the defect of the auricular septum. In some instances the cardiac lesion met with in such association is not an anomaly by arrest, but is one of those which have been ascribed with some show of reason to the occurrence of fœtal endocarditis—such, for example, as stenosis of the pulmonary orifice due to fusion of the valve flaps into a cone. It may be that, as Rokitansky suggested, a primary malformation predisposes to fœtal endocarditis, for there is certainly evidence to show that malformed valves have some special liability to the post-natal lesions of ulcerative endocarditis.

Transposition of viscera is not infrequently associated with other malformations; and in a paper written by one of us, eleven years ago, several cases were quoted from the literature in which transposition was accompanied by other malformations in addition to congenital heart lesions; among these were examples of hare-lip, absence of spleen, and that commonest of all malformations, multiple spleen.*

In conclusion, this case affords an example of an association of a quite special frequency, viz. that of congenital cardiac lesions with the form of idiocy known as the Mongol or Mongoloid variety.

Attention was directed to this association by one of us in a paper read before the Clinical Society in 1899, and the observation has been confirmed by a number of other observers. It is in the out-patient departments of children's hospitals that this association is best seen, for children who exhibit it very seldom survive the first year or two of life, and in asylums it is seldom observed among Mongolian idiots who have passed the age of five years. Fennell, however,†

* *St. Bartholomew's Hospital Reports*, vol. xxx, 1894, p. 53.

† *Lancet*, vol. ii, 1903, p. 1650.

records three instances among twenty-three such idiots at Darenth. Only in the shape of the back of its skull did the infant which forms the subject of this paper depart from the characteristic Mongol type, but we are inclined to think that the long-headed sub-variety is a distinct and not very rare one.

XXV.—*Treitz's Hernia complicating Gastro-Enterostomy.* By Arthur E. Barker, F.R.C.S. *Read March* 30, 1906.

THE comparative rarity of this form of intra-abdominal hernia, and the fact that it was encountered in an operation undertaken in the hope of relieving pyloric stenosis by gastro-enterostomy, justify a short description of it as far as it was seen.

Some time ago I was called to a great distance to operate on a gentleman, æt. 56, for carcinoma of the pylorus of long standing. The most marked symptom was intense irritability of the stomach, so that even the smallest quantities of fluid were rejected almost at once. There was obscure resistance over the pylorus; otherwise the abdomen appeared normal to palpation and inspection.

On opening the abdomen by a median incision above the navel, the pyloric growth was easily seen. It involved all the distal end of the stomach and infiltrated the greater curve. On raising the great omentum, which was loaded with fat in two large thick rolls, the transverse colon was found far less mobile than usual. The stomach also could not be pulled forward. As I contemplated a retro-colic gastro-enterostomy it was first necessary to ascertain whether the infiltration of the great curvature involved the posterior surface of the organ. This could only be made out by examination through the gastro-colic omentum or the transverse meso-colon. As the first way was difficult owing to the shortness of the gastro-colic omentum, I selected the second; but to my surprise on looking at the meso-colon I could see no small intestine, and the inferior leaf of the meso-colon was bulged forwards, starting from the actual colon. Enlarging the abdominal incision and looking into each side of the abdomen and down towards the pelvis while the walls were pulled forwards, I could see a perfectly normal parietal peritoneum and the small intestine covered everywhere by a second layer of serous membrane—in other words, that all the small gut was included in a retro-peritoneal sac. This was opened by a transverse slit for about three inches,

two and a half inches from the colon, where the small intestine in a perfectly normal condition was seen and the usual spot for anastomosis was selected. But from this opening the posterior wall of the stomach was felt indurated and immovable. The hand passed along its anterior surface to the left felt also a mass which appeared to unite the cardiac

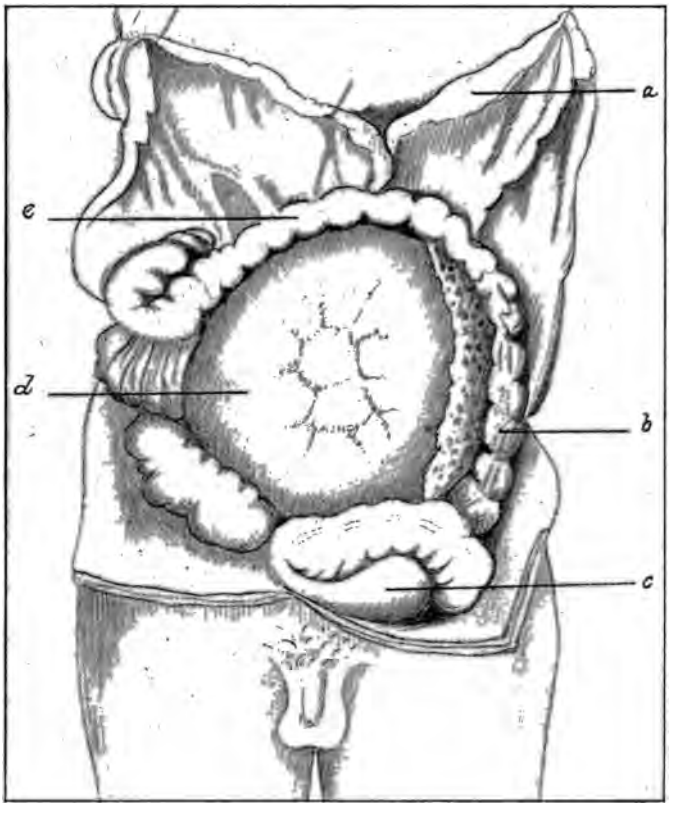

FIG. 12.—*a*. Omentum. *b*. Descending colon. *c*. Junction of sigmoid and rectum. *d*. Anterior wall of sac.

end with the ribs and splenic flexure. As there appeared therefore to be no place on the posterior surface sound enough for a junction with the jejunum, and as the anterior surface was doubtfully sound also, and as moreover a loop of the small intestine would have to be drawn through the slip in

the hernial sac if an anterior gastro-enterostomy were to be done, I gave up the thought of any anastomosis and closed the slit in the sac by continuous suture and then the abdomen.

The appearance of the parts on opening the abdomen was usually that depicted in Fig. 12, which is the illustration of Treitz's fifth case given in Jonnesco's monograph on the subject.

In this particular case, owing to the extent of the cancerous infiltration, it is evident that no effectual gastro-enterostomy would have been possible. But it was also clear that in a similar case with carcinoma limited to the pylorus such a hernia would have seriously complicated the operation. In the first place, as the hernia had separated the two leaves of the transverse and descending meso-colon, the large gut was thereby fixed and could not be thrown up so as to get at the posterior surface of the stomach. Two courses would then be open to the operator—either to do an anterior gastro-enterostomy through a large slit in the sac, risking a constriction in the slit, or to pass the hand down to the cæcum and withdraw all the small intestine before making the posterior or anterior anastomosis with the risk of a return of the hernia to the sac unless the opening of the fossa duodeno-jejunalis were stitched up, a very difficult proceeding. On the whole, however, I think that the latter would be the best course to take. I am confirmed in this opinion by a careful perusal of Jonnesco's admirable monograph on retro-peritoneal herniæ, for the opportunity of perusal of which I am indebted to my colleague Professor Thane. In it there is a complete collection of all recorded cases, copiously and well illustrated. The variety met with in the above case appears to be the most common. But in reading Treitz's cases, eight in number, one cannot but reflect that at any time one may be confronted by a condition seriously complicating an otherwise very difficult operation. Personally I have only met with the condition twice (one being a doubtful case) in a large number of abdominal sections. The first was strangulated, the second (the present case) not strangulated, but none the less embarrassing on that account in this particular instance. The more frequent exploration of the abdomen nowadays will probably bring more of these cases to the front, but every surgeon will hope that it may not be his lot to meet with the condition in the course of a gastro-enterostomy.

XXVI.—*A Case of Right Duodenal Hernia in which the Hernia was reduced but Death followed in seven Days, due apparently to Gut re-entering the Sac.* By E. Percy Paton, M.S., F.R.C.S. *Read March* 30, 1906.

B. P., a female infant æt. 3 months, was admitted into Westminster Hospital under my care on September 2, 1904. The child was sent up to the hospital by Dr. Norman, of Brixton, with a history of only a few hours' duration of vomiting and apparently abdominal pain. There had been no definite passage of blood and mucus *per anum*, and a definite swelling had been felt in the abdomen.

On examination immediately after admission the infant was found to be somewhat collapsed, but not very markedly so; there were no physical signs of importance apart from the abdomen, which was full, but not distended, and seemed somewhat tender to the touch. No definite tumour could be felt, though there was a suspicious fulness in the hypogastric region. Rectal examination revealed nothing abnormal. Dr. Norman had diagnosed the case as one of early intussusception; and as the symptoms were in agreement with this view and the child was clearly suffering from some acute intra-abdominal trouble, with some obstruction, it was decided to open the abdomen to clear the matter up. This was done at once, a small opening being made in the linea alba immediately below the umbilicus. A loop of gut was at once encountered which passed from left to right, under what was at the time taken to be a band extending from the region of the transverse colon to the right side of the pelvis. The gut was only loosely engaged under the supposed band, and without any difficulty about a couple of feet or possibly more of intestine were drawn out until all seemed free. It was now proposed to investigate the nature of the band, but the general condition of the infant made it necessary to complete the operation without delay and as the "band" was broad in character and it seemed impracticable to divide it with safety as its connections could not be clearly made out, the abdomen was closed at once without further investigation.

The general condition of the child was immediately greatly improved, and in two days' time she seemed to be

progressing rapidly towards recovery. This condition of matters continued till the sixth day, when vomiting returned, which was speedily followed by profound collapse, and the child died on the seventh day after the operation.

FIG. 13.—A. Liver. B. Colon. C. Appendix. D. Mesentery. E. Entrance into sac. F. Margin of neck of sac containing termination of superior mesenteric artery. G. Cæcum. H. Small intestine. In this figure the small intestines have been turned over to the right side, exposing the left side of the mesentery.

At the *post mortem* nothing abnormal was found outside the abdomen. The peritoneum showed no signs of inflammation. On turning the small intestines over to the left side there was to be noticed on the right side of the mesentery a

swelling about the size of a tangerine orange, but rather more oval in outline (Fig. 14). This swelling clearly lay mostly in the root of the mesentery and was surrounded above, to the right, and below, by the transverse and ascending colon and the cæcum. On shifting the small intestines to the right side an aperture at once became visible in the front of the mesentery (Fig. 13). This opening had a thin, sickle-shaped anterior border, in which lay the superior mesenteric artery, continuing on to its ileo-colic branch; its posterior boundary was formed by the peritoneum covering the posterior abdominal wall. The opening thus formed would easily admit two fingers. Tracing up the intestine from the ileo-cæcal valve at a spot about eighteen inches from the duodenal junction, it was found to disappear through the opening which has just been described, very gentle traction upon the entering loop readily disengaged it, and eighteen inches were very easily drawn out. The loop of gut thus withdrawn from the sac was not distended nor congested nor did it show any other sign of strangulation. On examination of the interior of the sac its posterior wall was found to consist mainly of the peritoneum lining the posterior abdominal wall on the right side, being continuous at the aperture with the peritoneum lining the left side of the posterior abdominal wall. This description, however, does not completely indicate the arrangement, as at the upper part the peritoneum forming the sac had somewhat encroached on the anterior aspect of the duodenum, which, therefore, also formed part of its posterior wall, with, of course, an intervening layer of peritoneum. There seemed to be also some extra adhesion of the first part of the jejunum to the posterior abdominal wall, as has been described by Moynihan to occur in some similar cases.

The sickle-shaped edge bounding the anterior part of the mouth of the sac was clearly the "band" under which at the time of the operation it was supposed that the intestine had slipped, and although all the intestine had apparently been withdrawn from the sac it appears to have speedily returned again, though in view of the fact that it showed no signs of being strangulated it is doubtful why this should have given rise to the severe symptoms and ultimate death of the child.

Right duodenal herniæ seem to be very rarely met with, and Moynihan in his monograph on retro-peritoneal herniæ was only able to collect records of fourteen cases. The condition appears to be the result of a gradual distension of the

fossa of Waldeyer, a depression which is not infrequently found at the root of the left side of the mesentery, though it is by no means constant. The most characteristic anatomical feature of this variety of hernia is the presence of the superior

FIG. 14.—Lettering as in Fig. 13, but K, sac. In this figure the small intestines have been turned over to the left side, exposing the right side of the mesentery.

mesenteric artery forming the anterior boundary of its neck. For though this artery does not normally form the anterior boundary of the fossa of Waldeyer, when this fossa is dilated by gut the mesentery rapidly gives way before the intestine distending it, until the resistant artery is reached, which

succeeds in preventing any further enlargement of the opening, and, therefore, in those cases which become strangulated it is the main cause of the strangulation, a most important point, for any attempt to divide the constricting band would almost inevitably sever this artery, with clearly the most disastrous results. In most instances, however, if the condition has been recognised it does not seem to have been a very difficult task to disengage the bowel, which has, however, as in my case, shown a very strong tendency to return to the sac. It might be thought that this recurrence could be prevented with success by suturing the neck of the sac; but though I am not aware if this has been done in a right duodenal hernia, attempts of a similar sort in other retroperitoneal herniæ do not seem to have met with much success, as no obliteration of the sac has occurred, and the stitches which have been put in seem soon to have become loose and ceased to serve the purpose for which they were intended.

XXVII.—*Large Cyst of Common Bile-Duct.* By Frederic Eve, F.R.C.S. *Read March* 30, 1906.

MARIA P., æt 46, was transferred from the medical side to my wards at the London Hospital on March 29, 1903.

History.—She had suffered somewhat from indigestion and flatulence for some years. Jaundice came on three years ago, and has continued with occasional variations, but on the whole has increased. She was admitted to the hospital in the spring of 1902, for an abdominal tumour with jaundice, and was readmitted in November, 1902.

Present condition.—Her general condition and nutrition are fair. The jaundice is moderate in intensity. No constipation or vomiting, but the motions are light in colour. No wasting. Urine natural except for the presence of bile. Temperature low and irregular, 97° F.—98·6° F.

The whole of the right side of the abdomen is occupied by a tumour which extends from the right costal margin downwards to the crest of the ilium and obliquely across the abdomen to the left side of and below the umbilicus. The swelling is distinctly elastic, dull to percussion, the dulness being continuous above with the hepatic area. There is resonance in the right flank behind the tumour, which moves slightly on respiration. Just below the costal margin a smaller, movable tumour overlies the larger one. Pelvic viscera natural. Some leucocytosis.

Diagnosis.—A cystic kidney was excluded by the position of the colon, which was pressed outwards and backwards. Hydatid of the liver seemed improbable owing to the presence of leucocytosis; and the symptoms which would accompany suppuration of a hydatid cyst were absent. There was also no eosinophilia. By process of exclusion, and owing to its relative fixity, it seemed likely to be a cyst of the head of the pancreas pressing on the common bile-duct.

Operation April 3, 1903. The abdomen was opened through the outer part of the right rectus. A large retro-peritoneal cyst was exposed with the gall-bladder, bent upon itself, lying in front of it. The cyst was tapped and then opened; it contained clear fluid mixed with thick green mucoid material and a few small dark pieces of grit. As

it was emptied the gall-bladder became flaccid. The cyst wall, which was of the thickness of an abdominal aorta, was sewn to the peritoneum and abdominal aponeurosis and a large drainage-tube packed with gauze was inserted. The amount of fluid removed at the operation was roughly 148 ounces. An analysis of the fluid by Dr. McLeod showed that it contained bile-pigments and salts, mucin, and a trace of heat coagulable proteid. After the operation pure bile drained freely from the cavity. The patient recovered well from the operation and left the hospital seven weeks after with a fistula from which great quantities of bile-stained fluid were discharged.

On June 10 the patient was readmitted on account of the soreness and inconvenience resulting from the constant discharge of a large amount of fluid from the fistula.

To relieve her condition I decided to make a communication between the dilated duct and the colon. This operation was performed on June 26. On opening the cyst through the old scar it was found that the cyst wall had not contracted to the extent that had been hoped for; the cavity contained a large quantity of decomposing bile and was thoroughly washed out. The peritoneum was then opened, the colon found, and a lateral anastomosis between the hepatic flexure and the dilated duct was performed by stitching. A drainage-tube with silk thread attached was placed in the opening, the thread being brought out through the abdominal wound, which was partly closed. The patient did fairly well for the first week, there being no abdominal distension nor vomiting. Pulse 90 to 100 and temperature 97° F. to 99° F. The tube lying in the communication between the cyst and intestine was removed on the fourth day. There was considerable passage of fæces through this opening into the cyst and through the external wound. It was in anticipation of this difficulty that the external wound was left open in order that the cyst might be flushed until it contracted. After a week the patient became feebler, pulse weak, extremities cold, but the pulse and respiration never quickened and there were no abdominal symptoms and no fever. She gradually failed and died fourteen days after the operation.

Autopsy.—The heart was very fatty, the muscular substance being reduced to a thin layer.

Abdomen.—No sign of peritonitis or other morbid condition, with the exception of the cyst. The union between the colon and the latter was firm.

The cyst was removed, together with the stomach, duodenum, pancreas, portions of the liver and ascending colon, and the subcutaneous tissues which formed the wall of the biliary fistula, these organs being preserved for subsequent dissection.

Description of cyst (Pl. VII).—The cyst has a dense fibrous wall, varying from $\frac{1}{16}$ to $\frac{1}{8}$ inch in thickness, its greatest diameters being as follows: transverse $4\frac{1}{2}$ inches, vertical 4 inches, antero-posterior 3 inches. It occupies the whole length of the common bile-duct.

Relations.—Above is the liver (portions of right and left lobes). In front are the gastro-hepatic omentum, the pyloric end of the stomach, the duodenum, and the head of the pancreas. On the outer side lies the ascending colon.

The internal portion of the cyst projects into the lesser sac of the peritoneum, and posteriorly it was adherent to, and had to be dissected off, the posterior wall of the abdominal cavity.

Behind the cyst, and nearer to its inner than its outer border, are the hepatic artery and the vena portæ.

Above the middle point of its upper border, closely bound down between the cyst and the liver, is the tip of the shrunken and contracted gall-bladder.

Interior of cyst.—At the outer (right) part of its upper border is the remains of the fistula which communicated with the outer surface of the anterior abdominal wall.

On its outer wall, inferiorly, is the anastomotic communication with the ascending colon—an orifice which just admits the first joint of the index finger.

At the inner (left) portion of the upper border are three orifices, each of which just takes the tip of the little finger, and into each of which a probe can be passed for about an inch; these represent the dilated cystic and right and left hepatic ducts.

On the posterior wall of the cyst, near its lower margin, is a papillomatous growth. Its base is about half an inch in diameter, and it extends for about two thirds of an inch into the interior of the cyst, expanding slightly.

The base of the papilloma corresponds to a point on the wall of the cyst about one inch above the papilla biliaris. From the papilla a fine probe can be passed with ease, travelling upwards for about one inch, and entering the cyst just on the inner (left) side of the base of the papilloma. There seems no doubt that during life the projecting portion

DESCRIPTION OF PLATE VII.

Illustrating Mr. Frederic Eve's Case of Large Cyst of Common Bile-duct.

a. Cyst. *b*. Pyloric end of stomach. *c*. Duodenum. *d*. Hepatic flexure of colon. *e*. Gall-bladder. *f*. Rod passed through anastomosis between the cyst and colon.

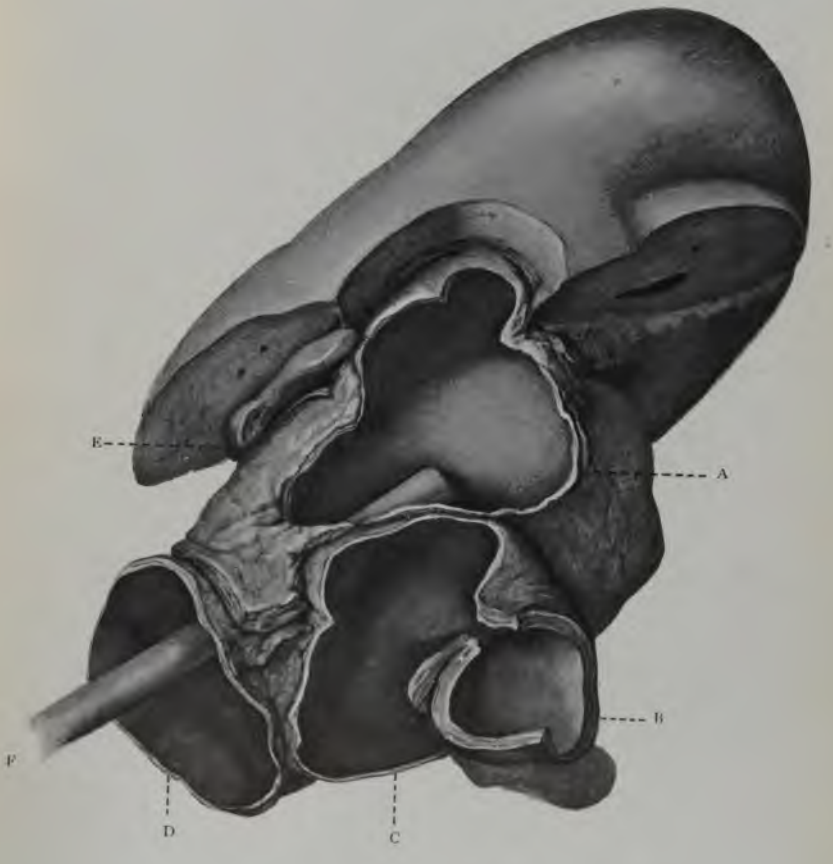

Bale and Danielsson, Ltd.

of the papilloma acted as a valve and prevented the passage of bile into the duodenum. Microscopically, the tumour was a papilloma (Fig. 15).

I am much indebted to the late Dr. Slade for making the post mortem and for the description of the cyst.

Remarks.

It is very rarely that a diagnosis of the condition under consideration has been arrived at before the cyst has

Fig. 15.—Microscopic section of papilloma obstructing the orifice of the common bile-duct. The growth is composed of delicate papillæ lined with columnar epithelium.

been opened. The cyst has usually been mistaken for a greatly dilated gall-bladder or for a cyst of the head of the pancreas. This is not surprising seeing how much the neighbouring structures are displaced. The contents are almost invariably mucus; but this may be slightly stained with bile, or contain green, gritty material. In Edgeworth's case, however, the cyst contained normal bile. A fistulous communication had in one case (Barlach's) been established with the stomach and in another with the gall-

bladder. The onset of symptoms is usually slow and gradual, but in Russell's case, a boy æt. 8, the patient had only been ill for five days. Jaundice is of necessity a constant symptom.

Cystic dilatation of the common bile-duct does not appear to be exceedingly rare, for in a somewhat cursory examination of the literature of the subject I have found twenty-four cases.

Dr. Todd appears to have recorded the first case in 1817, and the second was described by Dr. Douglas in 1852.

Todd's patient was a girl æt. 14; the common and hepatic ducts formed a cyst reaching from the liver to the sacrum; it lay behind the duodenum, pancreas, and root of mesentery. The cause of dilatation was a "scirrhous state of the pancreas" (chronic pancreatitis).

As regards the causation the cases appear to fall into three groups:

(1) Those in which the obstruction to the common duct is due to the formation of a valvular fold, to stenosis, or to complete obliteration.

In Dr. Ashby's case, occurring in a boy æt. 7, the duodenal end of the duct was obliterated.

M. J. Rostowzew has reported a typical case of occlusion of the duct by a valvular fold; the patient was a peasant maid æt. 13. Enlargement of the abdomen had been noticed for three years and icterus for three weeks before her admission to hospital. The jaundice was not complete and the tumour varied in size. The cyst was opened, fixed to the abdominal wall, and drained. Death took place within twenty-four hours. In the lower segment of the cyst there was a funnel-shaped opening of the size of a lentil. It was overhung by a valve-like fold, so that the opening was absolutely closed when the cyst was full. He concluded that the cyst was due to a congenital abnormality, and that, a dilatation of the common bile-duct having occurred in some unexplained way, the valve-like fold was produced by alteration of the direction of the undilated lower orifice of the duct.

In some instances the obstruction to the duct is stated to have been a congenital anomaly; and the considerable number of cases in which the condition was observed in children, or young persons ranging from the ages of four to fourteen years, lends a certain amount of support to this view. Edgeworth's patient, a girl æt. 4½, developed jaundice at six months of age, and from that time had recurring attacks about every six months.

(2) In a second group of cases, comprising a smaller number, the obstruction was due to a calculus.

(3) In a third group a growth was the cause of the obstruction. My own case reported above is a typical example of this.

In Wilkes and Moxon's cases the cyst, as large as a child's head, was studded with numbers of pedunculated myxomatous growths containing muscle-fibre. The patient, a boy æt. 4, was admitted for enlargement of the abdomen, emaciation, and vomiting, of seven months' duration. The right half of the abdomen was occupied by a fluctuating swelling from which five pints of greenish, purulent fluid were withdrawn.

A primary carcinoma of the common bile-duct may give rise to dilatation above it (Brenner).

Treatment.

In upwards of fourteen cases of cyst of the common bile-duct choledochostomy was performed; or, in other words, the cyst was opened, its walls attached to the parietes, and a drainage-tube inserted.

Among the few survivors one case, operated on by Mr. Mayo Robson, made a perfect recovery. The obstruction was due to stone and, therefore, removable.

In Dr. Ashby's case the patient survived the operation of drainage for two months, but died later of peritonitis, following an abortive attempt to establish a communication between the cyst and the duodenum.

The patient in my own case also survived the operation of choledochostomy for three months.

The operation of draining the cyst into some portion of the intestine has been performed on several occasions.

The first successful case was reported by Sprengel in 1891, and another case was operated on successfully in 1894 by Swain.

A communication has been established between the cyst and the duodenum, the jejunum, and, in my own case, with the colon.

The cyst being usually of large size and the relation of parts much altered, the establishment of an anastomosis between the dilated duct and the duodenum would appear to me to be usually attended with great difficulty and risk.

The simplest and safest procedure is the establishment of an anastomosis between the cyst and the hepatic flexure of the colon.

That the diversion of the bile into the large intestine is not attended by any physiological disturbance has been shown by those cases in which a junction has been formed for other conditions between the gall-bladder and the colon.

Should the state of the parts permit of it, probably the best course would be to effect an anastomosis between a coil of the jejunum and the cyst, as was done so successfully by Mr. Swain.

It may be open to discussion whether it is advantageous to perform a primary choledochostomy, in order to allow the cyst to contract, followed by a junction between the cyst and some portion of the intestine, or whether the latter operation should be undertaken in the first instance.

My impression is that choledocho-enterostomy should be performed at once; for in the case detailed above, although the cyst was drained for three months, yet on opening it to perform the second operation I found that it had not materially contracted. Although in many instances the cystic duct remained patent, yet an anastomosis between the gall-bladder and the bowel would not provide sufficient drainage for the cyst, owing to the circuitous and narrow communication which would exist.

References.

1. Edgeworth, *Lancet*, 1895, vol. i, p. 1180.
2. Todd, *Dublin Hospital Reports*, 1817, vol. i, p. 328.
3. Douglas, *Monthly Journal of Medical Sciences*, February, 1852.
4. Ashby, *Medical Chronicle*, October, 1898, p. 28.
5. Rostowzew, *Deut. med. Woch.*, Bd. xxviii, S. 739, 1902. He also gives three other cases, including Douglas's.
6. Wilkes and Moxon's *Pathology*, p. 485, 3rd ed., 1889.
7. Mayo Robson, *Diseases of the Gall-Bladder*, p. 126, 3rd ed.
8. Swain, W. P., *Lancet*, 1895, vol. i.
9. Sprengel, *Verhandlungen der Deutschen Gesellschaft f. Chirurgie*, Bd. xx, 1891.
10. Oxley, *Lancet*, 1883, vol. ii, p. 988.
11. Russell, *Annals of Surgery*, December, 1897, p. 692.
12. Barlach, *Deut. med. Woch.*, 1876, No. 31.
13. Frerich, *Klinik de Leberkrankheiten*, vol. ii, p. 433.
14. Brenner, *Virch. Archiv*, November, 1899, vol. clviii, Part II, "Primary Cancer of Common Duct with Dilatation."
15. Kocher (quoted by Sprengel *op. cit.*).

XXVIII.—*Three Cases of Gastro-jejunostomy.* By F. C. Wallis, M.B., B.C., F.R.C.S. *Read March 30, 1906.*

THE operation of gastro-jejunostomy is such an every-day occurrence now that unless it was thought that some special point was being brought out one would scarcely be justified in bringing these cases before the Society.

The first case is of sentimental interest in that the patient was a lady, æt. 91, who had lived in five reigns, and remembered being carried in a sedan chair in the Strand.

The other two cases are, I venture to think, of extreme practical interest in that in both cases chronic inflammatory growth around an ulcer simulated carcinoma so closely that the latter diagnosis was made in each instance.

Case 1.—A female patient, æt. 91, whose life history was excellent except for an attack of general eczema twelve years previously; beyond this and occasional bilious attacks she had never had any illness.

At the commencement of 1905 the patient had all the signs of a dilated stomach, vomiting large quantities of fluid which was on various occasions of coffee-grounds character, tenderness over the pylorus, no cachexia, no great loss of flesh.

In March, 1905, Dr. Hale-White saw the patient in consultation with Dr. Grigg, and it was agreed that there was evidently pyloric obstruction, and as the patient was suffering and going downhill, it was decided that, in spite of the great age of the patient, an operation was urgently needed for her relief.

A posterior gastro-jejunostomy was done by me on March 31.

At the operation extensive ulceration and thickening of the pylorus was found, and the liver and pyloric end of the stomach were all matted together. The stomach itself was much dilated.

The patient made a good recovery, and from April to December, 1905, regained weight, had a good colour, and was able to take out-of-door exercise. She could take

her ordinary diet, but, as heretofore, had occasional bilious attacks. At the end of December patient had cerebral thrombosis and died three months later.

Case 2.—A male patient, æt. 57, was admitted to Charing Cross Hospital on December 4, 1905, suffering from gastric pains. The pain came on about four months previous to admission. It was of a sharp, shooting character, always starting in the same place and radiating across the abdomen. The pain became more and more severe and lasted for longer

Fig. 16.

periods, much worse after food, always bad at night, keeping him awake.

No vomiting and no nausea, considerable loss of weight, and great tenderness on pressure over the stomach region. The patient was profoundly anæmic.

Operation (December 11).—When the abdomen was opened and the stomach pulled forward a large growth was exposed (see Fig. 16), involving the lesser curvature and extending to the pylorus, but not to the cardiac end. It was thought that the growth could be removed, but having regard to the general condition of the man, it was considered best to do a gastro-jejunostomy now, and leave the major operation until later. This was accordingly done. The patient made a good recovery and got up on the tenth day. He left the hospital at the end of the third week, and was re-admitted a week later.

All pain had disappeared within thirty-six hours of the operation and there had not been any return of it. Patient

was eating and sleeping well, had put on weight, and was obviously greatly improved in health.

Second operation (January 10, 1906).—When the abdomen was opened and the stomach pulled forward it was seen that

FIG. 17

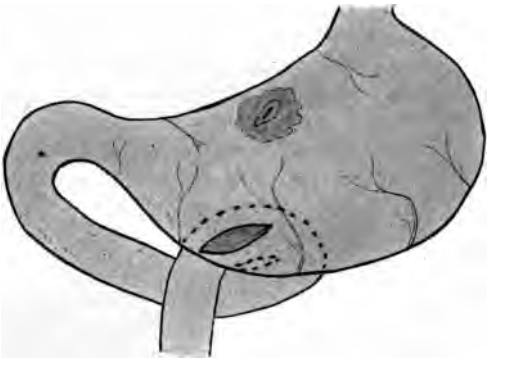

the "growth" had to a great extent disappeared (see Fig. 17). Enlarged glands were found in the omentum, but they were not characteristic of new growth.

FIG. 18.

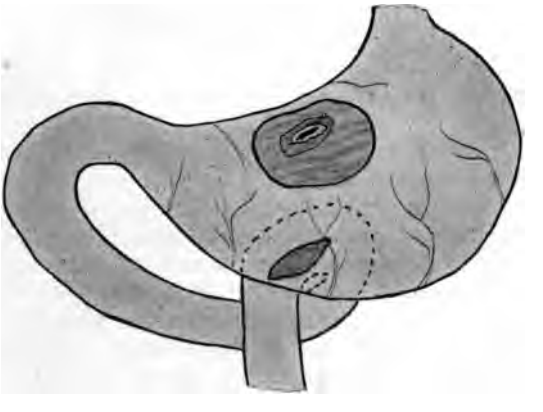

The new growth was now entirely on the posterior surface —near, but not quite reaching, the lesser curvature. A circular ulcer with a clear-cut edge was felt through the anterior wall (see Fig. 18).

The ulcer itself was adherent to the pancreas.

The wound was closed and the patient left the hospital twelve days later. He was last seen on March 26. He takes ordinary diet, has no pain, has gained a stone in weight, and looks well and healthy.

Case 3.—A female patient, æt. 39, was admitted to St. Luke's Hostel under the care of Dr. de Haviland Hall on January 29 this year suffering from gastric pain and general nervous depression. Began to have pain about the first week in December, 1905. Had been treated for nervous dyspepsia at Windsor and gastric neuralgia at Brighton.

Patient complained of severe abdominal pain, going through to the back—the pain is better after food. Has

Fig. 19.

been very sick at times, vomit containing a little blood. Unable to sleep or eat, had bad dreams, was depressed and constipated.

Nothing made out on examining the abdomen, as the patient was hypersensitive, and even slight pressure caused pain. I saw the patient in consultation with Dr. de Havilland Hall on February 6, and it was decided that a gastro-jejunostomy should be done. The operation for various reasons unfortunately was postponed until February 13.

On opening the abdomen an extensive growth was found occupying the cardiac end of the stomach which was considered malignant and quite impossible to remove (see Fig. 19). Posterior gastro-jejunostomy was done in the hope of relieving pain by the quicker outlet thus obtained.

The night of the operation was most satisfactory in that the patient was almost free from pain; this was noticeable all

along until, on February 16, at 12.15 p.m., the patient became collapsed and vomited some blood. Dr. Hubert Roberts did everything possible, but the patient gradually became more exhausted and died twelve hours later.

The *post-mortem* examination (see Fig. 20) showed that what was taken for a malignant growth was chronic inflammatory thickening around a large ulcer situated high up on the posterior wall in the lesser curvature towards the cardiac end.

Death was due to hæmorrhage from an oval opening in a large vessel running along the floor of the ulcer. It was

FIG. 20.

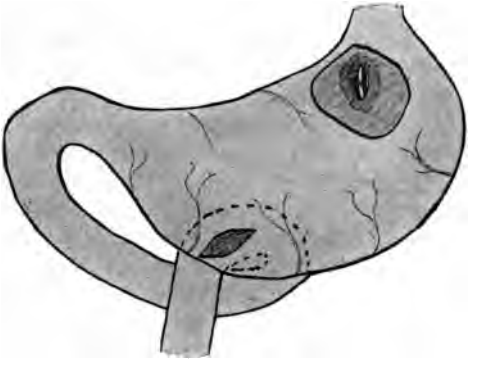

interesting to note the perfect mechanical safety of the gastro-jejunostomy on the fourth day of the operation.

REMARKS.

Additional interest in the case of the old lady is that it is a good example of the fact that even very old people stand operations well when their tissues are young, and the number of years a patient has lived is not in itself a bar to even a considerable surgical operation.

In Case 2 all of us present at the first operation were sure that the growth was malignant, and I regretted at the time that I did not think the man's general condition warranted me doing a partial gastrectomy. It was a matter of great surprise and satisfaction to see when the abdomen was reopened how the mass had melted away.

I have been so much impressed with this case and the next that I am strongly inclined to think that in a large

number of cases where partial gastrectomy is under consideration it would be always as well to do a preliminary gastro-jejunostomy. The operation in either case is of material benefit to the patient. The pain suffered is much less or entirely disappears and peaceful sleep is procured. The diet can be increased and the food is digested.

If a partial gastrectomy is necessary the patient is in much better case after two or three weeks than when the abdomen is first opened, and the time lost makes no material difference in the possibility of removal of the growth.

In the third case when the stomach was exposed the condition looked so hopeless that I nearly closed the wound without doing anything further.

The effect of the operation on the patient was interesting and most satisfactory during the three days that she lived, The drawn, pain-stricken appearance of her face disappeared. and she lay in bed quite comfortable and placid.

I was fortunately able to procure a *post mortem*, which I was anxious to get, to see whether this case was also only inflammatory growth around an ulcer; this, as the specimen shows, it proved to be, and a microscopical section of the tissues near the ulcer is a further proof of it.

The lesson the third case teaches is that delays are dangerous in cases of gastric pain which are well marked and do not readily respond to medical treatment. Under such circumstances the abdomen should be opened and the stomach examined. A gastro-jejunostomy can be done, and if there has been hæmatemesis to any marked degree the stomach should be opened, through healthy tissue in the neighbourhood of the ulcer, and the ulcer either cauterised, cut out, or ligatured to prevent further hæmorrhage.

XXIX.—*A Case of Cystic Tumour of the Spermatic Cord.*

By CUTHBERT WALLACE, M.B., B.S., F.R.C.S. *Read May 11th*, 1906.

W. R. W., a male, æt. 41, was admitted into St. Thomas's Hospital in April, 1904. Five years previously he had noticed a swelling above the right testis, which had gradually increased in size. For some time after its appearance it "would go back," but had become irreducible for the last two years. A fortnight before admission the patient had lifted some heavy furniture, which act had caused pain in the mass and an increase in its size. There had been several attacks of abdominal pain and vomiting, the last one of which was so severe as to suggest to his medical attendant the possibility of obstructed hernia.

On examination a swelling the size and shape of a large pear was found to occupy the upper part of the scrotum and adjacent part of the inguinal canal. It was irreducible; there was no impulse. It was nodular on the surface and elastic in consistence. Translucency was not obtained. Rectal and abdominal examination showed the presence of a mass occupying the right fossa and the right posterior quadrant of the pelvis. The nature of the tumour was obscure, but the physical properties of the scrotal and inguinal portions suggested an irreducible inguinal hernia, although the presence of the abdominal portions and some details of the history were not consistent with this view.

Operation.—An incision showed the tumour to occupy the upper part of the scrotum immediately above the testis, from which it was, however, quite distinct. Traced upwards, it entered the inguinal canal. This was, therefore, slit up and the spermatic cord exposed in its full length. The mass was then seen to lie within and be covered by the cremaster muscle and fascia. When this latter was divided the tumour was seen to enter the abdomen through the internal ring. The structures of the cord were spread out over the tumour, so that its separation was a matter of some difficulty and left the cord in a very ragged state. Near the internal ring the adherence of the mass to the surrounding tissues was very intimate and several small cysts about ·5 cm. in diameter became detached from the main mass. Traction on the

tumour showed that it was continuous with that felt in the belly, from which it could only be separated with the knife. While this was being carried out the appendix appeared and to it were adherent many small cysts similar to those just mentioned.

The appendix was removed and a finger introduced into the abdomen. A careful search made it plain that the intra-abdominal mass was composed of a series of small cysts which were but loosely tied together. The fact that several of these small cysts were adherent to the appendix seemed to point to an intra-abdominal site for the mass; but if this was the case there must have been extensive adhesions, for no intestines protruded or were seen.

Description of tumour.—A complex, thin-walled, lobulated, cystic tumour which was removed from the spermatic cord. It is cordiform, with the apex downwards, and measures in the vertical diameter 10·5 cm., its chief transverse diameter about 6·5 cm., and its greatest circumference (taken in a slightly oblique direction) 18 cm. While in the body the long axis corresponded with that of the spermatic cord; the centre of the tumour lay midway between the two abdominal rings. The exterior is smooth and glistening except where covered with the connective tissue derived from the spermatic cord, the sheath of which was divided in its removal.

The mass consists of two main cavities the highest of which measures about 5 cm. and is continuous with the intra-abdominal extension of the mass mentioned in the account of the operation. The lower of the two main cysts, which in the body lay partly to the left side of the other, measures about 9 cm. Although the lower chief cavity is single it presents many falciform processes, the presence of which suggests that it may have arisen from the fusion of a series of lesser cysts. In addition to the two main cavities there are shown three processes of more compact structure. One of these, projecting partly into the upper of the two main cysts, is broadly attached to the septum that separates them. A second, of crescentic form and about 5 cm. in length, is attached partly to the septum mentioned, whence it extends beneath the roof of the lower cyst. The third projects into the lowest loculus of the same cyst. These more solid masses as seen in section are constructed of a compact series of small alveoli, the largest of which is about ·5 cm. in diameter. Microscopic preparations of these more solid parts reveal a congeries of sharply defined spaces lying in a scanty, loose

connective tissue and lined with a distinct flat endothelium. The shape of these spaces is very various, some being circular, others oval or flattened. There is nowhere any indication of a columnar or cubical epithelial lining even in the smallest cysts, which are altogether microscopic.

The fluid in the main cysts was clear in the recent state; that from the more solid portion in the higher cyst was slightly milky.

Without for the moment discussing its etiology and regarding the clinical features only, it seems probable that the case just described must be classed with those to which the older writers gave the following names: "diffuse hydrocele of the spermatic cord," "hydrocele of the cells of the tunica communis," "hydrocele by infiltration," "multilocular hydrocele of the cord." No such cases have been described of late years, and modern English text-books dismiss the disease with a few words and speak of it as an œdematous condition of the cord. Thus in Quain's *Dictionary of Medicine* (1902) the following sentence occurs: "The diffuse hydrocele, which is very rare, is simply an œdema of the areolar tissue of the cord. When inconvenient owing to its size, antiseptic incision and drainage should be undertaken." Curling, writing in 1878, says "The disease is of the nature of a simple œdema, a watery fluid being diffused throughout the loose tissue connecting the vessels of the spermatic cord." In none of the cases, with possibly one exception (Flowers, *Medical Times and Gazette,* 1859), that I have been able to find will the theory of simple œdema suffice to explain the conditions described by the older writers or found in the present case. The idea that these tumours were of an œdematous nature seems to have arisen with Percival Pott (*Treatise on Hydrocele,* 1773) who first described and who regarded it as due to a dilatation of the lymph-spaces caused by some obstruction. Modern writers, evidently unacquainted with the condition, have been content with this explanation. The three cases described by Pott occurred in middle life and were of considerable duration. The tumours were situated in the cord and reached from the top of the testis upwards towards the abdomen. In all the testis was distinct. The surface was nodular and the skin normal except in one case, where an excoriation had been produced by an ill-fitting truss. The two tumours of less extent were stated by Pott to have resembled irreducible omental herniæ. The largest tumour reached to the knee and was continuous with an

abdominal swelling which increased in size when pressure was exerted on the scrotal portion.

Incision into the growths showed that they were made up of congeries of cysts which in one instance were traced, after death, into the abdomen as far as the origin of the spermatic vessels.

Humphry (Holmes' *System of Surgery*) describes a case of a youth, æt. 19, who had a tumour connected with the upper end of the testis, and above this again a second tumour situated in the cord. Both were fluctuating and translucent, and the upper tumour displaceable into the abdomen. Incision into the upper one set free clear fluid and exposed numerous thin-walled cysts connected with each other and with a main cyst. The tumour in the scrotum was an ordinary hydrocele.

Steinthal (*Centralblatt f. Chirurgie*, 1885) relates a case in which a swelling suddenly appeared in the spermatic cord of a man æt. 20. An incision evacuated a yellow fluid from a moderately sized cyst, in the posterior wall of which were numerous small cysts. Cubical and columnar epithelium were found in one of the cavities, but the author was of the opinion that it was of an endothelial origin.

Von Baum (quoted by Kocher, *Deutsche Chirurgie*, 50 B), quotes the case of a man, æt. 67, above whose right testis a tumour had existed for twenty years. For nine months before he came under observation this had increased rapidly in size, and when seen was as large as a man's fist. Puncture with a trocar reduced it but little. The testis and cord were ablated. Examination then showed that the tumour was formed of a "cellular membrane" the thickness of two thumbs which surrounded the cord. The fluid from some of the cysts contained spermatozoa.

Curling, in his *Diseases of the Testis* (1878), gives an interesting account of this affection chiefly borrowed from Pott, and gives an illustration, taken from a book by Scarpa, of the external appearance of such a tumour as it lay in the cord covered by the cremaster muscle. Mention is also made of a description of another case by Bertrandi (1778), who had the opportunity of a dissection after death. Shattock (*Path. Soc. Trans.*, vol. xliii, p. 107) has described and figured what may well be a tumour of a similar nature to the one now under discussion. In this case a cystic tumour three inches in length lay behind the testis and epididymis and between these and the vas. The vessels of

the spermatic cord passed over its inner and posterior surface. The testis and epididymis were perfectly normal, and the tunica vaginalis quite distinct from the mass.

The tumour, which is now in St. Thomas's Hospital Museum, consisted of a thin-walled cyst which showed on its anterior wall three other thin-walled cysts. The large cyst, although forming but a single cavity, presented several crescentic septa suggesting the fusion of smaller cavities to form a larger one. The hydatid of Morgagni was distinct. Shattock suggested that the cysts were formed from remnants of the Wolffian body, and mentioned a Hunterian specimen in the Museum of the Royal College of Surgeons (No. 4291) which had probably a similar origin.

The following is an abstract of the description of this specimen: "A testicle, to the posterior part of which, but external to the tunica vaginalis, a large cyst which contained a serous fluid is attached; at its anterior part there is an oval aperture by which it communicates with a smaller cavity imbedded in the lower part of the spermatic cord just above the upper end of the epididymis."

Putting all the recorded cases together, a very good picture of this disease can be formed. It is usually found in adult life, and is of slow and painless growth. As a rule the dimensions of the tumour are small but may, as in a case of Pott's, reach a remarkable size. It occupies some position in the length of the spermatic cord, usually starting from the top of the testis and reaching upwards and even entering the abdomen, where it forms a readily palpable mass. The testis is normal, except for the occasional presence of a vaginal hydrocele. The surface is nodular and the mass more or less translucent.

Pressure while the patient is in the recumbent position may produce some decrease in size, due either to a partial reduction or to a displacement of fluid.

Simple incision or puncture is followed by an escape of clear or slightly turbid fluid, but fails to secure a total disappearance of the tumour. Further exploration reveals the fact that the tumour is lying within the spermatic cord covered by the cremaster muscle or fascia, and is composed of many cysts of varying dimensions, the larger lying at the most dependent part. The cysts are thin-walled and in some cases easily detachable from the main mass.

From the literature it would seem that these cases have most often been confused with irreducible inguinal herniæ.

The intimate connection with the spermatic cord renders their removal extremely difficult, and in the writer's case atrophy of the testis followed from interference with the spermatic vessels.

It is not possible to state definitely that all the cases above mentioned had a similar origin, but they had so many features in common that it seems highly probable that such was the case. That the etiology of this class of case is obscure is shown by the number of theories that have been put forward.

The following have been advanced:

(1) That the cysts are due to hydatids.
(2) That they are due to loculation of an encysted hydrocele.
(3) That the cysts are of the nature of spermatoceles.
(4) That they are of the nature of a lymphangeioma.
(5) That they are of fœtal origin.

It is quite evident that the disease under discussion has nothing in common with hydatid disease, although such cysts have been described in this region. It is equally clear that the loculation of an encysted hydrocele will not account for the conditions found, and the histories of the cases are enough to refute such a contention. In one case spermatozoa were found, but too much stress must not be laid on this point as it was a solitary observation, and their presence is easily accounted for by a fortuitous communication with the excretory canals of the testis.

If these tumours are to be considered of a lymphatic nature, it is necessary to show that the lymphatic system does or can produce similar tumours in other parts of the body. The lymphatic nævi such as produce macroglossia at once occur to the mind, but a little consideration will show that the two tumours have little in common. Such lymphatic nævoid growths contain cysts, it is true, but none of such size as are met with in the disease of the spermatic cord. In macroglossia the cysts or spaces are distributed throughout the substance of the tongue between the muscle-fibres, and it is impossible to remove the tumour without removing the part of the organ it has infiltrated. After removal of the tongue the tumour collapses in great part, while in diffuse hydrocele of the cord it retains its shape and bulk.

Hydrocele of the neck certainly resembles somewhat closely the tumour under discussion, since here the cysts are of large size, forming a definite mass. It is, however, a matter of doubt as to whether a hydrocele of the neck owes its origin to dilatation of lymphatic spaces; to justify this

view it must be shown why such tumours always occur in the same place or that similar growths can be produced by obstruction to lymphatics in other parts of the body.

Chronic lymphatic obstruction, such as is seen in malignant disease of the breast, invading the axillary lymphatics, or such as is met with in spurious elephantiasis, produces a condition of things that is widely different from the appearances described above. In fact, all that is known seems to point to the impossibility of considering the disease under discussion as due to lymphatic blockage pure and simple.

The last theory to be examined is that which states that these tumours are developed from fœtal remains in the spermatic cord. The so-called cystic adenoma of the testis is usually attributed to the remains of the Wolffian body undergoing a late development in the testis, and tumours of similar constitution found in the kidney are attributed to the same cause. Bearing in mind the original relation of the testis and the kidney to one another, it does not seem improbable that remains of the Wolffian body should be found in the spermatic cord, and that these undergoing an abnormal development should give rise to the tumours under discussion. Although this theory is not capable of proof and although no epithelial lining is found in the cysts, with the one exception reported by Steinthal, yet the fact that in one case the tumour reached from the top of the testis to the origin of the spermatic artery seems to support the Wolffian theory.

XXX.—*Carcinoma of the Thyroid Gland.* By A. C. Hudson, M.D., F.R.C.S., introduced by Mr. L. S. Dudgeon. *Read May 11th*, 1906.

BY the courtesy of several of the members of the staff of St. Thomas's Hospital I have recently had the privilege of examining the notes and clinical material of a somewhat remarkable series of cases of thyroid tumour. Of these the eight cases to be first described exhibited features of carcinomatous invasion. In the next six cases, although the clinical history was not characteristic of malignant disease, yet the histological structure of the tumours was that of carcinoma. The two tumours which will be described last were discovered after death, and had given no evidence of their existence during life.

Case 1.—M. J. H., female, æt. 49. Under the care of Mr. Clutton.

Tumour two years; painful one month, without increase in size; dysphagia five days. Tracheotomy performed for urgent dyspnœa three weeks before death by Mr. Percy Sargent.

The tumour was contained within a capsule common to it and the thyroid gland, from which, however, it was sharply marked off. No secondary growths were found. It proved to be a squamous-celled carcinoma, the cells of which did not exhibit keratinisation. Mr. Shattock is of opinion that it originated from remains of the thyro-glossal duct.

Case 2.—E. H., female, æt. 49. Under the care of Mr. Battle.

A tumour had been noticed in the mid-line of the neck for eighteen months, and had ulcerated through the skin. At the operation for removal in October, 1899, it was found to have infiltrated the neighbouring muscles.

The tumour showed a scanty connective tissue with few nuclei supporting columnar epithelial cells arranged so as to enclose irregular spaces, into many of which papilliform processes projected. No colloid material was seen.

Six months later the tumour recurred, and at the same time a tumour in the left side of the neck which had existed about the same time as the central one ulcerated through

the skin, causing considerable hæmorrhage. At this time both tumours were about the size of a lemon, and small, hard, glands could be felt beneath the angles of both jaws.

Subsequent history unknown.

Case 3.—Miss M. Under the care of Mr. Clutton.

There was a hard, nodular goitre which had existed for fifteen years, but had caused no distress, and a large glandular mass in the right side of the neck, which had been noticed for twelve months. For six weeks this had been increasing rapidly in size, with signs of inflammation, but under the influence of a week's rest it diminished to half its original size, and became more movable. It was then excised by Mr. Clutton, the operation involving resection of several inches of the internal jugular vein.

Microscopic sections of the tumour showed lymphatic gland tissue invaded by a new growth, consisting of a scanty connective-tissue stroma rich in nuclei, in which columnar and cuboidal epithelial cells were disposed so as to enclose spaces many of which were rendered very irregular in outline by papilliform ingrowths. Most of them had thin mucinoid, a few colloid, contents. There was active invasion of the surrounding tissues by the growth, side by side with which could be seen at some places a tendency to the formation of a capsule by compression of the peripheral parts of the tumour.

Shortly after operation the voice became impaired, and an intra-laryngeal subglottic growth was discovered, together with signs of early paralysis of the right vocal cord. Subsequently the voice became normal, and the patient appeared to recover complete health.

Eight months after operation the health was not quite so good, and the intra-laryngeal growth was obvious. Three months later the patient was able to resume her occupation as lady's maid.

Case 4.—M. B., female, æt 49. Under the care of Mr. Clutton.

Goitre twelve years, local and lancinating pain six months. Recently the patient had completely lost her voice. Tracheotomy was required, but the patient died shortly afterwards.

The tumour was completely encapsulated, except at the upper part, where irregular growth projected through the capsule.

Microscopic sections showed in the deeper parts of the

tumour polyhedral and columnar epithelial cells, arranged sometimes in solid masses, at others forming small alveoli, many of which contained a colloid material. These epithelial groups were aggregated into lobules, and to some extent separated from one another, by a scanty connective-tissue stroma with few nuclei. In the more peripheral parts of the tumour the alveolar formation tended to be replaced by solid epithelial plugs and single epithelial cells of various shapes and sizes, while the connective tissue became more and more embryonic in type, these changes being most pronounced immediately beneath the capsule.

Case 5.—A. W., female, æt. 64. Under the care of Mr. Battle.

Tumour in right side of neck six months; voice thick one month; some dysphagia.

At the operation for removal the tumour was found to extend back between the trachea and œsophagus, but was apparently completely encapsulated. It was pronounced by Mr. Shattock to be a carcinoma composed of spaces filled with glandular cells and invading the surrounding tissues.

The patient enjoyed subsequent good health for two years, when there was a rapid recurrence of the tumour, which proved fatal in six months. Secondary growths were found in the lungs.

Case 6.—I received the following notes of the case from Mr. Pitts at the beginning of this year:

E. B., female, æt. 47. Five years ago a small tumour was removed from the neck by another surgeon, and was pronounced to be a carcinoma of the thyroid gland containing much fibrous tissue. Each succeeding year lymphatic glands, exhibiting a growth exactly similar to the primary one, have been excised from the neck. Sharp pain has been noticed in the left leg during the last year. There is now a fusiform tender swelling of the lower end of the left femur. A number of small glands can be felt in the neck.

Case 7.—Mrs. V., under the care of Mr. Clutton. A small elastic tumour, fixed to the right side of the cricoid cartilage, had been noticed for six weeks, when removed in June, 1905. It was found to be continuous with the thyroid gland, and to have infiltrated the muscles of the neck.

In microscopic sections (Fig. 21) the tumour was seen to be

composed for the most part of regular alveoli, lined by cubical or sub-cubical epithelium, and containing vacuolated colloid material, together with some solid epithelial masses. The resemblance to the corresponding structures met with in the normal thyroid gland was very remarkable. There was a

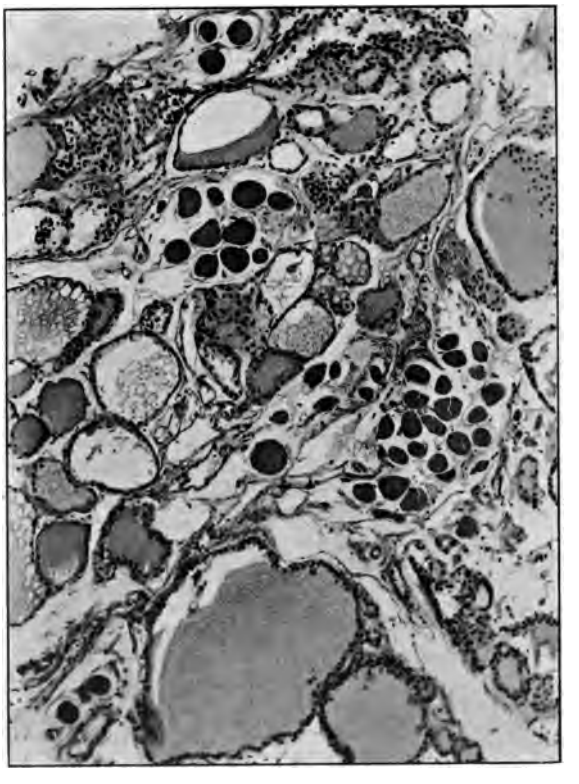

FIG. 21.—Microscopic structure of tumour in Case 7 of first group, showing infiltration of sterno-mastoid muscle by thyroid tissue.

fairly abundant loose fibrous connective tissue. At many points were seen bundles of striped muscle-fibres, many of them shrunken and atrophic, completely surrounded by the neoplasm.

There was no evidence of recurrence of the tumour fourteen weeks after operation.

Case 8.—S. S., female, æt. 64, under the care of Mr. Battle.

Swelling in right side of neck noticed six years, one in mid-line noticed six months, and one in left side of neck, noticed one week. Dyspnœa three months, no dysphagia.

In the course of the operation for removal one tumour was found to be cystic with an indurated base and very adherent to the trachea. Four days later tracheotomy was required. The patient died a week later.

Microscopic sections showed very scanty connective tissue in which lay epithelial cells, arranged partly in solid masses, partly so as to form colloid-containing cavities. There was at one part a very dense capsule, which was apparently being invaded by epithelial processes arising both from epithelium imbedded in the capsule and from the more central parts of the tumour.

In the group of six cases to be next described, although the clinical history in all cases would seem to negative the view that the patients were victims of malignant disease, yet the microscopic structure of the tumours removed was pronounced by Mr. Shattock to be that of carcinoma. In no case epithelial invasion of the tumour capsule could be seen. In all the cases the supporting connective tissue was of finely fibrillated texture, with a very few elongated nuclei, and capillary blood-vessels were very numerous.

Case 1.—A. N., female, æt. 32, under the care of Mr. Makins.

Tumour the size of a turkey's egg, which had been growing for eight years, but had caused no urgent pressure symptoms, enucleated May, 1905. Ten months later the patient was in good health.

The tumour was composed, for the most part, of irregularly arranged columns of large polyhedral cells, with practically no lumen-formation or colloid.

Case 2.—C. W. T., male, æt. 42, under the care of Mr. Cuthbert Wallace.

Tumour which had been noticed for ten weeks, and was found to involve the whole of the left lobe of the gland, removed. The tumour was of friable consistence, and there was no tumour capsule. The gland-capsule which enclosed it was not removed. The patient was quite well seven months later.

The tumour consisted, for the most part, of polyhedral epithelial cells arranged in solid groups and columns. There were some narrow tubules with colloid contents.

Case 3.—F. H., female, æt. 25, under the care of Mr. Clutton.

Deaf mute, whose aspect was somewhat suggestive of cretinism.

Tumour, which had been noticed for twenty years, removed in July, 1903. There was no normal thyroid tissue overlying it. Two years later the patient was in good health.

The tumour consisted chiefly of polyhedral epithelial cells, arranged almost entirely in solid groups. Occasionally a central lumen could be seen, with granular contents quite distinct from colloid.

Case 4.—L. P., female, æt. 28, under the care of Mr. Pitts.

The neck had always been large, more noticeably so for the last eleven years. Slight dyspnœa.

In December, 1903, the isthmus and left lobe of the thyroid gland were removed. The left lobe was found to contain multiple adenomata. The tumour in the isthmus was composed chiefly of columnar epithelial cells arranged to some extent in solid masses, but for the most part enclosing tubular spaces containing a coarsely granular material and a certain amount of matter resembling a much vacuolated colloid.

In March, 1906, more than two years later, the patient was in excellent health.

Case 5.—M. A. L., female, æt. 47. Under the care of Mr. Ballance.

Swelling in neck for four or five years, increasing more rapidly for two or three weeks. Pressure symptoms for two or three years, more pronounced during the last ten weeks.

The tumour was removed in June, 1904, by Professor von Mickulicz. It contained epithelial cells of polyhedral columnar and cubical form, very atypically arranged, some in solid masses, others enclosing spaces, many of which contained masses of colloid. In August, 1905, the patient was in rather poor health, but there were no signs of recurrence of the tumour. In March, 1906, she wrote that she was feeling very poorly, and that there was some pain in the throat.

Case 6.—J. S., female, æt. 34. Under the care of Mr. H. B. Robinson.

Tumour the size of a hen's egg, which had been noticed to be growing for three years, and had caused symptoms of pressure for one year, enucleated in January, 1905.

Microscopic sections of the tumour exhibited epithelial cells of very irregular form, many of which appeared to be scattered broadcast through the connective-tissue stroma, while others were aggregated into solid groups or surrounded spaces containing a vacuolated colloid material.

In March, 1906, sixteen months after operation, the patient wrote that her health had deteriorated, and that there was cramp-like pain in the right side and beneath the right scapula.

The two last tumours to be described were discovered in the *post-mortem* room, and had given rise to no symptoms during life.

Case 1.—Tumour about the size of a small cherry found in the right lobe of the thyroid gland of a man æt. 18, who had died, after a week's illness, from purulent meningitis, following middle-ear disease. The right internal jugular vein had been ligatured and divided.

The centre of the tumour was necrotic. Outside this was seen an epithelial growth, consisting of large columnar and cubical cells enclosing spaces, the outline of which was in some cases simple, whilst in others it was rendered extremely complex by the presence of papilliform ingrowths. The contents of these spaces, where such could be seen, consisted for the most part of a thin, mucinoid material; in a few cases colloid was present. The supporting connective tissue was richly nucleated. In the more peripheral part of the tumour was a thick zone of fibrous tissue, into which epithelial processes were pushing their way, the invasion being associated with connective-tissue proliferation and immigration of leucocytes.

Case 2.—The patient was an elderly woman, who had died from retro-uterine sarcoma. The tumour was about the size of a cherry, and exhibited a structure similar in its main features to that of the tumour last described.

A study of the histological characters of the capsule of a simple adenomatous thyroid tumour affords evidence that

this structure is formed as the result of a connective-tissue proliferation at the margin of the tumour, involving both the peripheral portion of the new growth and the neighbouring normal gland-tissue and the subsequent compression during the growth of the tumour of the tissues so involved. As a result epithelial cells, which at one time formed constituents of the more central portions of the tumour, become included between the layers of the capsule, where they exhibit usually a somewhat atrophic appearance and a linear arrangement in conformity with the lamination of the capsule.

I would suggest that the connective-tissue proliferation referred to above as accompanying the epithelial growth is an evidence of an interreaction between the growing epithelial cells and the connective tissues, by means of which, under ordinary circumstances, a certain state of equilibrium as regards growth is maintained. A disturbance in this equilibrium might be conceived to give rise to just such a condition of epithelial growth as has been described in the last two tumours, and to be responsible for the phenomenon of the supervention of a malignant character in a thyroid tumour, which has for years existed as an encapsulated, apparently innocent, growth. Moreover, it would seem possible to expand the hypothesis so as to afford an explanation of those cases which have been recorded in which a primary tumour and its metastases have exhibited a different degree of malignancy and such a phenomenon as the partial encapsulation of an obviously malignant tumour to which attention was called in one of the cases described above.

Conclusions.

(1) That thyroid carcinoma is probably somewhat commoner, not infrequently pursues a more protracted course, and is more amenable to surgical treatment than is perhaps generally believed.

(2) That the disease is very frequently, if not always, the manifestation of a change in type of an apparently innocent encapsulated tumour, a fact which will reinforce other indications for the removal of such a tumour.

(3) That difficulty is likely to be experienced in correctly estimating the degree of malignancy of an epithelial thyroid tumour solely from the type and arrangement of the epithelial cells.

(4) That the most important aids in the diagnosis of the

malignancy of these tumours are clinical evidences of the character of local extension and the formation of metastatic growth and microscopic evidence of malignant invasion of the capsule and surrounding tissues.

(5) That it is important in microscopic examination of thyroid tumours not to mistake epithelial cells which have been passively included in the capsule during the process of its formation for cells invading it from within.

(6) That the behaviour of epithelial thyroid tumours appears to be governed by some interreaction between the epithelial and connective-tissue cells, which is liable to vary in character in different individuals and in different regions and at different periods in the life-history of one individual.

XXXI.—*A Case of Perforated Gastric Ulcer treated by Evisceration and Irrigation. Recovery.* By E. W. Roughton, M.D., B.S., F.R.C.S. *Read May 11th*, 1906.

ADELA M., æt. 26, enjoyed good health and was free from indigestion until the middle of January, 1906. She then began to suffer from pain after food. On the morning of January 31st she felt better than usual and had breakfast at 9.30. At 12.30 mid-day she was seized with violent abdominal pain and vomited several times. During the course of the afternoon she was seen by Dr. Beauchamp Hall, who diagnosed a perforation and sent her to the Royal Free Hospital. On admission she was pale and collapsed and in great pain. Abdomen tender all over, not moving with respiration, not distended. Liver dulness impaired, not abolished.

Operation at 6 p.m., about five and a half hours after the onset of symptoms of perforation.

The abdomen was opened about an inch to the right of the middle line by a six-inch incision, the rectus being displaced outwards. No gas escaped on opening the peritoneum, but there was a good deal of thin yellow turbid fluid; this was not localised to the stomach region, but was soiling all parts of the peritoneum. The stomach being brought into view, a perforation one eighth of an inch in diameter was at once discovered on the anterior surface of the stomach nearer the lesser curvature and cardiac end. It was easily closed with two rows of Lembert sutures. The extravasated stomach contents were then mopped up with gauze swabs, but as the infection was more or less general it was deemed advisable to flush out the abdominal cavity. With this object the incision was extended downwards nearly to the pubes, the small intestines turned out and received into a hot sterile towel, and a stream of sterile, normal saline at 107° F. directed into Douglas's pouch. When the pelvis was full the lotion ran upwards along the kidney pouches, round the hypochondriac regions, over the front of the stomach, and out of the upper end of the incision, thus travelling in exactly the reverse direction to that in which the stomach contents had extravasated into the abdomen. When the fluid came out clean, the coils of intestine were thoroughly washed and some flakes of lymph wiped off. The excess of lotion was then squeezed out of the abdomen

by pressing on the abdominal wall and the peritoneal cavity wiped dry with large gauze swabs; each viscus and every part of the peritoneum except the lesser sac was thoroughly dried. The intestines were replaced and the abdominal cavity filled up with a fresh quantity of saline fluid. The abdominal wound was then closed with three layers of sutures, no drainage being employed; the operation lasted fifty-one minutes from induction of anæsthesia to the application of dressings. At the end of the operation the patient's general condition was better than at the beginning, the pulse being slower and stronger.

The patient made an uninterrupted recovery, the temperature never rising above 100° F.

My object in bringing this case before the Society is to draw attention to the method of cleansing the peritoneal cavity in cases of perforation of a hollow viscus. All surgeons are agreed that when the extravasation is localised it is better to use swabs and to avoid irrigation, the latter method being apt to disseminate the infection. But when the whole peritoneal cavity is more or less soiled swabbing is inadequate, and it is necessary to irrigate. In my opinion irrigation can only be satisfactorily done when the small intestines have been turned out. Many surgeons dread to do this for fear of shock, but I think the amount of shock caused by this method has been over-estimated: in the case now related it seemed to produce no shock at all. A point of some importance is to commence the irrigation in Douglas's pouch, so that as the lotion pervades other parts of the peritoneum it may be travelling in the opposite direction to that taken by the extravasated stomach contents. In this way the risk of spreading the infection is diminished.

I do not think it is any use trying to drain the peritoneum in these cases, as the places occupied by the tubes soon become shut off by adhesions. If the peritoneum has been effectively cleansed drainage is unnecessary.

The abdominal incision must be long enough to give very free access to all parts of the abdomen. It should be made an inch or more to one side of the middle line, the rectus being displaced outwards. At the end of the operation the anterior and posterior sheath of the rectus should be sutured separately, the undamaged muscle sliding back into place between the two layers of suture. This method does not add appreciably to the length of the operation and minimises the risk of ventral hernia.

XXXII.—*A Case of Complete Removal of a Multilocular Cystic Tumour of the Pancreas; Colo-colic Anastomosis sixteen days later; Recovery.*

By John D. Malcolm, F.R.C.S.Edin. *Read May* 11, 1906.

THE case here recorded is the second in which I have been so fortunate as to be able to remove completely a multilocular cystic tumour of the pancreas. The patient, a Jewess, æt. 50, felt something move in her abdomen and was very sick about six months before she sought medical advice. This disturbance soon passed off and she "forgot" about the "lump," but she began to lose flesh and strength at that time. A month before I saw her she fainted and was very pale for the following week. The fæces were "like ink" for three days and then resumed their natural colour. Apparently there had been a hæmorrhage into the upper part of the alimentary tract. The patient again became conscious of something abnormal in her abdomen, and consulted Dr. Basil Morison, who sent her to me.

Her general condition was good, the urine was normal, and the bowels acted well without medicine. There was an oval, hard tumour in the left side of the upper abdomen measuring about four inches in its lateral diameter and rather more from above downwards. It had considerable mobility, exactly resembling that of a large loose kidney, the greatest fixity being towards the spine. The percussion note over the most prominent parts was dull before and behind, the area of dulness varying with the position of the tumour. The right kidney was somewhat mobile. I diagnosed a malignant growth in a loose left kidney, the capsule of which had not yet ruptured.

At the Samaritan Free Hospital, on April 26, 1905, I opened the abdominal cavity by an incision outside the left rectus muscle. The transverse colon was displaced downwards and pressed forwards by a growth which was seen between it and the stomach. There was only one layer of serous membrane over the tumour, which apparently had developed to the left of the lesser sac of the peritoneum. The kidney was in normal position behind the neoplasm and the tail of the pancreas lay across the upper inch or rather more of its anterior surface, being intimately attached to it.

Many vessels over the tumour were ligatured as they

were divided and the mass was gradually freed without much loss of blood until its only attachment was to the pancreas. I cut into this gland so as to get the whole growth away. The pancreatic tissue bled freely, but it showed no friability and ligatures applied to it held well. A large vein, quite a third of an inch in diameter, was cut across and there was a profuse hæmorrhage for a moment, but both ends were secured in forceps and safely tied. When the pancreas was released it immediately turned round so that its anterior aspect presented unharmed. Evidently the new growth had arisen from the posterior surface of the gland and rather from the upper part of it. The fact that the pancreas had been incised gave rise to no subsequent trouble. In enucleating the tumour both layers of the transverse meso-colon were divided, and the edges of the inferior layer were brought together by sutures. A drainage-tube was inserted through an incision below the twelfth rib, the anterior abdominal wound was closed, and healing gave no trouble.

From the first there was considerable distress caused by vomiting and retention of flatus. The bowels acted when enemata were given, but every attempt to give the patient a sufficient quantity of food was followed by symptoms of a partial obstruction of the bowel, and there was an increasing tendency to intestinal distension. A great deal of peristaltic movement became visible in the epigastric and umbilical regions and down almost to the pubes. I thought that the small intestine was adherent somewhere, probably to the wound of the transverse meso-colon, and as the patient was losing ground, the abdomen was reopened on the sixteenth day after the operation.

It was then obvious that the large intestine was at fault, and that the difficulty was caused by an unusually acute angle at the splenic flexure, the mobility of the transverse colon being interfered with by adhesions between it and the anterior abdominal wall. The ascending and transverse colons were elongated, distended, and tortuous so as to fill the area where peristalsis had been visible. The adhesions were separated, a lateral anastomosis was made between the transverse and descending colons, and flatus escaped freely from the rectum a few hours after the operation. There was for a time a tendency for fæces to collect in the colon, but there were no further urgent symptoms, and the patient, who had become very emaciated, gradually put on flesh and left the hospital on July 3, 1905.

I saw her on March 13, 1906, when her general health was good and the bowels acted regularly without medicine. She complained of a dragging pain in the right side, and the right kidney was much more mobile than it had been.

Fig. 22.—Cystic tumour of the pancreas.

Dr. Morison informs me that the pad and belt which were ordered have made the patient quite comfortable. There is at present no sign of a recurrence.

One half of the tumour is preserved in the Museum of the

Royal College of Surgeons, and Mr. Shattock has kindly given me the following description of it (see Fig. 22):

"The tumour is of spheroidal form, lowly lobular on the surface, and measures about 4½ inches by 3½ inches in its chief diameters. The cysts of which it is almost entirely constructed vary in size, the largest of the whole being about 3 inches across. Between a few, sharply-edged apertures of communication exist, these being due apparently to partial disappearance of the intervening walls.

"In the cut surface between certain of the cysts there occur a few areas of more solid tissue, though such are nowhere of very considerable extent.

"The other half of the specimen was used for microscopic purposes. From this two of the chief portions of solid tissue having the general character of those shown in the half preserved were selected for histological examination. One of the microscopic preparations was cut so as to include portions of a cyst; the latter was lined with an epithelium of columnar cells.

"The solid pieces themselves differed somewhat in structure. In one the substance was fibrous, containing glandular spaces in process of cystic distension. Some of the proper glandular tissue suggested that of the pancreas.

"In places, however, it was quite atypical, the cells, which were of large size and not compressed from cirrhosis, being devoid of any true glandular order and disposed in solid groups after the manner of a carcinomatous lesion. This indication was confirmed in the sections of the second piece of solid tissue, a triangular area about three quarters of an inch along each of its sides. The structure shown here was of large polyhedral cells, some of striking size, and with more than a single nucleus."

Unfortunately, the tumour was kept in spirit for some time and the characters of its fluid contents were not determined.

The other case in which I removed a multilocular cyst of the pancreas is already published,* but may be shortly re-stated. A woman, æt. 49, noticed an enlarging swelling for seven months. A diagnosis of hydronephrotic kidney was made, but a tumour measuring 6 inches in its longest diameter and having the same relations as in the case above reported was removed. Its connections were not so vascular, except those to the pancreas. It consisted of two large and several smaller cysts, into some of which blood had been

* *Med. Soc. Trans.*, vol. xxi, p. 97.

effused. The mixed fluid from several cysts was strongly amylolytic. There was practically no solid tissue. This tumour is also in the College of Surgeons' Museum, No. 2834A, and Mr. Shattock found "no evidence of malignancy" in it. The patient made a good recovery, and was alive and well five years after the operation.

Mr. Shattock has directed my attention to a case of "Cystic Adenoma of the Pancreas," published by Mr. W. Watkins Pitchford,* and to a paper on "Multilocular Cystoma of the Pancreas" by Dr. Reginald H. Fitz. Mr. Pitchford's case was that of a woman, æt. 29, who had an abdominal tumour growing for two years and causing increasing dyspepsia and pain in the back.

It was about the size of a cocoanut, mesial in position, with considerable mobility. The transverse colon was found below the tumour near the pubes. A layer of peritoneum was torn through, and after a second layer was divided the tumour was shelled out with comparative ease. Recovery was uneventful. The growth is preserved in the Museum of the Royal College of Surgeons, No. A 2835. It weighed 2 lb. 2½ oz. and was a multilocular cystoma, having three or four cysts attached to the main mass by a pedicle. The cystic spaces varied in size from 5 cm. in diameter downwards. The liquid in the cysts was inodorous, transparent, of an olive-brown colour, with a specific gravity of 1020, alkaline in reaction, and containing cholesterine; it showed no amylolytic, fat-splitting, or tryptic properties. The walls consisted mainly of bundles of fibrous tissue with foci of more actively growing connective tissue. The cystic spaces were lined with short columnar cells, with well-marked nuclei near their basal ends. In the connective tissue there were clusters of cells of polyhedral form and furnished with special deeply stained nuclei. In two sections typical gland-tissue was encountered. In one this appeared "as the cross-section of a tubular structure lined with columnar epithelium and having no lumen. In the other a distinct lobulus is seen in the gland-loculi, of which the cells are of a polyhedral form, with clear cell-body." Owing to the position of the tumour, and especially on account of its microscopic appearances, it was considered of pancreatic origin, "being probably developed very early in life in some outlying fragment or accessory portion of the gland."

* *Path. Trans.*, vol. liv, p. 354.

Mr. H. H. Clutton has published* a case which, in the details of the operation, resembled the foregoing so closely that it must be mentioned here, although the cyst was unilocular. A woman, æt. 38, had a swelling in the left side of the abdomen at the age of twenty-two, there being a history of a squeeze of the part when she was sixteen. Thirteen years later, after a miscarriage, there was a severe dragging pain on the left side, with nausea and flatulence. Some twenty months later 2½ drachms of pale yellow fluid, which became nearly solid on boiling, were withdrawn through a fine cannula from a globular mobile tumour, which then disappeared. It was, however, again discovered after another eighteen months, and the patient came under Mr. Clutton's care for operation. All the organs appeared to be healthy, the right kidney was mobile, and there was no evidence "that the left kidney was not in its normal position." The relations of the tumour were exactly as in my cases. When the great omentum was divided "the globular cyst was at once, and quite easily, lifted out through the wound on to the abdominal parietes, bringing with it, but without any traction, the tail of the pancreas." It was necessary to cut through pancreatic tissue in order to remove the cyst. A fistula followed, and a large quantity of fluid was discharged through a drainage-tube. This gradually ceased, and the patient was discharged quite well seven and a half weeks after the operation. The cyst is preserved in St. Thomas's Hospital Museum, No. 1414A.

Professor Dunstan examined the fluid from the cyst and a specimen of the discharge collected on the fifth day. The latter was a true pancreatic secretion. The cyst fluid closely resembled it, but did not emulsify fat, convert starch into grape-sugar, or digest fibrin.

The tumour was regarded as probably a pure retention cyst of the pancreas. But the four cases above recorded show a remarkable resemblance to each other, and seem to illustrate different phases of one pathological condition. Mr. Clutton's case was unilocular. My first case (the second recorded above) was multilocular, without solid tissue; in my second case there was a small amount of solid matter, and in the case published by Mr. Watkins Pitchford the solid material is in much larger quantity. There seem, therefore, to be reasons for regarding all four as cystic new growths.

* *St. Thomas's Hospital Reports*, vol. xxi.

Dr. Fitz,* setting aside inflammatory conditions, collected all the cases of "benign multilocular cysts of pancreatic origin" which he could find. These were as follows: (1) Bozeman (*New York Med. Journ.*, 1882, vol. xxi, p. 46) removed from a woman, æt. 42, a multilocular cyst containing 2½ gallons of brown liquid. Garrigues (*Med. Record*, 1882, vol. xxi, p. 286) described this tumour and showed that the cysts were lined by cylindrical or polygonal epithelium, and the resemblance to ovarian cysts was noted. (2) Riedel (*Arch. f. klin. Chir.*, 1885, vol. xxii, p. 994) recorded the case of a woman, æt. 45, in which the cyst existed nine years. It filled the abdomen and was supposed to be an ovarian tumour before the operation. Ten litres of brown fluid were drawn off by puncture and the tumour was removed. The cysts had adenoid projections from their walls and were lined by cylindrical epithelium. In some there were papillary elevations, as in ovarian cysts.

(3) Paltauf (*Zeitschr. f. Heilk.*, 1886, vol. vii, p. 19) found a tumour twice the size of a man's fist, apparently continuous with the pancreas, in the body of a woman who died of mammary cancer. It contained a thick, slimy, greyish-brown fluid. There were two projecting cystic masses on its surface. The cysts were lined by cylindrical epithelium and the pancreatic duct was found within the gland.

(4) Kuhnast (*Inaug. Diss.*, Breslau, 1887, p. 77) published the case of a man, æt. 51, in whom the body of the gland was made up of cysts, one as large as a medium-sized apple. Almost the entire gland was transformed into fibroid tissue. There is no evidence that there was any new growth in this case.

(5) Martin (*Virchow's Arch.*, 1890, pp. 120, 230) reported a case in which a tumour the size of an egg was observed in a woman, æt. 21. When she was thirty-four the tumour had become the size of a man's head and was thought to be an ovarian cystoma. An exploratory operation showed that the mass was behind the transverse colon and the abdomen was closed. Martin operated when the woman was fifty years old. The tumour then filled the abdomen and 15 litres of a thick brown fluid were withdrawn. The mass was removed, leaving a stump the size of two fingers. The wall of the tumour contained many cysts lined with cylindrical epithelium.

(6) Gussenbauer (*Prag. med. Woch.*, 1891, vol. xvi, p. 365) related a case in which he drained a pancreatic cyst in a

* *The American Journal of the Medical Sciences*, New Series, vol. cxx, p. 184.

woman æt. 28. Some months later the patient died of phthisis. The left half of the pancreas consisted of a collection of cysts lined with cylindrical epithelium. The pancreatic duct was opened from the duodenum to the cysts.

(7) Thiraloix and du Pasquier (*Bull. de la Soc. Anat.*, 1892, vol. lxvii, p. 310) related a case in which the whole gland consisted of a mass of cysts and there was no constriction of the duct of Wirsung. In these two cases also there is no evidence of the existence of a new growth.

(8) Cibert (*Gaz. des Hôp.*, 1896, vol. lxix, p. 347) described a tumour removed by Poncet from a woman æt. 26. The growth existed four years and was the size of an adult head. It consisted of a large cyst with smaller cysts in its wall. These were lined with cylindrical epithelium.

Dr. Fitz's own case was that of a man, æt. 36, who had a rapidly growing tumour in the left side of the upper abdomen causing indigestion troubles and extreme weakness although the patient gained in weight. A cyst of the pancreas was diagnosed and Dr. M. Richardson cut down on and excised it. Diseased portions of what was supposed to be the pancreas, but having a malignant look, were removed with the tumour. The patient was sent home six weeks later with a sinus and slight discharge. The growth was described as a hæmorrhagic cystadenoma. The contents, a reddish-brown fluid, contained blood, but no pancreatic ferment. Some of the cavities contained projecting papilliform growth and many were lined by cylindrical epithelium. Occasionally the distribution of the epithelial cells suggested the acini of the pancreas, but the normal structure of the gland was not seen. In some sections a tendency to atypical growth of epithelial cells was apparent. The cells were of a cylindrical character but by no means of an uniform size, shape, and arrangement. They were grouped in a tubular form, but often presented an irregular alveolar appearance. The tumour was considered to be on the border-line between a proliferating cystoma or cystadenoma and a cystomatous carcinoma.

Dr. Fitz also referred to a case recorded by Hartmann (*Cong. Franç. de Chir.*, 1881, p. 618) in which a pancreatic cyst was drained. The patient died six months later. The entire body and tail of the pancreas formed a polycystic mass and Gilbert regarded the condition as representing a cystic epithelioma. Cancerous nodules were found in the liver. In describing this case reference was made to one described by Danot and Gilbert (*Études sur les Maladies du Foie*, Paris,

1888) which was regarded as a tubular pancreatic epithelioma, with secondary growths in the liver.

A case closely resembling mine in many details was published by Dr. L. H. Dunning of Indianapolis.* He removed a multilocular cystic tumour which was attached to the pancreas and was mistaken for a left hydronephrosis. Under microscopic examination "somewhat regularly formed acini lined by epithelium" were seen. "While this adventitious tissue was not typical of pancreatic tissue, it might pass for such."

These tumours are rare, my two specimens and that described by Mr. Watkins Pitchford, being the only examples in the Museum of the Royal College of Surgeons. Moreover, in some of the cases collected by Dr. Fitz the abnormal condition appears to have arisen from dilatations of the pancreatic ducts, and not as a new growth.

It has been suggested that some tumours closely resembling those described above and found in the neighbourhood of the pancreas do not arise from that gland but from remnants of the Wolffian body. Professor Monprofit has described † a large cystic tumour which was so firmly attached to the spleen and to the tail of the pancreas, that it was necessary to remove both to complete the operation, from which the patient made a good recovery. The microscopic and other characters of the neoplasm constituted the chief grounds for believing that the tumour did not originate in the pancreas. On the same grounds, in my two cases, the tumours would be definitely attributed to this gland as their site of development. The first contained strongly amylolytic fluid, and was certainly not a retention cyst, whilst the microscopical characters of the second were suggestive of the proper structure of the pancreas. There can be no doubt, therefore, that cases do occur in which the connections, and structure, and contents of the tumours clearly indicate that they are of pancreatic origin.

The diagnosis of these removable multilocular cysts of the pancreas is very difficult. The fact of their being removable involves the presence of sufficient pancreatic tissue to prevent symptoms arising from destruction of the gland. In both my cases, and in others to which I have referred, the tumours were mistaken for renal growths, and this error may be

* *The American Journal of Obstetrics*, 1905, p. 101.

† "Ablation d'un Kyste du Corp Wollf avec Pancreatectomie Partiale et Splenectomie," par Prof. A. Monprofit (d'Angers), *Gaz. Med. de Paris*, March 12, 1904.

hardly avoidable. When the neoplasm has been more median in position it has frequently been mistaken for an ovarian cystoma, and I think that Dr. Fitz's case is the only one that was diagnosed as pancreatic before being operated upon.

When it is possible these tumours should be removed. Although the operations were not easy, there were no important manipulative difficulties in my cases, and drainage of a multilocular cyst cannot be really curative. Moreover in several cases, including the first above recorded, the microscopic appearances of the growth were those of a carcinoma, for which nothing but complete removal can be of any use. The subsequent history of such cases is of much interest and I therefore hope to be able to record my patient's condition on some future date.

XXXIII.—*Case of Thrombosis of the Abdominal Aorta.*

By Francis H. Hawkins, M.D. *Read May* 25, 1906.

Martha P., æt. 56, a married woman with a grown-up family, was admitted into hospital under my care on May 3, 1904, complaining of "pain and numbness of the legs, with inability to walk."

Previous history.—Patient had rheumatic fever when seventeen years old and typhoid when she was thirty-nine, and she has on several occasions suffered from bronchitis. This patient was under my care as an out-patient in December, 1900, and from my notes made at that time I find she complained of "pains in the head, giddiness, and a feeling of pitching forward and reeling about when walking." She further complained of pains all over, especially down the right side and across the back. At that time she could walk. The heart was described as normal. Her last period was in June, 1900. I could not detect any evidence of actual disease and regarded the case as a "climacteric neurosis." Under treatment she improved, the pains subsided, and the last note made was, "Pains better, but patient states that she feels crippled from head to foot and does not gain strength." She subsequently ceased attending, and I saw nothing of her until her admission to the hospital.

History of present attack.—Four months previous to admission while standing at her work she was suddenly seized with cramp-like pain in her right leg; subsequently the pain became shooting in character and was so severe that she went to bed. During the time she was in bed pains, first cramp-like, then shooting, were felt in the left leg, but these pains were never so severe as those in the right leg.

After remaining in bed for one month, the pains having improved, patient got up and she could walk about, but during the last month she has not been able to walk without assistance.

On admission it was noted that the patient was a big, stout, fat woman, and on examination there was nothing abnormal in the appearance of the legs; the skin was of the ordinary colour, not unduly pale and not mottled. There was no œdema of the legs (and I may here remark that on

being asked the patient stated that she had never had any swelling of the legs and had never suffered from hæmoptysis). On palpation both legs were exquisitely tender, especially the calf of the right leg, and on firm pressure patient said we hurt her very much.

The knee-jerks were present and there was no ankle-clonus.

While lying in bed both the legs could be moved in all directions, the patient could stand without assistance, but she could not walk, though when supported on either side she could shuffle along for a short distance.

Heart.—The apex beat was normal in position, no murmur was heard, but the first sound at apex was short and sharp.

Urine.—No albumen.

Further notes.—The patient made no improvement; on the contrary, she became worse. The hyperæsthesia and analgesia of the legs became more marked. The patient frequently wept and was greatly depressed. On June 4th (one month after admission) about seven o'clock in the morning the patient called the nurse to her, saying that her legs had become quite numb and that she felt very ill. The house-physician was sent for, and one hour later when he again saw the patient the legs, which at seven o'clock were quite cold, were now quite pallid, having, as he described it, "a *post-mortem* appearance."

The lips were blue, hands cold, pulse at wrist feeble. Pulse in the femoral arteries could not be felt on either side. The patient now complained of a severe pain over the abdomen and she commenced to vomit. When I saw her later in the day she was still vomiting and the abdomen was greatly distended. The patient gradually became worse and died on June 5th at 7.55, about twenty-four hours after first feeling her legs becoming quite numb.

Necropsy (from notes by Mr. Thomas, house physician).—Rigor mortis well marked. Abdomen much distended, discoloration around the umbilicus. On opening the abdomen it was noted that the abdominal wall was very thick (fat). The intestines were distended, dark in colour, with many areas almost black. On incising mesentery the vessels were seen to be occluded.

Kidneys.—Capsules adherent, vessels engorged, early cirrhotic changes. Several recent infarcts in both kidneys.

Liver.—Discoloured (greenish) patches of emphysema under capsule.

Spleen.—Enlarged and hard, no infarcts.

Heart.—Left ventricle small, wall hypertrophied. The mitral valve is stenosed; the opening only admits the end of the little finger.

Aorta.—On palpation the femoral and iliac arteries felt firm, as also did the aorta at its bifurcation. On opening their arteries they were seen to be filled with a blood-clot which in the aorta extended up to the mesenteric arteries. Just above the bifurcation of the aorta a calcareous plate was seen on the posterior surface.

Remarks.—Several points of interest arise from this case. Firstly, was this a case of primary thrombus forming at the bifurcation of the aorta around or upon the calcareous plate? or was there originally an embolism lodging at the bifurcation and the thrombus of secondary formation? In favour of the latter view we have sudden onset of cramp-like pains in the right leg, the evidence of an old infarct in the right kidney, and the presence of mitral stenosis. In favour of the former view we have a gradual onset of pains in the left leg and a gradual appearance of weakness of the legs and inability to walk. Whichever view we may take we must, I think, conclude that the symptoms were due to the gradual formation of a thrombus, which finally produced complete occlusion of the aorta, and emboli as evidenced by the recent infarcts in the renal and mesenteric vessels, which latter caused death before gangrene of the extremities could supervene. Welch, writing on this subject, says that in fifty-nine cases of plugging of the abdominal aorta that he had collected mitral stenosis existed in twenty, and in classifying these cases he placed nearly all of those associated with mitral stenosis under embolism, but he adds: "I am not disinclined, in spite of the rapid onset of symptoms and frequently co-existent infarctions, to interpret many of them as primary thrombosis of the aorta." In only two or three of the cases was there any evidence of a thrombus in the left ventricle or the aorta above the plug, and he further adds: "An embolus large enough to occlude the lower end of the aorta could not pass through the contracted mitral orifice."

The second point of interest is, To what cause must we attribute the paraplegia, or weakness and inability to walk? On examining this patient, while I thought the symptoms pointed more to a peripheral than a central lesion, I came to the conclusion that it was neither, but that the condition was a functional one, although I was by no means satisfied with my conclusion.

We are, I think, still somewhat in the dark as to whether ischæmia of the cord or ischæmia of the peripheral nerves and muscles is the cause of the paraplegia in these cases, and I may perhaps again quote Welch on this matter. He writes: "There is no direct observation to support the opinion that the paraplegia following embolism or thrombosis of the abdominal aorta in human beings is caused by ischæmia of the cord, so that the old explanation which refers it to ischæmia of the peripheral nerves and muscles has the most in its favour." I regret the cord in this case was not examined.

The third point of interest is the mode of death. Apparently most of the patients suffering from occlusion of the abdominal aorta died from gangrene of the extremities; in only one of the 59 cases collected by Welch—a case described by Jurgens—was there hæmorrhagic infarctions of the intestines. In the 59 cases above referred to 30 were in females and 27 in males; the ages varied from one at nineteen to one at sixty-one, most cases occurring between thirty to forty and fifty to sixty. Dr. J. H. Bryant, writing on this subject in Allchin's *Manual of Medicine*, says: "There were only four in the Guy's Hospital Records spread over a period of forty-seven years," and regards it as an extremely rare condition.

XXXIV.—*A Series of Cases in which Pulmonary Embolism appeared to be due to the Displacement of a Thrombus in the Main Trunk of the Pulmonary Artery.*

By Charles R. Box, M.D. *Read May* 25, 1906.

THE interest of the seven cases which, by the courtesy of my colleagues at St. Thomas's Hospital, I am now enabled to report lies in the fact that they appear to exemplify a class in which the formation of a thrombus in the main trunk of the pulmonary artery is succeeded by embolism in the same trunk or in one of its primary subdivisions.

There is strong presumption that in most, if not all, of them a clot had formed in the pulmonary stem, and that this clot, becoming detached from its anchorage in the heart or vena cava, was carried towards the bifurcation of the artery, where, becoming coiled upon itself, it occluded the orifices of the main branches of the vessel. The process may be described as pulmonary embolism by a displaced pulmonary thrombus.

Judging from *post-mortem* room experience, an occurrence such as this cannot be exceedingly rare, and doubtless has been observed before. Yet little or no allusion to it can be found in the text-books in common use.

It is a matter of common knowledge that emboli can be derived from clots in the lumina of the iliac, femoral, or other veins, and the possibility and danger of such an occurrence after childbirth is universally recognised. The right cavities of the heart are also admitted as possible sites of origin for emboli, but the fact that an insidiously formed clot in the pulmonary artery, by becoming displaced, may suddenly induce all the appalling phenomena of pulmonary embolism is not generally recognised. In fact, the only references to this sequence of events which I have been able to find are as follows:

Bristowe, in his *Theory and Practice of Medicine*, writes that clots in the pulmonary artery "may form without pain, and cause little or no distress until, by some *displacement* of them or by the sudden coagulation of the blood still circulating between them and the walls of the tube where they lie, they suddenly bring the pulmonary circulation, and with that life itself, to a stop."

Dr. Newton Pitt (*Pathological Transactions*, vol. xliv),

when analysing cases of pulmonary thrombosis from the records of Guy's Hospital, found twenty-six cases of embolism of the pulmonary artery. Referring to these, he says, "In many cases the only evidence for calling the clots emboli was the belief that this was the orthodox view to take," and urges that all the evidence tends to show that many such clots are formed initially in the pulmonary arteries and should be labelled thrombi.

Dr. Aufrecht, in Nothnagel's *Encyclopædia*, makes the following statement: "Among other sources of emboli are to be considered the inner surface of the right heart and the pulmonary artery, with its main branches," but he goes on to add that "from the latter the thrombus has to be carried some distance before it is liable to lead to occlusion of the vessels."

To Playfair is due the credit for drawing attention to the frequency of pulmonary thrombosis as distinct from pulmonary embolism. His observations related mainly to puerperal cases, and he pointed out that pulmonary thrombosis occurs before the lapse of a fortnight after delivery, whilst embolism (from pelvic veins) does not occur until after the nineteenth day, the clot needing some time to become softened and detached.

A perusal of the cases of thrombosis related by Playfair leaves no doubt in my mind that some of them were of precisely the same nature as those now recorded, but his explanation of the onset of symptoms is different from the one now advanced. He says: "The history of many cases tends to show that the obstructing clot was present for a considerable time before death, and that it was only when some sudden exertion was made, such as rising from bed or the like, *calling for an increased supply of blood, which could not pass through the occluded arteries*, that fatal symptoms manifested themselves."

Further, it appears from his writings that Playfair believed all clots originating in the pulmonary artery to be "white, dense, and homogeneous, or firm at the periphery, and possibly softened at the centre." Consequently, he looked upon cases where the clot had a different appearance and was not laminated or uniformly decolorised as examples of embolism. This evidently landed him in a position of some difficulty, for he says: "It must be admitted that the anatomical peculiarities of the coagula will by no means always enable us to trace them to their true origin. In many cases emboli may escape

detection by their smallness or from the quantity of fibrine surrounding them."

My contention is that clots of the red and mottled variety can and do form in the heart and pulmonary stem during life. The following case may be cited in support of this view:

E. H., æt. 70, died three days after exploration of a left-sided renal tumour. The pulmonary artery was occupied by a considerable length of clot, which also extended into its finer branches. The clot was laminated and not adherent; it consisted of a central core, decolorised and softening, encased by a shell of darker and firmer coagulum. The surface of the latter was mottled with yellow patches. The clot was not coiled up in any way. The abdominal tumour was a left hydronephrosis, due to compression of the ureter by an abnormal renal vein. In this case the clot had evidently formed *in situ* and certainly was not of the laminated, decolorised variety.

The following are brief summaries of the clinical histories and the results of *post-mortem* examination of the cases, most, if not all, of which I regard as instances of pulmonary embolism succeeding pulmonary thrombosis. In each case the presence of a clot in the systemic veins, from which an embolus might conceivably be derived, was, as far as possible, excluded.

Case 1.—*Cellulitis of leg; pulmonary thrombosis succeeded by pulmonary embolism.*—M. M., æt. 50, a lighterman, was admitted to hospital on August 20, 1899, with cellulitis of the lower limb. The condition was treated by free incisions and the wounds were granulating well when, eighteen days later, and without warning, the patient had a convulsive fit, became cyanosed, and suffered with intense dyspnœa. The pulse became rapid and feeble, and death ensued fifteen minutes from the commencement of the seizure.

At the autopsy the head, neck, and shoulders were deeply cyanosed, and the veins of the head and neck much engorged. The air-passages were clear, but the lungs were engorged and œdematous. They showed no signs of infarction.

The heart was generally enlarged and thickly coated with fat. The right ventricle was opened before the heart was disturbed, and the incision prolonged into the pulmonary artery. A large clot was found coiled up in the main trunk of the latter, effectually blocking it. The clot was chocolate-coloured and tenacious; it was a little thicker than an

ordinary cedar-wood pencil, and of uniform colour throughout. Distally it extended into the terminal ramifications of the pulmonary vessels. The complete clot was 10 inches in length. It was in no way adherent to the vessel-wall, but, at the same time, was certainly of some standing. The supposition was that it had formed gradually in the pulmonary trunk and right ventricle and then, its cardiac end becoming detached, had become impacted in the pulmonary stem. The inferior vena cava, the iliac, and the femoral veins contained no clot at all, but the length of the pulmonary embolus may indicate that it was formed in one of these veins.

The myocardium was pale, somewhat mottled, and very friable. There were a few subserous hæmorrhages on the inner surface of the left ventricle. No clots in the heart.

The liver was slightly cirrhosed, the spleen large and soft, and the kidneys engorged. The brain with its membranes and vessels appeared healthy. The incisions in the right leg below the knee had either healed or were rapidly granulating up.

Case 2.—*Severe burns of abdomen, thighs, and genitals; pulmonary thrombosis followed by pulmonary embolism.*—R. A., æt. 45, whilst under the influence of drink, placed a lighted pipe in his pocket and fell asleep. He sustained extensive burns of the abdomen, penis, scrotum, and thighs. He was admitted to hospital on June 6, 1900, and five days later the burns were skin-grafted under ether. The operation took an hour, and the next morning the patient appeared quite well, but at eight the same evening, twenty-two hours after the operation, he was seized with severe dyspnœa, became collapsed, and died in ninety minutes.

At the *post-mortem* examination, on opening the right ventricle and the pulmonary artery, a firm and slightly decolorised clot was discovered just above the pulmonary valves. It was coiled up, and effectually blocked the artery. The clot when uncoiled measured nearly 4 inches in length, and was not quite ½ inch in diameter. The outer skin of the clot was firmer than the rest, and presented a mottled red and grey appearance. The clot was elastic and, when stretched, showed slight lamination. It was very firmly impacted in the pulmonary artery, but was not adherent to the wall. The cardiac valves were competent, the ventricles moderately dilated, and the myocardium friable and much mottled on its interior surface. The heart contained no clot. The lower

lobe of the right lung was very extensively infarcted, and presented a uniform, dark, jelly-like appearance. The other lobes were dense, short of air, and gorged with dark blood.

The liver was large and slightly congested. The kidneys were of a deep chocolate colour, swollen, resilient, and full of blood.

The wound area appeared quite healthy, and there was no thrombosis of the iliac or pelvic veins.

The brain was unduly firm, and the circle of Willis slightly atheromatous.

Case 3.—*Typhoid fever; sudden death from pulmonary embolism, the sequel of pulmonary thrombosis.*—E. B., a female, æt. 21, was admitted in November, 1900. She had been ailing eighteen days and had taken to bed for a week. She went through a smart attack of typhoid fever with high temperatures. There was no hæmorrhage from the bowel. On three separate occasions the serum reaction for typhoid was doubtful, but the typical bacilli were afterwards isolated from the urine.

At the end of three weeks, when the temperature was already nearly normal, an attendant attempted to lift the patient from her bed, to facilitate which the patient placed her arms round the attendant's neck. The result of this effort was that the patient almost instantaneously expired.

At the autopsy typical typhoid ulceration was found in the lower eighteen inches of the ileum and was particularly extensive just above the ileo-cæcal valve.

The right ventricle of the heart was empty, but the pulmonary artery was firmly plugged by a firm clot which extended through its main subdivisions onwards into the lungs. The proximal end of the clot, lying just beyond the pulmonary valves, was doubled on itself for nearly an inch and firmly impacted. The condition was thought to have been brought about by a primary pulmonary thrombosis, the coagulum extending into the right ventricle and by a forcible contraction becoming detached and driven on into the pulmonary trunk. The clot was red throughout, but its surface was mottled with paler patches where it was becoming decolorised. It was not adherent to the artery. There was no separate embolus in the clot and no source of embolism could be detected anywhere in the body.

The lungs were œdematous, but not in any way infarcted or consolidated.

The liver and kidneys showed the ordinary appearances of cloudy swelling and the spleen was large and soft.

Case 4.—*Diabetes mellitus; pregnancy; pulmonary embolism following pulmonary thrombosis.*—S. S., a female æt. 37, was admitted to hospital on December 6th, 1905. For four months she had noticed symptoms suggestive of diabetes, namely emaciation, polyuria, and intense thirst. She was six months pregnant with her sixth child. The amount of sugar passed whilst under observation varied considerably, once reaching a maximum of 4000 grains in a day. Reactions indicating the presence of diacetic acid and of acetone were sometimes present, sometimes absent. The treatment consisted of codeine and a modified diabetic diet.

On the morning of January 6, a month after admission, she was noticed to be rather cyanosed and inclined to be drowsy. The same evening, whilst having a bath, she suddenly complained of faintness, developed extreme dyspnœa, and died in fifteen minutes.

At the autopsy a little regurgitated food was found in the air-passages. The right side of the heart and the pulmonary artery, the stem of which was collapsed and flattened, were opened *in situ*. In the distal portion of the main pulmonary trunk, immediately below the bifurcation, lay a coiled mass of clot. This when extracted was found to have extended into the terminal ramifications of the artery and in all had a length of fifteen inches. The diameter of the thick end was nearly half an inch. The clot was firm and red, but its surface was mottled with buff-coloured patches. Part of the clot extended into the left pulmonary branch and part into the right; the portion in the latter was doubled on itself and firmly wedged in.

As no source for the clot was found in the pelvic or other veins it was assumed that it had formed in the pulmonary trunk and the right heart, but had become shifted during the exertions of the bath which preceded death.

The lungs were dark-coloured, but not infarcted. The heart on further examination proved healthy in all respects.

The liver was of full size, dark, oily-looking on section and friable. The spleen was large, dark, and soft. The kidneys were deep red and moderately swollen; pelves and ureters a little dilated. Pancreas, thyroid, and adrenals normal. The pregnant uterus occupied the greater part of the belly; it showed nothing abnormal. The brain was healthy.

Case 5.—*Operation for radical cure of inguinal hernia; pulmonary embolism following pulmonary thrombosis.*—A. R., æt. 44, an iron turner, was admitted to hospital February 9, 1906. He had a small left inguinal hernia which followed a strain and was of about a week's duration. On February 13, under ethyl chloride and ether, an operation for radical cure was performed. The wound healed by first intention. Six days after operation the patient, who was still on his back, but had been singing and applauding a performance in the ward, suddenly sat up, complained of great pain in his heart, and vomited. He experienced a severe choking sensation and became dyspnœic and dusky in colour. In twenty minutes he was dead.

At the *post-mortem* examination the heart was examined *in situ*. The right ventricle was empty and when the incision was prolonged into the pulmonary stem a much coiled clot was found impacted at the bifurcation, extending into each main branch. The clot was a little stouter than an ordinary cedar-wood pencil; its surface was mottled, red, and grey; its consistence was firm, but on section it was found to be softer in the centre, the softened part being enclosed in an outer, firm shell. It was not adherent to the vessel wall. One end was somewhat expanded and the moulds of the semilunar valves could easily be recognised here. The clot had evidently become dislocated from the main pulmonary trunk and had terminated life by a process of embolism.

Further examination of the heart showed that it was uniformly enlarged and the myocardium very friable. The valves were competent, but there were a few patches of atheroma in the anterior mitral curtain.

The lungs were gorged with dark blood, but not infarcted. The apices contained some small calcareous nodules and were adherent.

The liver was fatty and soft, the spleen firm, dark red, and rather large. The kidneys were of cardiac type, being purple, tough, and slightly swollen.

Careful investigation failed to disclose any thrombosis of the internal or external iliac veins or of the inferior vena cava.

Case 6.—*Operation for radical cure of inguinal hernia; pulmonary embolism following pulmonary thrombosis.*—F. F., æt. 46, house painter, was admitted to hospital February 14, 1906. An easily reducible but gradually increasing hernia in the right groin had been noticed for five months. On

February 21, under ethyl chloride and ether, an operation for radical cure was performed. Seven days later the stitches were removed, the wound having healed by first intention. At 6.15 next morning the patient was seized with faintness and dyspnœa. He became restless and broke out in a cold sweat, but was not convulsed. The condition became rapidly worse and death occurred sixty minutes after the seizure. The temperature, which was 95° F. at the commencement, ran up to 103·2° F. and the pulse became much accelerated before death.

At the autopsy the heart was examined *in situ* before anything was disturbed. The right ventricle was relaxed and the pulmonary trunk empty, but just below the point of bifurcation of the vessel lay a mass of tangled clot. The proximal piece of this was about an inch long and five eighths of an inch in diameter; this was separate from the rest. It was succeeded by a long clot which was tightly packed into the orifice of each main branch of the artery and folded on itself. Both portions of the clot were old, being encased in an outer tenacious skin whilst the interior was softer. The outer surfaces were mottled red and grey and not at all adherent to the vessel-walls.

The incision in the ventricle was carried on into the superior vena cava and its tributaries. There was no clot in these. The incision was also carried downwards along the inferior cava and on into the iliac and femoral veins of each side. There was no vestige of clot in any of these vessels. The internal iliac and the pelvic veins were similarly free from clot. It appeared probable that the impacted clot had been dislodged from the pulmonary stem and the right ventricle and had become broken, thus accounting for the two pieces.

The heart was further examined after removal. It contained no clots. The valves and coronary arteries were healthy, but the myocardium was yellowish and friable. The liver was pale and soft. The spleen was large, firm, and deeply congested. The kidneys were not large but were firm and purple like those of old-standing heart disease. All other viscera were healthy.

Case 7. *Malignant disease of cardiac end of stomach; ascites; exploration of abdomen; pulmonary thrombosis followed by pulmonary embolism.*—E. G., female, æt. 61, came under observation for ascites of doubtful origin. An exploratory

incision revealed the presence of diffuse malignant disease, so after evacuation of the fluid the abdomen was closed.

The patient's progress was apparently quite satisfactory until the twelfth day after the operation, when she suddenly gave a little cry and fell back in her bed dead.

Post-mortem examination.—The body was extremely emaciated. The mouth, fauces, larynx, pharynx, trachea and œsophagus were normal. There were a few pleural adhesions at each apex and the scars of past tuberculosis.

The heart was examined *in situ*. The right ventricle was flabby and the pulmonary stem collapsed. On incision a little red blood escaped. The first part of the pulmonary artery was empty, but just proximal to the bifurcation lay a tangled mass of reddish clot. When extricated this was found to consist of two pieces, but they evidently formed parts of the same thrombus. The clot was about the thickness of an ordinary cedar-wood pencil and was enclosed in a firm outer skin which was mottled and dry; the interior was deep red. The two pieces together measured four and a quarter inches in length. They quite occluded the pulmonary stem and reached a short way into its main branches. Beyond the clot the pulmonary arteries were empty. At the base of the right lung was a small hæmorrhagic area. This lay at the periphery and was not wedge-shaped.

The peritoneum, both visceral and parietal, was infiltrated with small nodules of new growth. The primary growth was in the stomach wall near the cardiac orifice. Externally this appeared as a puckered scar whilst internally it formed a more or less circular elevation the size of a florin. It was not ulcerated. There was no evidence of implication of the thoracic duct or supra-clavicular glands. Neither the superior nor inferior cava, nor yet the iliac or femoral veins, showed the slightest trace of thrombosis.

In each of these cases the onset of symptoms was sudden and characteristic of embolism rather than of thrombosis. In none of them, before the fatal seizure, was there any obtrusive evidence of the presence of the pulmonary clot which when dislocated caused death.

I say obtrusive evidence because there is reason to believe that, in some cases at all events, the presence of such latent thrombosis may be recognised. The *premonitory signs*, upon the recognition of which the patient's life may depend, are the development of a systolic basic murmur in the

pulmonary area, as pointed out by Walshe and Playfair, an undue acceleration of the pulse, and in some instances the presence of slight cyanosis and dyspnœa.

The basic murmur is not always present. No doubt it is due to the presence of clot in the pulmonary orifice. The murmur is harsh and systolic. A diastolic murmur has not been recorded in this condition, for in all probability the closure of the semilunar valves on the sides of the clot is sufficient to prevent regurgitation. In Case 5 the impression of the valves could easily be recognised on the clot which was extracted from the point of bifurcation of the pulmonary trunk. In a case of pulmonary thrombosis, secondary to ear disease, which occurred in St. Thomas's Hospital in 1902, and which I had the opportunity of examining *post-mortem*, the development of a harsh systolic pulmonary murmur was noticed during the progress of the affection, and after death pulmonary clot was found which extended from the right ventricle through the valves into the artery. I have not included this case with those now reported because it does not illustrate the process of secondary embolism with which this communication is concerned.

If the pulmonary clot is sufficiently extensive to reach through the tricuspid orifice into the auricle, which at times it does, a tricuspid murmur might conceivably result. In one of the cases reported by Playfair a loud systolic murmur was heard at the junction of the fourth and fifth ribs with the sternum. In this case with the subsidence of the dyspnœa the murmur disappeared. The patient ultimately succumbed, but no *post-mortem* examination was obtained.

It has been pointed out by the older writers on thrombosis that acceleration of the pulse-rate often accompanies thrombosis of veins at the periphery of the body. When the pulmonary artery is in part occluded we should also expect this acceleration to occur. Only one of my cases affords any evidence bearing on this: in the patient with typhoid fever the pulse-rate was charted and a decided quickening was noticed for a day or two before the fatal issue.

Again, when the lumen of the pulmonary artery is to any degree narrowed owing to the presence of a thrombus, it is probable that the limitation of the blood-supply to the lungs will produce a moderate degree of dyspnœa and possibly cyanosis in addition. In the case of the patient with diabetes the presence of slight cyanosis was particularly noticed on the morning of the day on which the fatal event occurred. If the

significance of this sign had been rightly understood, precautions might have been taken which would have prevented the appalling accident which occurred later. There is also recorded in Vol. XIII of the Obstetrical Society's *Transactions* a case of apparently simple pulmonary thrombosis in which the face assumed a livid purple hue.

An analysis of the symptoms presented *after the embolism has occurred* shows that in two cases death was practically instantaneous and that in all the others dyspnœa, usually accompanied by more or less cyanosis, was the prominent symptom. In addition, severe cardiac pain was experienced in one case and the onset accompanied by vomiting, whilst in another there was an initial convulsion. Later on signs of pulmonary infarction may arise.

The mechanism of these symptoms offers interesting matter for speculation. In those cases where death is absolutely sudden and also in those where it is so nearly instantaneous that the patient has barely time, before the fatal issue, to exclaim, to borrow Aufrecht's phrase," I choke! I die!" the end is due to syncope. This is probably brought about by the complete blockage of the pulmonary trunk and consequent cessation of cardiac action. But it is also possible that it is due to reflex cardiac inhibition. Drs. Russell and Brodie performed a series of experiments with the object of ascertaining which of the afferent fibres of the vagus nerve are most potent in causing reflex stoppage of the heart. They found (*Journal of Physiology*, vol. xxvi, 1900–1901) that in this respect the effect of stimulation of the pulmonary fibres was much more decided than that of the cardiac fibres themselves. Stimulation of the pulmonary branches at the root of the lung caused typical arrest of ventricular contraction, arrest of respiration, and inhibition of the vasomotor centre, with considerable fall of blood-pressure. Dr. Russell has applied these experimental results to explain those cases in which sudden death has followed exploratory puncture of the lung (*St. Thomas's Hospital Reports*, 1899). A difficulty in the application of the same explanation to the sudden death induced by pulmonary embolism lies in our scanty knowledge of the innervation of the pulmonary trunk. According to Quain, the anterior pulmonary plexus is formed by the union of two or three anterior pulmonary branches of the vagus with filaments of the sympathetic ramifying on the pulmonary artery. Whether a reflex sufficient to cause cardiac inhibition can be originated from the pulmonary artery is open to question.

Whether the cessation of cardiac action is due to mechanical obstruction of the pulmonary trunk or to reflex action originating at the point of impaction, the result is the same: the cerebral circulation is brought to a sudden standstill, and death is practically instantaneous. Both Panum and Paget, many years ago, suggested that the cause of death in some cases was cerebral anæmia.

The dyspnœa, which is by far the most prominent symptom in cases which are not at once fatal, admits a direct mechanical explanation. It is peculiar in that it co-exists with an absolutely free entry of air into the lungs and so is obviously of circulatory origin. It is due to diminution and ultimate cessation of the circulation through the lung, caused by the presence of the embolus and the extension of thrombosis into the remoter branches of the pulmonary artery. I am aware that most writers on the subject of pulmonary thrombosis assume that the thrombotic process begins in the small branches and extends backwards into the larger ones. I am inclined, from the character of the clots in the cases which I have observed, to take the opposite view. As a rule I have found the terminal clots to be red, gelatinous, and recent, whilst the coiled clot in the occluded main trunk was obviously older. I find that the same view as to the direction of extension of these clots has already been advocated by Drs. C. J. Martin and G. E. Rennie in a suggestive contribution on cardiac thrombosis which appeared in the *Lancet* of September 16, 1899. These authors point out that the churning movements of the cardiac contractions, aided by the high carbonic acid tension of the blood before it is aerated in the lungs, are admirably adapted to favour thrombosis in the right ventricle and pulmonary artery, should any coagulants of the nature of nucleo-albumens have found access to the blood-stream.

Patients who survive the first shock of the embolism complain chiefly of dyspnœa and may develop a considerable degree of cyanosis, as noted in Cases 1 and 5. These patients ultimately appear to die of asphyxia, whilst those who die from syncope at the first shock of embolism may be quite pallid.

The pulse, when there is opportunity to observe it, is found to be feeble and accelerated. The same applies to the heart sounds.

Cardiac pain was experienced in one instance. It is well known that arterial embolism is associated with severe pain at the point of impaction and presumably the occurrence of

such pain in the region of the pulmonary artery should afford valuable confirmatory evidence of what has occurred. Although pain of this character is only explicitly described in one of this series of cases, I cannot help thinking that it should be more constant than the case records lead us to infer. Not only is the pain referred to the neighbourhood of the pulmonary artery in embolism, but when the embolism is unilateral the pain may be strictly unilateral too, as occurred in a case which came under my observation, where pulmonary embolism followed thrombosis of the internal iliac vein. The pain in this case was solely referred to the side of the chest on which a plug was found in the main subdivision of the vessel. The pain, when it occurs, is of sudden onset and appears to be due to forcible stretching of the vessel walls. There is no evidence that simple pulmonary *thrombosis* is ever accompanied by pain of this nature. Of course, should it turn out that the pulmonary artery really has no nerves of any kind distributed to it, this explanation becomes untenable.

The occurrence of initial convulsions in one instance is a point of the greatest interest. In cases where gradually increasing dyspnœa and cyanosis terminate in asphyxial death the occurrence of convulsions might be expected. I have never met with a case of this sort. Marked convulsions similar to those noted in one instance were observed by Dr. Russell in one of his cases of death after exploratory puncture of the lung. He attributes them to cerebral anæmia. Cannot the same explanation be given of the initial convulsions and vomiting of pulmonary embolism ?

Time will not permit discussion of pulmonary infarction in the present paper. I will, therefore, content myself with recalling to you the fact that there is experimental evidence that the nutrition of the lung can be fully maintained by collateral circulation through the mediastinal, pericardial, and bronchial arteries when the pulmonary artery has been completely occluded by aseptic clot or by a foreign body purposely introduced. Besides this, there is clinical evidence that when the pulmonary artery has become gradually occluded by thrombosis or by new growth, no extravasation of blood into the lung-tissue need occur. Dr. Newton Pitt published some reflections on this subject in a suggestive paper which he contributed to the *Transactions* of the Pathological Society in 1899.

In only one of the cases now recorded was extensive pulmonary infarction present, and this was in the patient who survived the embolism for the longest period—*i. e.* ninety

minutes. In the patient who survived the accident sixty minutes the posterior parts of the lower lobes were encased in a narrow shell of congestion and partial collapse, and in the lung of one of the patients who died instantaneously a small hæmorrhagic area was found near the base of the right lower lobe. In the remaining four cases the lungs were either œdematous or slightly congested.

In cases where thrombosis or embolism of the pulmonary artery is suspected it is essential that the examination of the artery and of the right cavities of the heart should be effected before the thoracic viscera are removed or in any way disturbed. The method of examination adopted in the latter cases was as follows:

After opening the pericardial sac an incision was made in the front of the right ventricle near its apex. The opening was carefully prolonged into the pulmonary trunk by blunt-pointed scissors. By this method the condition and relations of the clot in the pulmonary artery were determined before there was any opportunity for displacement to occur. The ventricular incision was next prolonged through the tricuspid ring and wall of the right auricle into the superior vena cava, innominate veins, and their chief tributaries.

The intestines were next removed and the liver split vertically to expose the inferior cava. That vein was laid open from its cardiac orifice to its bifurcation, and the incision continued along the internal iliac trunks and also along the external iliac and femoral veins, and so on.

By this method all the large veins and their tributaries are exposed without unnecessary disturbance, and any peripheral source of a large embolus is unlikely to be overlooked or inadvertently mutilated.

It is particularly important to investigate the pulmonary artery before the thoracic viscera are interfered with, for it is conceivable that, during the removal of the thoracic contents, a pulmonary clot might become displaced or even, by virtue of its elasticity, slightly coiled up when its cardiac connections are ruptured.

The treatment of these cases falls naturally under two headings:

(1) Prophylaxis.

(2) The management of the patient after embolism has occurred.

With regard to prophylaxis it is evident that the most important indication is to absolutely forbid any muscular exertion in any of those conditions which are known to be associated with a tendency to the insidious formation of thrombi in the right cavities of the heart and the stem of the pulmonary artery. Amongst the conditions in which this complication is likely to occur may be enumerated the following:

Surgical operations, especially when accompanied by profuse hæmorrhage or prolonged anæsthesia.

The puerperal state, particularly when, for any reason, childbirth has been accompanied by severe bleeding.

Phthisis when associated with severe hæmoptysis.

All septic conditions, particularly septic peritonitis.

Acute pneumonia.

Acute rheumatism.

Typhoid fever.

Conditions of enfeebled circulation with fatty heart such as occur in alcoholics.

The second element of prophylaxis consists in the administration of anti-coagulants. The preparations of iron and of ammonia have long had a reputation in this respect. Richardson advocated the administration of liquor ammoniæ in doses of 20 minims every hour.

More recently Sir A. Wright has urged the claims of citric acid, and observing that the increased coagulability of the blood in patients convalescing from typhoid fever is accompanied by an excess of lime-salts, has advocated the decalcification of the cow's milk used as a diet in that disease by the addition of from 20 to 40 grains of citrate of soda to each pint.

As Professor Warrington Haward suggested in his Hunterian Lectures on phlebitis and thrombosis, the decalcification method is also applicable to other diseases and conditions than typhoid fever.

Since oxygen has also been proved to act as an anti-coagulant, the adoption of methods calculated to improve the circulation of blood through the lungs and also the provision of liberal supplies of fresh air also deserve attention. The beneficial effect of cardiac tonics, such as strychnine and digitalis, may be mentioned in this connection.

When embolism has occurred it appears inadvisable to attempt to relieve the dyspnœa by artificial respiration, as is often done. The forced movements may even disturb the

clot and make matters worse. Rather we should rely on the administration of oxygen, the subcutaneous injection of strychnine and free dosage with some rapidly diffusible stimulant such as ether and ammonia mixture. Injections of morphia may also be used.

Although many cases are fatal, it cannot be denied that recovery occurs occasionally, even after the development of the most urgent symptoms.

XXXV.—*Acute Dilatation (Acute Atony) of the Stomach and Intestines connected with Pneumonia and Pleuro-pericarditis.* By F. PARKES WEBER, M.D., F.R.C.P. *Read May* 25, 1906.

THE patient, Florence W., was a delicate-looking young woman, æt. 21, a mantle-maker in London. She was admitted under my care at the German Hospital on June 15, 1905, soon after the commencement of pleuro-pneumonia. According to the history the lung trouble began with cough and pains in the chest two days before admission, but she

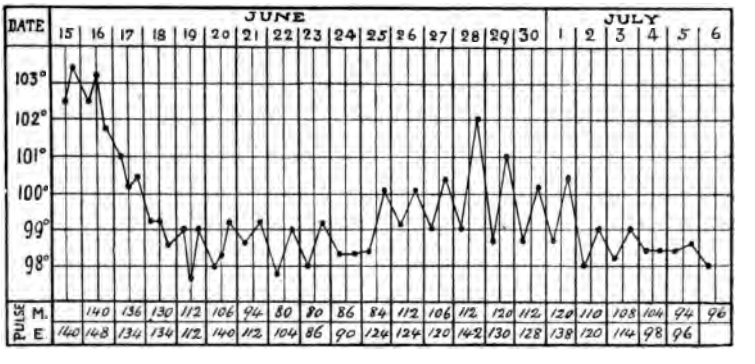

was said to have had diphtheria six weeks previously, and to have suffered since then from want of appetite, belching up wind, lassitude, and palpitation. She had previously often suffered from cough in winter, but had never had hæmoptysis.

On admission there was some shortness of breath, slight meteorism, and considerable fever (see temperature chart). Pulse 140, small and weak. Respiration 32. Examination of the chest showed impaired resonance, diminished breath sounds and crepitations at the base of the right lung behind; there were likewise scattered dry sounds. In the cardiac area to the left of the sternum a little friction was heard. Nothing else abnormal was noted in the thorax and abdomen. The urine gave a faint reaction for albumen.

During the course of June 16 the meteorism greatly increased, and when I saw her, at about 11.45 a.m. on the

following day (June 17), the condition looked grave. The belly was much distended and tympanitic all over and there was no movement of the abdominal wall with respiration. Percussion showed extreme upward displacement of the heart and liver. There were crepitations over the front and back of the left lung and dulness below the spine of the scapula. The heart sounds were accentuated. No pericardial friction was noted. The face was pale and only slightly cyanotic. Pulse 130, regular. Respirations 38. There was an expiratory, wheezy sound to be heard at the patient's mouth. No flatus had been passed, but a glycerine enema had been followed by a motion of small, hard scybala.

The stomach was washed out by a syphon-tube and much blackish material came away; some was vomited around the tube. The stomach-contents had a sickly smell and an acid reaction; they apparently contained no free hydrochloric acid; the guaiac reaction was positive, yet much of the blackish appearance may have been due, not to blood, but to some red wine which the patient had been given. She felt great relief even whilst the gastric lavage was in progress, but the tympanites did not immediately disappear, proving that the stomach was not the only part of the alimentary canal affected and that the condition was partly due to intestinal distension. Afterwards a watery motion was passed containing blackish material similar to that brought away from the stomach. The patient was then ordered to have temporarily nothing by the mouth excepting ice-pills, and she was given hypodermic injections of camphor (in oil) and of liquor strychninæ hydrochloridi (two minims). On June 18 she was free from fever, but over the upper part of the right front of the chest there was much crepitation. She was then fed with nutrient enemata, and five drops of liquor strychninæ hydrochloridi in water were prescribed to be given by the mouth three or four times daily. During the night of June 18 the meteorism diminished, and on the evening of June 20 there was none noticeable; the liver dulness was then natural. About this time it was remarked that the patient slept very much during the day as well as during the night. Some crepitation at the base of the left lung was heard on June 19, and a pericardial rub was likewise noted. The pulse was 108 and the respirations 24 in the minute. On June 22 pericardial friction was distinct over the lower part of the sternum, on June 28 the friction could be heard all over the cardiac area, and on the following day the præcordial dulness

was found to extend a little to the right of the sternum. About this time there was again some fever (see chart).

On July 6, however, friction was no longer present, and I could find nothing abnormal in the thorax excepting some impairment of resonance in the right infra-scapular region. The patient's general condition was good, excepting that about this time there was a state of peculiar mental depression, which soon passed off again. The diet had been gradually amplified, and the patient had likewise been given some digitalis, and later on citrate of caffein. In the latter part of July the pulse varied between 64 and 96, the patient was allowed to be up in the ward, and albuminate of iron was given as a medicine. There was, however, no very decided anæmia, for on June 28 a blood-count had given 4,480,000 red cells and 35,600 white cells in the cubic millimetre. During the first two weeks of August the pulse varied between 54 and 92, and when I examined her on August 14 I found nothing abnormal in the chest. She had gained weight and thought she was again in her ordinary state of health. In November, 1905, I saw her again. She then looked well, and I could find nothing wrong in the thorax or abdomen, but she was apparently often troubled by feelings of indigestion and globus-like sensations.

Remarks.—The case presents certain features which I think merit attention. It was certainly not one of the severest examples of acute dilatation (acute atony), and there was none of the spontaneous vomiting of enormous quantities of fluid characteristic of typical cases. It might perhaps be more correctly termed "acute atonic gastro-intestinal tympanites." Yet at first her condition appeared alarming enough to give rise to some anxiety as to possible bad effects of attempting to pass an œsophageal tube. There was a definite history that after the so-called diphtheria, six weeks before admission, the patient had been troubled with a tendency to bring up wind. She herself told us that when ill at home just before coming to the hospital she had been able to eat nothing at all, whereas on admission to the hospital, for some reason or other, she could take more food. She was given fluid diet, with two eggs, somatose, and a little wine, as well as digitalis as a medicine. At the same time she lost the power of belching up wind. This probably marked the commencement of the atony of the gastro-intestinal musculature. The acute abdominal distension followed, and this was clearly not entirely confined to the stomach, for the tympanites did not immediately disappear after the lavage of the stomach. In

spite, however, of the persistence of intestinal meteorism the effect of the gastric lavage was most encouraging, and it obviously gave the patient a certain amount of immediate relief. In all probability the increased amount of food taken on admission to the hospital helped to set up the condition of dilatation in this debilitated patient suffering from pleuro-pneumonia. Of forty-four cases of acute dilatation of the stomach analysed by H. Campbell Thomson in his monograph* on the subject only three were connected with pleurisy and pneumonia and one with empyema, against sixteen following operations or injuries. In the present case the so-called "diphtheria" (?) from which the patient suffered some weeks before the onset of the pleuro-pneumonia may have acted as a predisposing cause by inducing a condition of debility. The constipation may likewise have played a part in the causation of the gastro-intestinal distension.

It is obviously more correct to speak of "acute atony" or "acute atonic dilatation" of the stomach than to use the term "acute paralytic dilatation" when speaking of a temporary condition such as occurred in the present case. This condition may be compared to the atonic dilatation which has been noticed in other abdominal viscera. Thus, at the other end of the alimentary canal, atony gives rise to the well known "ballooning of the rectum*"; in the uterus acute atony occurs in the form of "paralysis of the non-gravid uterus," which has sometimes disagreeably complicated the operation of curetting and about which a good deal has been written; in the urinary bladder temporary acute atony has likewise been recorded (Geyl noted it in connection with the removal of two polyps from that organ†).

* *Acute Dilatation of the Stomach*, London, 1902.

In regard to the occurrence of "ballooning of the rectum" and of "atonic dilatation of other viscera" three factors have to be considered, viz. (1) the pressure within the viscus, (2) the pressure without the viscus, and (3) the atony of the unstriped muscle in the wall of the viscus. In ballooning of the rectum excessive intra-rectal pressure cannot be considered a necessary factor, for if it were so the rectum would collapse when the anus is held open. The other two factors are *both* required for the production of "ballooning"; atony of the rectal musculature can give rise to "ballooning" only when, owing to the position of the body, or otherwise, the external pressure is negative. With considerable pressure from without the rectum would collapse in spite of atony.

† This observation in regard to the urinary bladder (to which my attention has been kindly directed by Dr. L. Fellner) is recorded by Geyl in his note on "Paralysis of the Uterus during Curetting" in the *Archiv für Gynäkologie*, 1887, vol. xxxi, p. 376. "Paralysis of the non-gravid uterus," it seems to me, might almost be termed "ballooning" of the uterus.

Whether excessive or dangerous dilatation is or is not associated with a temporary acute atony of any hollow abdominal viscus must depend largely on the amount of pressure within the viscus during its period of atony. Thus, it is obvious that relative overfeeding, combined or not with constipation or with excessive fermentative changes in the gastro-intestinal contents, may constitute an important factor in the production of acute dilatation of the stomach and intestines. It is equally obvious that lavage of the stomach, though it probably cannot immediately remove the condition of muscular atony which underlies the dangerous acute dilatation, must do good both by relieving the intra-gastric pressure and by washing away fermenting and irritating contents.

Perhaps some further light will be thrown on the subject of acute atony of the stomach and its connection with pleurisy by investigations into the exact motor innervation of the muscular abdominal viscera, similar to the studies which have already helped to explain the occurrence of "paralysis of the non-gravid uterus" during the process of curetting that organ (L. Fellner,* etc.)

* See also Dr. L. Fellner's earlier work on the "Innervation of the Rectum," *Med. Jahrbücher der k. k. Gesellschaft der Aerzte Wien*, 1883, p. 571, and *Archiv für die ges. Physiologie*, 1894, vol. lvi, p. 542.

CLINICAL CASES

EXHIBITED.

*** Published in accordance with the regulation relating to the exhibition of patients at the meetings of the Society, viz. that each case shall be accompanied by a brief written description of the points it illustrates; such description to be published or not in the *Transactions* as the Council may direct.

I.—*Case of Mediastinal Dermoid.* By G. E. O. Williams (introduced by Batty Shaw, M.D.). *Exhibited October* 27, 1905.

M. M—, æt. 26, was admitted to University College Hospital in June, 1905, complaining that for the previous three months she had been very much troubled with cough, and had brought up "pink" expectoration. In addition she had lost weight, and so feared that she had "consumption."

On closer inquiry she admitted that she had had a "weak chest" all her life, and cough had been troublesome for the last eight or nine years. She also volunteered the statement that she frequently found that hair came up into the mouth, sometimes with the expectoration, sometimes independently: this has occurred several hundred times during the last seven or eight years.

When twelve years of age she was treated at the North-Western Hospital for *left*-sided pleurisy: exploratory puncture was performed and some fluid was removed.

Physical examination of the chest shows that there is some prominence of the front of the chest to the *right* side of the sternum. The percussion note is dull over the upper part of the right chest as far down as the fifth rib, and reaching from the sternum to the anterior axillary line on the right side. The breath sounds are greatly reduced above and below the right clavicle, and almost absent in the second, third, and fourth spaces. Behind there is only slight impairment of percussion note internal to the lower part of the right scapula, the breath sounds being a little weaker than normal at the right apex.

No adventitious sounds are heard anywhere. The temperature whilst in hospital did not exceed 99°. There is a slight suspicion of clubbing of the fingers. The sputum is whitish in appearance, and is free from tubercle bacilli.

Radioscopic examination shows a shadow over the dull area above indicated, which is lost on its inner side in the shadow of the sternum and vertebral column.

Hair was expectorated on two occasions during her stay in the hospital.

II.—*Three cases of Submucous Excision of Deviations and Spurs in the Nasal Septum.* By StClair Thomson, M.D. *Exhibited October* 27, 1905.

THESE three cases are samples of several which have been operated on in the following method:—An incision is made through the mucous membrane, inside the columella of the nose, and parallel to it. Through this incision the muco-perichondrium is separated all over the convexity. The cartilage is then cut through, a little in front of the original incision, but without incising the muco-perichondrium of the opposite side. The mucous membrane and perichondrium is separated from the concave side of the deformity. The deviation, thus freed on both sides from its mucous covering, is cut out; any bony spur is chipped or chiselled away, and the two mucous membranes are allowed to fall together. The original incision is then closed by one or two stitches.

Healing is rapid, there is no formation of crusts, the nose

is left with an intact mucosa, and the result is always satisfactory and permanent.

Case 1. Man, æt. 17, says he could breathe freely through nose before receiving blow five years ago. There was a large deviation, with a long ascending spur on it so completely blocking up the right nostril that he was quite unable to inspire through it. Mouth breather at night. Operation was done on June 3rd, 1905.

Case 2. Man, æt. 25, trouble with nose for five years. Complained of bleeding and crusting in nose, obstruction of left nostril, inability to lie on right side, and mouth breathing at night. There was a large concavity of the right side of septum, showing a crusted, bleeding ulcer. Through the left nostril he could only inspire a trifling amount owing to large deviation and long spur.

Case 3. Man, æt. 32, complained of winter cough and expectoration, and mouth breathing at night. He showed typical adenoid facies, a high, narrow nose, high-arched palate, and crowded teeth. A small amount of adenoids was removed. The left nostril almost completely occluded by deviation and spur. Now sleeps with his mouth closed, and so far has had no winter cough. The operation was done on June 21st, 1905. The fleshy septum is still seen to quiver when the patient inspires quickly.

III.—*Cases of Recovery, without Spinal Symptoms, after Severe Injury to the Neck.* By Edred M. Corner, B.C. *Exhibited October* 27, 1905.

Case 1. *Fracture of the pedicles of the axis.*—This case with skiagraph was shown at a meeting of the Society on January 22nd, 1904. The accident was the result of rolling out of his chair whilst sleeping on Sunday afternoon. He never had any paralytic symptoms. The lesion was demonstrated in a skiagraph. Since being shown here, he has

recovered full power of movement of his neck, and began driving his cab again twelve weeks after the accident.*

CASE 2. *Fracture of the body and pedicles of the fifth cervical vertebra.*—This case with skiagraph was shown at a meeting of the Society on January 22nd, 1904. The accident occurred during a gymnastic display on the stage. There never were any paralytic symptoms. After he had recovered from the accident he complained of some obscure and painful sensations in the back of his shoulders and down his left arm. Since being shown he has resumed his occupation as a professional acrobat, but still complains of pain at the back of the left shoulder.*

CASE 3. *Rotatory dislocation of the atlas.*—This case with skiagraph was shown at a meeting of the Society. He was thrown from his horse, but was only slightly concussed and rode home. There were no paralytic symptoms. His head is still turned to one side, but he has to some extent recovered the power of movement. From an examination of the skiagraph at the meeting at which he was first shown it was generally thought that there was no fracture of the odontoid process.†

CASE 4. *Subluxation of the atlanto-axial joint.*—This case is that of a boy thirteen years of age who hurt his neck whilst diving. His head was rotated to one side, and his neck was stiff, painful, and immovable. He was seen a month after the accident, and had never had any paralytic symptoms. Reduction was easily accomplished under an anæsthetic. The boy wore a poroplastic collar for a week or so, since when he has completely recovered all his movements, so that it would be impossible to know that he had received a severe injury to his cervical spine.

CASE 5. *Lateral fracture of the axis.*—A man of fifty years of age was thrown from his horse on to the top of his head. There were no paralytic symptoms. The injury took place about seven years ago. He has now recovered full movement, and experiences no trouble from his injury. The skiagraph shows anchylosis and deformity of the axis.

* *Transactions*, 1904, p. 234.
† *Transactions*, 1905, p. 228.

IV.—*Stokes-Adams Disease.* By R. O. Moon, M.D. *Exhibited October* 27, 1905.

A CARPENTER, æt. 60.

Five years ago, while on some scaffolding, he fell backwards in a faint. A week later he had another similar attack. After that the attacks recurred at intervals of six months until June, 1903, when they came on with great frequency. In the attack he would fall to the ground with the suddenness of an epileptic seizure, remain unconscious for half a minute, and on regaining his senses feel perfectly well. There have been twitching movements on several occasions, but he has never bitten his tongue or passed his water.

During the last year the attacks have been decidedly less frequent, but he suffers a good deal from vertigo.

The pulse is regular and very slow; the rate is usually 28, but it has been as low as 24 and as high as 36. It is apparently unaffected by posture or exercise.

The cardiac impulse is very feeble, and there is a soft mitral systolic murmur at the apex, which, however, was not present when he first came under observation, June, 1904.

There is no albuminuria, and the optic discs are healthy.

There is no history of lues. He has been a man of regular habits, excepts as regards smoking; after the age of forty he became a very heavy smoker till two years ago.

V.—*A Japanese Infant, showing the Congenital Pigmentation of Mongolians.* By G. A. Sutherland, M.D. *Exhibited October* 27, 1905.

THE patient is a female infant, æt. 10 months, of pure Japanese descent. Over the scalp the hair is long, straight, and black, and it extends as a soft, downy growth over the forehead and in front of the ears. The skin over the lower part of the sacrum is of a dark blue colour, and a similar pigmentation, but of a lighter colour, extends over the buttocks. Smaller areas of blue pigmentation are present along the spine and behind the left shoulder, and there is one patch on the dorsal surface of the left hand.

VI.—*Cases of Lupus becoming Epithelioma after repeated Surgical and prolonged X-ray Treatment.* By W. G. Spencer, M.S. *Exhibited October* 27, 1905.

Case 1. *Lupus becoming epithelioma in a girl æt.* 15 *years after repeated surgical and prolonged X-ray treatment.*—At the age of six a bluish swelling formed on the gum of the upper jaw, which looked like a myeloid sarcoma, and histologically appeared to be a sarcoma without giant-cells. The disease having recurred several times it was recognised as lupus. It spread to the interior of the nose, then to the outer surface, the eyelid, and forehead.

The X-ray treatment, by Dr. Sale-Barker, was commenced about three years ago, and was immediately followed by healing except for some persisting islands. Lately the ulceration has recurred, the X rays now excite ulceration and sloughing, the edges of the ulcers are becoming indurated and everted, and the epithelium seems to be growing downwards.

Addendum (February, 1906).—Dr. Sale-Barker has been applying the anode of an electrolysis battery soaked in chloride of zinc, under which much, but not all, of the ulceration has healed, whilst the doubtful epitheliomatous areas have not extended.

Case 2. *Lupus becoming epitheliomatous after surgical and X-ray treatment.*—A woman, æt. 35. Lupus commenced in the right parotid region twenty-two years ago, and was treated by scraping under anæsthesia. Nineteen months ago the X rays were applied, on one occasion for ten minutes. A burn resulted, and then a swelling, which later spread downwards below the angle of the jaw, forming an abscess, which was incised. The ulceration began to fungate about ten weeks ago, and on October 17 a piece removed was found to be epitheliomatous.

Addendum.—The epithelioma rapidly extended.

VII.—*Peculiar Pigmentation of the Skin in an Infant.* By A. E. Garrod, M.D. *Exhibited October* 27, 1905.

THE patient is a female child, æt. 2½ years. She has always been very backward, and has never sat up nor talked. She is conspicuously brachicephalic, and shows some of the characteristics of the "Mongolian" variety of idiocy, but the facies is not typical. There is some spasticity of the limbs, and when the child is placed upon its feet the legs are crossed, as in cases of congenital spastic diplegia. The remarkable feature of the case is a peculiar pigmentation of the skin, which has a linear distribution, is of a grey-brown tint, and in places is arranged in whorls (Pl. VIII). The pigmented areas are not raised above the surrounding skin. The arrangement of the pigmented lines and whorls is remarkably symmetrical on the two sides of the body, but does not follow the course of nerves. Dr. J. Colcott Fox expressed the opinion that the case was one of linear papillomatous nævus, in a very early stage, preceding the development of actual papillomatous thickening in the seats of pigmentation.

VIII.—*Epithelioma of the Lip in a Man of Forty-four Years of Age.* By Lawrie McGavin. *Exhibited October* 27, 1905.

THIS patient was admitted to the Seamen's Hospital suffering from a large mushroom-shaped growth of the lower lip. Four months previously he had smoked the pipe of a friend, and a few days later noticed a small blister on the lip. This gradually increased in size to its present dimensions. Owing chiefly to its great rapidity in growth it was at first regarded as a primary chancre; as, however, it steadily progressed in spite of mercurial treatment, and as the glands present were not of the size or consistency usual in such cases, and in the absence of secondary symptoms, this diagnosis was abandoned. The tumour, which had recently become harder and more everted at the edges, and more concave in the

PLATE VIII.

Illustrating Dr. Garrod's Case of Peculiar Pigmentation of the Skin in an Infant.

Bale and Danielsson, Ltd.

Mau

centre, occupied four fifths of the margin of the lower lip; it had not encroached upon the skin, but showed signs of invading the mucous membrane. The submental glands were slightly enlarged, and one of the left cervical chain could also be felt. It was proposed to remove the whole of the lower lip by an extensive V-shaped incision, and then to attempt the re-construction of the part by the use of some such plastic method as that of Langenbeck or of Syme and Buchanan.

IX.—*Rodent Ulcer of the Scalp, Face, and Inner Canthus of the Eyelid; treated by the application of X-rays.* By Lawrie McGavin. *Exhibited October 27, 1905.*

THE ulcer began nine years previously as a small pimple on the right eyebrow; from this point it had spread gradually inwards to the inner canthus, and upwards to the scalp an inch higher than the frontal eminence; below it extended to the bridge of the nose and along the upper and lower eyelids. Three years previously the ulcer had been scraped without in any way affecting its progress.

When first admitted to the Seamen's Hospital the patient presented a very hopeless condition. The invasion of the lids rendered the performance of any operation out of the question, and the ulceration was producing marked conjunctivitis, and showed a tendency to invade the orbit from the inner canthus. The upper and inner edges of the ulcer were markedly rolled and indurated, the most actively growing part being that over the bridge of the nose and the inner canthus.

The ulcer was submitted to X-ray treatment on September 1st, 1905. By the time he had undergone five exposures, each being of five minutes' duration, the patient exhibited a condition of intense dermatitis, and at the end of the ninth it was not considered wise to push the treatment further; it was accordingly stopped, and fomentations were substituted. From this time the ulcer underwent resolution at a very rapid rate. The rolled edge became perfectly flat, smooth, clean scar tissue taking its place, the eyelids healed with loss of the

lashes and slight tendency to ectropion, and, at the time of exhibition of the case there remained a healthy area of granulation tissue about an inch and a half in diameter over the eyebrow, which was rapidly becoming covered.

X.—*Multiple Lipomas.* By H. D. Rolleston, M.D. *Exhibited January* 26, 1906.

MAN, æt. 43, has noticed fatty tumours in the neck for about four years, but until his attention was drawn to them was not aware of the others. The multiple lipomas are almost everywhere symmetrical.

There are lipomas on both submaxillary and parotid regions, in front of the temporo-maxillary articulations, in both supra-clavicular fossæ, in the axillæ, on the posterior aspects of the arms over the triceps muscle, in the pectoral regions, over the recti abdominis muscles where they are not symmetrical, in the right groin, and outer side of right thigh. There are none on the legs or forearms.

The lipomas in the neck will, by fusion, probably lead to a diffuse lipoma before long. There has recently been some pain in the lipomas on the right side of the abdomen and in the right groin, but the other lipomas are neither painful nor tender, and pain has not preceded the appearance of the lipomas, as is the case in adiposis dolorosa.

No enlarged glands can be felt in connection with these lipomas, which, in their distribution, resemble that in so-called "adeno-lipomatosis," and there are no scars from tuberculous glands.

The knee-jerks are present; there is no loss of muscular power. The thyroid cannot be felt. No epistaxis.

In September, 1904, the patient was in St. George's Hospital with painful swellings of the wrists, ankles, and right big toe, which did not yield to salicylates or to colchicum. On getting up he had several attacks of peliosis rheumatica on the legs, and some œdema of the feet. He has occasionally had slight similar attacks, but never definite gout. The deformities of the fingers are explained by traumatism. He has recently put on weight (usual weight 9 st. 6 lbs., now 11 st.). Urine normal.

Up till September, 1905, took three or four pints of beer daily, but no spirits; none since.

Put on thyroid extract January 12, 1906; this made him irritable.

XI.—*A case of General Paralysis of the Insane in a boy æt.* 16 (?). By JOHN R. LUNN. *Exhibited January* 26, 1906.

T. J., single, a newspaper boy. The patient is one of eight children.

The mother states he has always been untrustworthy with money, and she thought he was a kleptomaniac. He has had three fits with unconsciousnes, April 15, September 9, and September 15, 1905. Since having the fits he has become duller, and has had occasional twitchings of the left arm and leg. He walks with his left arm flexed, abducted, and hand flexed on the forearm, and drags his left leg. There are no tremors, but there appears to be some weakness of the elevating muscles of his mouth, but neither facial muscles are affected. Some weakness of the left arm and hand. Sensation over the body normal. Speech not affected. Sphincters normal. Reflexes: left elbow and wrist present, but not present on the right side; patella reflex brisk on both sides; no clonus. Left pupil larger than right (contracts under *guttæ eserinæ*). No ocular paralysis. No changes in the fundus.

XII.—*A case of Myasthenia Gravis (?).* By JOHN R. LUNN. *Exhibited January* 26, 1906.

W. B., æt. 39. The last seven years he has noticed weakness of his hand and neck muscles. He stumbles when he walks.

Nervous system.—Motor weakness of arms, forearms,

hands, and legs; the fine movements of the fingers are lost. Flexion and extension at the elbows are weak. The anterior tibial muscles of both legs are weak, and there is foot-drop. Some loss of power in the face muscles, and ptosis. His eyes cannot be raised above the horizontal; paresis of both orbiculares oris and palpebrarum and some weakness of both occipito-frontales muscles. Right supinator longus muscle and right interossei are wasted. Some contraction of the sterno-mastoid muscles, but not sufficient to raise his head from the pillow when in bed.

Sensory.—Tactile sensation to heat and cold normal. Both knee-jerks and plantar reflexes absent; hypogastric and epigastric reflexes present. The tongue does not appear wasted; taste normal. The pupils react to light and accommodation; no changes in the fundus. Speech blurred, the blurring increased by talking; some slight difficulty in swallowing. All the wasted muscles react to faradism, but not well, and a strong current is necessary; they do not react to galvanism.

XIII.—*A case of Molluscum Fibrosum.* By JOHN R. LUNN. *Exhibited January* 26, 1906.

J. K., æt. 22, a cook. First noticed his present condition eighteen months ago, and has gradually become worse. Six months ago he was obliged to give up his work as some lumps appeared on his face. Two lumps on his toes have disappeared, leaving only slight scars. He has experienced no pain in the swellings, only slight itching at night-time when he gets warm in bed.

Present condition.—Healthy-looking man. The patient's trunk is covered all over with tumours, varying from the size of a millet seed to that of a cherry; most of them are sessile, but a few are becoming pedunculated; they are movable on the deeper structures, and adherent to the skin, which is rather thinned over their centres. The distribution does not appear to correspond to any nerves. He has had arsenic and thyroid tablets by the mouth, but no changes in the tumours have taken place. Two of the tumours were

excised for examination and sent to the Clinical Research Association.

"The larger of these two tumours is a localised, but not encapsuled growth of fibrous tissue, plentifully nucleated and containing blood-vessels and nerves. The presence of the latter, with their concentrically arranged sheaths, is of some importance, pointing to the probability that this fibroma has arisen from the nerve sheath, and is therefore a neuro-fibroma. The fact that the growths are multiple is also in favour of this, but it does not necessarily follow. The smaller tumour is more diffuse in appearance, and there are no nerve-fibres to be recognised in it. Neither of these tumours show any sign of malignancy."

XIV.—*A case of Laminectomy for Traumatic Paraplegia.* By Lawrie McGavin. *Exhibited January 26, 1906.*

THE patient, a labourer, æt. 36, was admitted to the Seamen's Hospital, October 10, 1905. A steel plate twenty feet long and four feet wide had fallen across his back. On admission there was complete loss of sensation and motion in both lower extremities; the scrotum and penis were partially anæsthetic; there was complete absence of knee-jerks and of plantar reflexes, and the bladder and rectum were paralysed, as was also the sphincter ani. A depression was found over the spine of the first lumbar vertebra deep enough to admit the tip of the finger.

The patient was submitted to operation three hours after the injury. The spinous processes and posterior halves of the first and second lumbar vertebræ were found to be completely detached, and forced down upon the cord; the left lamina of the second lumbar vertebra was comminuted, and a portion of this bone was found to have been pushed forwards between the cord and the transverse process. The whole of the detached bone was removed, and the wound was closed except for the presence of a horse-hair drain at the lower angle. Twenty-four hours later sensation had returned in the right leg and thigh, and the foot and ankle could be moved. On the following day sensation returned in left leg

and thigh, with the exception of the area supplied by the genito-crural nerve and the lesser sciatic. In three weeks the paralysis of the rectum and bladder improved; and under massage and faradisation the motor and sensory functions have gradually returned, although the left leg and thigh still remain feeble. The patient is now able to walk without the help of either crutches or sticks; the right knee-jerk is still delayed and feeble, and the plantar reflexes are absent.

XV.—*Congenital Aperture in the Centre of the Palate.* By James Berry, B.S. *Exhibited January* 26, 1906.

H. W., æt. 16. Admitted to the Royal Free Hospital on account of a congenital aperture in the middle line at the junction of the hard and soft palates. It is symmetrical

Fig. 23.—Congenital aperture in the centre of the palate.

and oval, being 7 mm. long and 5 mm. wide. Two thirds of the opening are in the hard palate, one third is in the soft.

The edges are thin. On either side of and behind the opening the tissues are thinner than is natural. The uvula and posterior edge of the soft palate are congenitally cleft.

There is no harelip nor any other defect of development except those mentioned.

The mother states that the opening in the palate was noticed soon after birth, and that it was then "nearly covered with a thin membrane." For the first two years of life the child was "delicate," but she has never had any serious illness. There has been no injury to the palate at any time, and no operation of any kind has yet been attempted.

XVI.—*Case of Shaking Head or Spasmus Nutans.* By C. H. Thompson, M.D. *Exhibited January* 26, 1906.

L. C., æt. 8 months. Attended St. George's and St. James's Dispensary last November, when five and a half months old, with an attack of bronchitis, from which she recovered in two or three weeks.

In the first week in December, when the child was six months old, her mother noticed movements of her head and eyes, which have continued up to the present time. The child has always been suckled, but was also fed on nursery biscuits during the first few months of life. She lives with her parents and two elder children in a dark back room in a basement in Soho.

There is no history of injury or fits, and there are no signs of rickets, although sweating about the head at night and throwing off the bedclothes have been noticed.

Present condition.—There are almost continuous movements of the head, both lateral and to and fro, while the child is awake. The movements cease during sleep and when the eyes are bandaged. They also cease if the child grasps any article and becomes intent on obtaining it.

There is marked nystagmus, lateral, rotatory, and up and down. These movements of the eyes become more marked when the head is grasped and steadied.

In its mode of onset, and the symptoms observed, the

case closely resembles thirty-five cases of this condition observed by Dr. John Thomson, of Edinburgh, and tabulated in his interesting paper on "Spasmus Nutans" in Jacobi's *Festschrift.* Almost all of Dr. Thomson's cases, however, showed signs of rickets. Thirty-one of them had nystagmus.

XVII.—*A Case of Amyotrophic Lateral Sclerosis.* By J. Walter Carr, M.D. *Exhibited January* 26, 1906.

PATIENT, æt. 33, is a labourer. His present illness began about four years ago with weakness and wasting of the right hand; two and half years ago the right leg began to get weak and stiff, with increasing difficulty in walking. A year ago weakness was first noticed in the left arm, and during the last few months in the left leg.

At the present time the legs present well-marked spastic paraplegia, with extensor plantar reflex, exaggerated knee-jerks, and, on the right side, ankle clonus. There is some pes cavus on both sides. The arms show distinct flaccid paralysis, affecting mainly the small muscles of the hands, and, to a much less degree, some of the shoulder muscles. Fibrillary twitchings are very marked in nearly all the affected muscles. The intrinsic muscles of the hands show a partial R.D., nowhere complete, except that the right first dorsal interosseous gives no reaction to either current.

There is no affection of sensation, of co-ordination, nor of the sphincters, and no indication of any bulbar paralysis, except very slight weakness of the right facial muscles.

There is well-marked nystagmus of the right eye, but this is perhaps connected with the blindness of the left eye due to ophthalmia neonatorum.

XVIII.—*A Case of Transverse Myelitis, with loss of Knee-jerks; Recovery.* By W. P. Herringham, M.D. *Exhibited January* 26, 1906.

A. S., æt. 29, a labourer, was admitted April 21, 1905, with the following history:—Nine days ago had pains in legs and back, which got worse. His arms became weak, and he lost control of his sphincters. Loss of power and anæsthesia rapidly developed in his legs. He has never been a drinker, and has not had syphilis.

On admission there was paralysis of intercostals, diaphragm, and legs. The arms were weak. There was anæsthesia of the legs, which soon spread upwards as far as the level of the nipples, with complete paralysis of his chest muscles, and loss of knee-jerks. Large bedsore developed; there was severe cystitis, and the urine became very ammoniacal and purulent. For a fortnight in May there was marked hectic fever. His condition gradually improved until now, nine months later, he is able to walk about unaided. He still has some weakness of the sphincters, but this is improving. His knee-jerks, which were not obtained during the early part of his illness, are now present.

XIX.—*Charcot's Disease of the Thumb.* By P. Maynard Heath, B.S. *Exhibited January* 26, 1906.

J. C., a man æt. 45, cut his left thumb with a saw three months ago. There was some inflammation about the part, but the wound healed. Soon after the thumb began to swell. A month later the skin became red, and lately the swelling has become much greater. There has been very little pain.

At the present time the thumb is very much swollen, and the skin is red and in parts scaly. The swelling is most

marked over the interphalangeal articulation, and this joint is disorganised. The metacarpo-phalangeal articulation is normal.

FIG. 24.—Charcot's disease of the thumb.

There are well-marked signs of Tabes. The knee-jerks are unobtainable. The pupils show the Argyll Robertson phenomenon, and Romberg's symptom is present.

XX.—*Case of Sudden Paralysis of the Third Cranial Nerve.* By BERTRAM ABRAHAMS, M.B. *Exhibited January* 26, 1906.

MARRIED woman, æt. 47. Has had eleven children, one premature confinement. Seven are living; one died, aged ten, of "ulcers of bowel," none of infantile ailments.

Husband has had a skin disease, with a rash on the body and loss of hair in patches, several years ago. This recurred two years back.

Patient had been subject to quinsies for many years till her tonsils were removed twelve years ago. Has been an out-patient at Westminster Hospital on and off for four years with shooting pains in legs and feet; these were relieved by tonics. For the last month there has been twitching of the left eyelid. On January 18 and 19 she was drowsy and sleepy, and had frontal headache. On the morning of January 20 she found that she saw objects double; the left eye was partially closed, and during the morning the closure became complete.

Present condition of eyes.—Left: slight elevation of eyebrow; complete ptosis; slight proptosis. Pupil three-quarters dilated; not quite circular; does not react to light or accommodation. Eye deviated outwards at an angle of about 25°. Movement *outwards* unimpaired, *inwards* not beyond centre of orbit, *upwards* lost, *downwards* lost except a slight downward movement with inward rotation (sup. oblique). *Right:* normal; transverse axis greater than vertical. No iritis; discs and fundi natural. There is crossed diplopia, both horizontal and vertical. In horizontal meridian the false image is below and to right of line. In vertical false image is below line with downward movement, and above it with upward. When the image is on the level of the centre of the eye it is single.

The other cranial nerves and the rest of the nervous system are natural. There is a systolic bruit at the cardiac apex, and a to-and-fro murmur at the aortic base. The liver is enlarged, the dulness extending to two fingers-breadth below the costal margin in the left mammary line. There is no other abnormal physical sign.

It will be noted that the palsy is in an early stage, over-action of the external rectus and radial dilator of the iris not having developed.

XXI.—*A Case of Bilateral Deformity of the Neck of the Femur.* By RUPERT BUCKNALL, M.S. *Exhibited January* 26, 1906.

A BOY, æt. 9, who always had difficulty in walking, which has increased as he has grown older. No history of injury; not thought to have had rickets; has been kept in bed during the past twelve months. The lower limbs are of equal size and length. The trochanter on either side lies higher than normal, its tip being three quarters of an inch above Nelaton's line. Otherwise, when lying at rest the limbs do not appear abnormal. The head of the femur can easily be felt in Scarpa's triangle, much below the level of the great trochanter. Extension is perfect; flexion is good; adduction is slightly increased in range; abduction is remarkably diminished, both in the extended and flexed positions of the limb. When extended the angle of abduction between the two thighs does not exceed twenty degrees. Internal rotation is slightly diminished. External rotation can only be carried out through half the normal range. The marked adduction of the thighs interferes with walking, and almost leads to a cross-legged gait, and running is impossible.

Skiagrams show marked bending of the neck of the femur downwards.

XXII.—*Case of Osteo-sarcoma of Frontal Bone.* By THOMAS H. KELLOCK, B.C. *Exhibited January* 26, 1906.

F. P., æt. 23. Family history quite good. Between six and seven years ago first noticed a small hard swelling on the left side of the forehead just above the eyebrow; this has gradually increased in size; it has never been tender nor given rise to any pain or symptoms. A large tumour now involves the left half of the frontal bone, and extends a little beyond the mid-line above the nose; it is 18½ inches in circumference, and rises about 4 inches above the level of the rest of the skull; it is densely hard, except in a few spots,

which feel soft and elastic; the veins in the scalp over it are somewhat distended. The left eyeball is displaced downwards and forwards, but there is no diplopia.

There are signs of optic neuritis in both eyes. A skiagram shows the tumour to be chiefly composed of bone, but the periphery is irregular. The patient's general health is, and has been, excellent, and he has followed his occupation—that of a tailor—up to the present time.

On January 2 an exploratory incision was made into the tumour by turning backwards a flap of the scalp, and the periosteum which overlay the growth was separated. The surface of the growth was found to be soft, and the microscopic examination of a piece that was removed showed it to be sarcomatous; the central portion of the tumour was very hard, and was with difficulty cut with a gouge. There was rather free hæmorrhage, which was arrested by the application of adrenalin solution. The wound was closed, and healed by first intention.

XXIII.—*Tetany of seven months' duration associated with Gastro-intestinal Disorder in a girl æt. 9 years, apparently cured by the use of Thyroid Substance.*

By H. T. Mant, M.B., and H. Batty Shaw, M.D.

Exhibited January 26, 1906.

E. A., an ill-nourished child of nine years, has suffered from gastro-intestinal disorder for the last four years. For the last eighteen months she has been unable to walk because of weakness of the lower extremities, and during this period the abdomen has become much distended. She has suffered from repeated attacks of tetany during the last seven months, and has become very pale, the blood examination showing secondary anæmia. She is somewhat puffy in the face, and a firm œdema has been present in the feet and hands. The knee-jerks have been lost on a previous occasion, but returned, and the tetany disappeared under treatment in hospital with salol, etc. The same treatment has now failed, and the knee-jerks are again absent. The recent attacks of tetany disappeared immediately after the

use of thyroid substance, and though this remedy was given for a week only, attacks have not recurred. The treatment has been lately resumed in order to get rid of pains in the feet, which occur in walking or standing. The points of interest in the case are—

(1) The long period (seven months) during which the attacks of tetany have been frequently reported.

(2) The association with marked gastro-intestinal disorder and distension of the alimentary tract.

(3) The failure of the antiseptic treatment of the bowel, though on a former occasion it appeared to be successful.

(4) The apparent prompt response to thyroid treatment.

XXIV.—*Plexiform Angioma of the Hand and Arm.* By HUGH M. RIGBY, M.S. *Exhibited January* 26, 1906.

THE patient, when three months old, was admitted into the London Hospital in January, 1905. The left brachial and radial arteries were dilated and tortuous, and communicated a well-marked thrill. The palm of the hand was occupied by a pulsating vascular tumour. The third part of the left subclavian artery was ligatured in February, 1905. Not improved.

XXV.—*Cavernous Nævus of the Tongue.* By HUGH M. RIGBY, M.S. *Exhibited January* 26, 1906.

THE patient was in the London Hospital eighteen months ago for cavernous nævus of the right border and dorsum of the tongue. In July, 1904, the right lingual artery and veins were ligatured, and the tumour apparently completely dissected out. The present condition shows a gradually increasing recurrence.

XXVI.—*Perforating Ulcers and Joint Changes with only slight Sensory Changes.* By C. E. BEEVOR, M.D. *Exhibited January* 26, 1906.

WILLIAM D., æt. 38, married, formerly catsmeat man (standing many hours).

Health generally good. Temperate. Bright's disease at twenty-seven for two years. Venereal disease and risk denied.

Five years ago had two fits, with parasthesia all over right side, and loss of speech. In bed six months. Unable to move legs, which were stiff, for six weeks; power returned gradually and steadily. Resumed business in nine months. Sphincters and sensation unaffected.

Three years ago toes became stiff; blisters appeared on dorsal and plantar surfaces, which ulcerated. Three pieces of dead bone separated on various occasions; one piece evidently distal end of terminal phalanx of great toe.

Had pains in right ankle, but could walk with a stick until nine months ago, when pain in ankles worse; feet tender, painful if he trod on a stone. Gave up walking ten weeks ago.

Present condition.—Some ptosis; slight overaction of frontalis. Pupils equal; react to light, and convergence. Talkative, and apt to get confused; lisps.

Sensation.—Slight difficulty in distinguishing between touch and prick, and also heat and cold on soles of feet and dorsal aspect of toes. Otherwise sensation is normal throughout. No lightning pains.

Ankle-joints were stiff on admission, but now appear normal.

Muscular system normal, except some difficulty in moving the toes; knee-jerks increased; plantar reflex gives flexion of toes.

Feet are very misshapen; sweat freely and smell foul.

Right foot flat; bones of tarsus and proximal ends of metatarsal bones are large, but joints are movable actively and passively without grating.

On admission to hospital there was much swelling of ankle, tarsus, and metatarsus and toes in both feet. This has diminished with rest in bed.

Right toes: four external toes are now about normal size; formerly enlarged and stiff. Great toe much enlarged in the soft tissues, which were still larger on admission. Bones of metatarso-phalangeal joint are large, but joint moves well actively and passively without grating. Phalangeal joint quite disintegrated; formerly large perforating ulcer on under aspect, through which three pieces of bone have sloughed, one of which is distal extremity of terminal phalanx, which is absent in skiagram. Toe-nail has been lost many times.

Left foot: arch is not flattened as in right. Outer three toes normal. Great toe misshapen. Great enlargement of metatarso-phalangeal joint, especially in dorso-plantar diameter; considerable bony deformity all round joint; passive movement only possible, and grating is obtained. Fair movement, active and passive, in phalangeal joint; no grating, but joint is abnormally loose. Perforating ulcer less severe under this joint. Second toe abnormally thick and straight, seen from above, but has a large bulbous soft swelling under the distal phalanx. Metatarsal joint much increased in dorso-plantar diameter; abnormal exostosis at the end of the metatarsal bone; movement of joint very limited; dorsi-flexion impossible; no actual grating; movements of phalangeal joints almost absent. Nail is at the extreme end of the toe.

The case is probably one of syringo-myelia with slight sensory changes or of early tabes dorsalis.

XXVII.—*Mediastinal Sarcoma which disappeared after treatment by the Röntgen Rays.* By J. P. ZUM BUSCH, M.D. *Exhibited March* 23, 1906.

E. K., æt. 37, suffered from a chancre in 1896. Syphilis was diagnosed only in the following year, when specific tonsillitis and an eruption on the palms and soles appeared. This psoriasis palmaris broke out frequently during the next years, so that the patient was almost continually under mercurial treatment. Altogether he used 480·0 grms. of grey ointment for inunction, and took a large number of mercurial pills; he also had thirty-five intra-muscular injections of

mercuric salicylate. In spite of this vigorous treatment the psoriasis palmaris recurred in September, 1904, when he came under my treatment.

The patient at that time was very anæmic and looked ill; his breath was very short. The face and neck were swollen and cyanosed; the superficial veins of the whole body, and especially the right epigastric veins, were enormously enlarged. He complained of pains in the right half of the thorax, which had for the first time occurred about four years ago. The pains came in attacks, always at night-time, and lasted for two or three hours. At first the intervals between the attacks had been very long; gradually, however, they had become shorter and shorter. Two years ago he began to complain of giddiness and pain in the left half of the head and pressure in the left eye. About this time the veins commenced to swell; the swallowing became difficult; large pieces of meat or bread could not be swallowed at all.

During the winter 1903—1904 the condition became worse; the attacks occurred almost every night. The spring and early summer brought a slight improvement. In August, 1905, he had a very severe attack of pain, which lasted five hours and left a swelling in the region of the second and third sternocostal joints. The swelling increased in size and became painful. About four weeks later a large lump was noticed in the right supra-clavicular space. There were frequent rises of temperature and patient lost weight rapidly.

When first seen by me (September, 1904) his condition was as above described; there was a large mediastinal tumour, which pushed the second and third rib on the right side of the sternum forward; this tumour could be easily made out by percussion, and was seen by examination with the Röntgen rays. The breathing was very short and the swallowing difficult; a distinct sound could be heard when the patient tried to force some food down. There were some hard, irregular glands to be felt above the clavicle, and a deep resistance on pressure over the jugulum. An examination of the blood gave a normal count. The present state seemed to warrant the diagnosis of a malignant tumour of the mediastinum. In view, however, of the co-existence of a typical syphilitic eruption, and of the nocturnal attacks of pain, the possibility of a large gumma was thought of and the patient treated accordingly by intra-muscular injections of mercuric salicylate and by the internal administration of 1·0 grm. potassium iodide three times daily. The skin erup-

tion disappeared rapidly; the tumour, however, remained quite stationary. In January, 1905, the patient caught a slight cold, which was followed by an unusually severe attack of pain, by coughing, hoarseness, still greater difficulty in swallowing, and paræsthesia over the left half of the body. The pulse rose to 120 and has remained more frequent since that time.

The patient seemed in a hopless state, and following the wish of his friends, he left for Vienna as soon as he was able to make the journey. Professor Mannaberg and others who saw the patient concurred in the diagnosis of malignant tumour; Dr. Porges, who also saw him, sent him to Dr. Kienböck for treatment with the Röntgen rays.

At the beginning of the treatment (February 10th) the condition was as follows: Area of dulness extending to both sides of manubrium sterni (more to the right) 14·5 cm. broad; at the level of the third rib it is only 11 cm. broad. Second and third costal cartilages on right side very prominent. Hard, irregular glands in supra-clavicular space on right side. Veins greatly dilated. Pupils of equal widths and normal reaction. Heart-sounds normal, pulse frequent. Examination of blood gave 5,100,000 red and 5700 white corpuscles; 68·8 per cent. polynuclear, 24·6 per cent. lymphocytes, 4·6 per cent. eosinophile, 2 per cent. plasma cells, hæmoglobin (Fleischl) 80 per cent., colour index 0·8. The blood count was normal, with the exception of an increase in the plasma cells.

The skiagraphic examination confirmed the diagnosis of a large mediastinal tumour. A gelatine capsule filled with bismuth, which the patient tried to swallow during the examination, did not pass further than to the level of the jugulum, where it stuck.

In view of the syphilitic history mercury inunctions (2·0 grms. *per diem*) were begun, and the tumour was exposed to the Röntgen rays in the following way:

From February 11 to 18 the prominent part of the tumour was treated daily for five to six minutes. After the first two sittings the patient felt greatly improved; the pain had disappeared and the difficulties in breathing and swallowing were much less. After the sixth sitting the prominence had disappeared. From February 20 to 25 the intra-scapular space was treated in the same way. From February 27 to March 2 the lateral parts of the thorax were treated.

From March 18 to 28 and again from April 2 to 14 the anterior wall of the thorax was exposed.

The patient came back to London and was seen by me on April 29. His condition was greatly improved; the dulness over the sternum was only 8·5 cm. broad, the prominence of the ribs and the enlarged glands had entirely disappeared, the veins were normal in size. The patient had gained 3 kgm. in weight, slept well, was entirely free from pain, and had no difficulty in breathing or swallowing.

On May 10 he came again to see me, and complained of some giddiness. It was found that the glands in the supra-clavicular space had become again enlarged and hard. As one of the glands felt fairly movable, I removed it under cocaine for diagnostic purposes. The gland was slightly adherent to its surroundings, looked homogeneous and glassy on section, and showed no trace of caseation.

Microscopically it proved to be a sarcoma, which showed in some parts an alveolar structure.

The patient was advised to return to Vienna for further treatment. He had five further exposures between May 22 and 26, after which the glands had almost disappeared.

Since that time the patient has remained in very good health; he is quite able to do all his work as an electrical engineer, he has gained in weight, and is quite free from pain.

In January, 1906, he had a further course of Röntgen treatment as a prophylactic measure.

A very similar case has been published by A. Clopatt in the *Deutsche medizin. Wochenschrift*, No. 29, 1905.

XXVIII.—*Bony Tumour of Skull.* By H. G. Turney, M.D. *Exhibited March* 23, 1906.

THE patient is a man æt. 42. He has noticed the swelling on the top of his head for seven or eight years. For the last eighteen months he has had headache, which is getting more severe. The headache is worse during the day; in fact, he sleeps well at night. He has had three "fits," at intervals of about two years, during the last six years, and four or five

years ago he had right-sided facial paralysis of infra-nuclear type (? if Bell's palsy).

On examination.—A large smooth bony growth occupying the right and anterior portion of the calvarium and extending across the mid-line for some distance. No optic neuritis; no signs of nerve involvement. No vomiting nor slowness of pulse.

XXIX.—*Case of Sudden Paralysis of the Third Cranial Nerve.* By BERTRAM ABRAHAMS, M.B. *Exhibited March* 23, 1906.

MARRIED woman, æt. 47. Exhibited at the last clinical evening of the Society, January 26. Paralysis of the left third nerve was then total. It was suspected that the lesion was of specific origin, as the patient was the subject of aortic valvular disease consequent upon a descending aortitis, and her husband was known to have suffered from a general cutaneous eruption a few years back. She was accordingly treated with potassium iodide for between two and three weeks without the slightest obvious effect. She was then put, instead, upon mercurial inunctions, and soon began to show improvement, which is now steadily progressing.

The original attack occurred suddenly on January 20. Visible improvement had begun by the middle of February, and by the middle of March the ptosis had virtually disappeared.

Present condition of left eye.—Ptosis very slight. Pupil moderately dilated, inactive to light and accommodation; backward deviation has decreased. There is some recovery of action of internal and inferior recti, less of superior rectus.

The diplopia is now as follows: Crossed diplopia to right of mid-line, with increasing separation of images with movement to right. Diplopia above level of centre of eyeball, with false image below line, and distance between images increasing with movement upward. No diplopia below level of centre of eyeball.

XXX.—*Case of Adiposis Dolorosa.* By BERTRAM ABRAHAMS, M.B. *Exhibited March* 23, 1906.

MARRIED woman, æt. 40. Rheumatic fever at 20; in hospital three months. Winter cough for years. No menstrual disturbance.

Two sisters and one daughter stout; remainder of family slight. No history of syphilis ascertainable. Patient was slight till her last child was born, three years ago. Since then has become steadily stouter and has had constant aching pain in lower part of back on left side. As the stoutness progressed tender places have gradually developed about the body.

She is clothed universally with a thick adipose layer over certain areas—(1) back of right arm, (2) outer aspect of right arm just below shoulder, (3) outer aspect of left forearm, (4) right hypochondriac region, (5) inner aspect of left thigh just above knee. The patient complains of tenderness, and some additional thickening of the subcutaneous tissues can be felt. On the outer side of the left leg there is tenderness, but no such thickening can be felt: here there are varicose veins. There is no other disturbance of sensation. Heart-sounds distant and feeble.

Thyroid natural; mental activity good; skin healthy.

The patient's daughter is also shown. She is eleven years of age, and weighs 8 st. 11½ lb. stripped. She complains of pains which are not definitely localised. There are no persistently tender spots, and no subcutaneous thickenings.

XXXI.—*Dislocation of Metatarsus.* By CYRIL A. R. NITCH, M.S. *Exhibited March* 23, 1906.

A. V., male, æt. 22, marine engineer, was in the engine-room of a ship at sea, when a sudden roll caused some heavy iron plates to fall on, and imprison, his foot, while, at the same time, he was thrown violently to the deck. After the accident the foot was much swollen, and he was unable to walk. One week later, when the ship reached Venice, a

plaster-of-Paris splint was applied, but apparently the dislocation was not recognised. After an interval of three weeks the splint was removed at another hospital, and he was then told to use the foot. This he has since been able to do, and, in addition, has climbed up and down an engine-room staircase. Ten weeks after the accident he was admitted to St. Thomas's Hospital under the care of Mr. H. H. Clutton. The most noticeable features then were—flattening of the plantar arch, slight abduction of the metatarsus, marked prominence of the internal cuneiform, and an apparently normal outer border to the foot. The skiagram (Pl. IX) revealed an outward dislocation of the metatarsus, the first metatarsal being in contact with the middle cuneiform, and the fifth completely separated from the cuboid. Reduction under an anæsthetic was attempted, but failed. Operative interference was not indicated, as the man was perfectly satisfied with his condition, and fully able to pursue his vocation.

XXXII.—*Dislocation of the Metatarsus.* By JOHN J. DOUGLAS, M.D. *Exhibited March* 23, 1906.

P. T., æt. 24, was thrown from a cart on January 19, 1906, the wheel going over his right foot. When first seen the foot was much swollen, but there was no very striking deformity. As the swelling subsided the internal cuneiform bone was seen to be unduly prominent. On February 6, a skiagram showed the whole metatarsus dislocated outwards, the first metatarsal being in apposition to the middle cuneiform and the fifth almost off the cuboid. Reduction under an anæsthetic was attempted, but failed, on February 8. On February 12 an incision was made along the inner margin of the foot, and the joint between the first metatarsal and internal cuneiform exposed. It was then found that the portion of the tibialis anticus internal tendon inserted into the base of the first metatarsal had got between that bone and the internal cuneiform, and was seemingly the obstacle to reduction. This being pulled out and replaced, the metatarsus was pushed into position with comparative ease. On March 29 the patient was doing his work, delivering meat in a butcher's cart.

PLATE IX.

Illustrating Mr. Nitch's Case of Dislocation of the Metatarsus.

Bale and Danielsson, Ltd.

Mapou

XXXIII.—*Case four years after Fixation of Omentum for Ascites.* By W. G. SPENCER, M.S. *Exhibited March* 23, 1906.

F., æt. 54. In hospital four years ago, under Dr. Murrell, with alcoholic hypertrophic cirrhosis and ascites; pigmentation of legs; no other specific signs. Tapped, but refilled, peritoneum drained, but refilled, again drained and omentum fixed in epigastrium. Liver found enlarged, nodular. Has continued to take alcohol as before, but no fluid has collected since. No œdema. No albuminuria. Re-admitted for complete removal of fungating cancer of left breast, including pectoral and axillary glands. Liver felt as much below ribs as at first.

XXXIV.—*Sporadic Case of Friedreich's Disease.* By J. G. GIBB (introduced by BERTRAM ABRAHAMS, M.B.). *Exhibited March* 23, 1906.

WILLIAM D., æt. 13, school standard II. No history of any nervous or mental disorder in the family. Father and mother healthy; they are first cousins; one sister well and strong, æt. 14.

Nothing unusual noticed till he was five years old. Then, in walking up hill and after walking rather far, he complained of pain in the small of the back; in walking he rolled from one side of the path to the other. He began to have bad dreams, night terrors, pain in head and over the right eye. For the last year he has been free from night terrors. The onset of these symptoms is attributed by his parents to a fright.

He is bright and intelligent, although the expression is a little vacant. Muscular development is poor.

He stands with a forward inclination of the trunk, neck bent to the right, arms forward, hands supinated, and feet apart. There is some static ataxia.

His walk is swaying to staggering and irregular. There

is slight stamping, but rather of the ball of foot than the heel. He turns with difficulty.

Speech is slow, and sometimes slurred.

The spine shows slight curvature, with convexity to the right in the mid-dorsal and to the left in the lower cervical regions. There is pes cavus when the feet are off the ground.

Romberg's sign with tendon movement is marked. Knee, ankle, supinator, and biceps jerks are absent.

There is some inco-ordination of the upper extremities and slight lateral nystagmus, more to right than to the left. Sensory functions are not disturbed.

XXXV.—*Spleno-Medullary Leukæmia (Myelæmia) in a Boy, æt.* 10½. By Arthur Voelcker, M.D. *Exhibited March* 23, 1906.

W. C., a boy æt. 10½, was admitted to the Hospital for Sick Children, under the care of Dr. Voelcker.

Present illness.—Patient was quite well till four months ago, when he began to lose weight and became pale. The abdomen has been enlarging for two months. No abdominal pain. Several attacks of epistaxis lately.

Previous history.—Unimportant.

Present state.—Rather pale, but lips and beds of nails of very fair colour. Spleen very large, extends down to pelvis. Liver extends ¾ inch below costal margin. Glands in groins and axillæ slightly enlarged. No tenderness about the bones. Urine contains a trace of albumen. Soft hæmic murmur at pulmonary cartilage. No retinal hæmorrhages.

Blood (report by Dr. J. Graham Forbes).—Hæmoglobin, 70 per cent.; colour index, 1·06; erythrocytes, 3,302,000 per c.mm.; leucocytes, 400,000 per c.mm.

Differential count.—Polymorphonuclear, 36·8; large mononuclear, 3·6; small lymphocytes, 9·6; large lymphocytes, 8·4; eosinophiles, 7·6; basophiles,* 13·6; myelocytes: [(1) finely granular eosinophilic, 14; (2) coarsely granular eosinophilic, 6; (3) basophilic, 0·4 = 20·4].

* Under basophiles are included all cells showing only basophilic granules round an irregularly lobed nucleus. Many possibly represent transitional forms of the polymorphonuclear cell. In counting 500 leucocytes only one nucleated erythrocyte (a normoblast) was seen.

XXXVI.—*Functional Hemiplegia (? Disseminated Sclerosis) in a Boy æt.* $9\frac{8}{12}$. By ARTHUR VOELCKER, M.D. *Exhibited March* 23, 1906.

A. P., a boy æt. $9\frac{8}{12}$, was admitted to the Hospital for Sick Children, under the care of Dr. Voelcker.

Previous history.—Two and a half years ago suddenly lost power in his legs. He was admitted as an in-patient at Great Ormond Street, where it was noted that he could not sit up; he had very little power in the legs, less in the right than in the left. Slight tremor in the upper limbs. Some nystagmus on extreme outward movement of the eyes. Knee-joints exaggerated. A.C. present on both sides. Plantar reflex extensor on both sides. Occasional incontinence of urine. A provisional diagnosis of disseminated sclerosis was made. The boy contracted scarlet fever, was sent to the Fever Hospital, from which he returned quite well, and has continued so till March 9th, 1906.

Present illness began suddenly, with weakness of the left arm and leg. He could not sit up when brought up to the hospital; there was left hemiplegia. Face not affected. The forearm muscles were most affected. Grip very weak on left side. Knee-joints exaggerated. No A.C. Extensor reflex on both sides, but next day on left side only. Sensation natural. Lateral nystagmus on looking to the right. Speech natural. No optic neuritis or atrophy. No incontinence of urine.

XXXVII.—*A Case of Congenital Absence of the Fibula and Malformation of the Head of the Femur (Congenital Coxa Vara) simulating Congenital Dislocation of the Hip.* By T. H. OPENSHAW, C.M.G. *Exhibited March* 23, 1906.

G. L., female, æt. 6. Mother and father healthy; no deformity in the family; seven other children, all perfectly formed. Liquor amnii abundant; good time when carrying; no fright or injury; natural birth; normal labour; vertex presentation.

Child walked first when two years old. Now walks very well, but drops down on to the left foot. Right leg, 19⅝ in.; left leg, 13⅞ in.

The left foot is valgus at the ankle. The internal malleolus is prominent. The tibia presents at the middle of the shaft a slight linear dimpling, situated exactly over and parallel with the anterior border of the tibia. The fibula is absent, except for a small portion at the lower end an inch to an inch and a half in length.

The left knee-joint is normal, except that the internal condyle is a little prolonged. The patella is present and in normal position. The left femur is much shortened; it measures 6½ in. from the great trochanter to the external condyle, the right femur measuring 10⅞ in. There is marked thickening of the bone at the great trochanter.

The whole lower extremity is rotated out through an angle of 35°, but there is no flexion, adduction, or abduction contraction at the hip-joint. Of the movements, flexion is a little limited. Abduction is only possible through a range of 10°. Adduction is increased, the left knee crossing the upper third of the opposite femur in full adduction. Rotation out is increased 20°, and rotation in is normal as compared with the right leg.

When the leg is fully adducted the great trochanter, and also what appears like the head of the bone, are distinctly felt beneath the glutei muscles.

The X ray, however, shows the head of the femur situated in the acetabular cavity. The acetabulum appears to be well formed. The upper end of the femur consists of no less than seven pieces (Pl. X). The head of the bone is normal in shape, but is small. The neck of the femur is in a position of acute coxa vara, and is represented by two pieces of bone, as if there had been a fracture of the neck. On the under surface of the neck there is a thin plate of bone, and on the top of what is in all probability the great trochanter there are two other fragments.

The X ray shows a faint trace of ossification in the lower end of the fibula.

When the child stands the right knee is flexed almost to a right angle. There is dropping of the pelvis on the left side, slight lordosis, and left convex lateral lumbar curvature.

PLATE X.

Illustrating Mr. Openshaw's Case of Congenital Absence of the Fibula and Malformation of the Head of the Femur (Congenital Coxa Vara) simulating Congenital Dislocation of the Hip.

Bale and Danielsson, Ltd.

U of M

Bale and Danielsson, Ltd.

PLATE XI.

Illustrating Mr. Openshaw's Case of Double Coxa Vara (Ricketic) in a Boy æt. 12.

XXXVIII.—*A Case of Double Coxa Vara (Ricketic) in a Boy æt.* 12. By T. H. Openshaw, C.M.G. *Exhibited March* 23, 1906.

D. D., æt. 12. There is no family history of any similar condition; no history of accident or injury. Patient was suckled until thirteen months of age, and as a child the legs were rotated out and abducted. Marked genu varum and curved tibiæ were noticed at the age of eighteen months, with enlarged wrists, and fontanelles late in closing.

Except the coxa vara, there is no evidence of rickets at the present time.

Lordosis was first noticed about the age of five years.

Present condition.—There is extreme lordosis. The great trochanters are elevated and prominent. The legs are equal in length. The legs are markedly adducted and cannot be abducted. The boy walks with extreme waddling gait, the lumbar vertebral column being flexed laterally with each step.

The right leg measures 28 inches. The upper border of the great trochanter is on the same level as the anterior superior spine. Flexion is only possible 40°. The leg is adducted to an angle of 45°; abduction impossible; rotation out through an angle of 25°, and rotation in for 10° only. There is flexion of the right knee and valgus of the right ankle.

The left leg measures 28 inches. The upper border of the great trochanter is slightly above the level of the anterior superior spine. Flexion is possible only to an angle of 90°; adduction to 45°; abduction impossible; rotation out through an angle of 25°. The thigh cannot be rotated in beyond the position in which the patella looks directly forward. The left knee is in a position of varus, with prominence of the head of the fibula, and the left ankle is valgus.

An X ray picture of the femur on each side (Pl. XI) shows the head of the bone situated in the acetabulum, and well formed. The upper edge of the head would appear to be an inch and a half below the upper border of the great trochanter. The neck of the femur seems altogether wanting. There is a flattened surface at the root of the head, which would appear to rest against the inner surface of the great trochanter. The upper border of the great trochanter is

prolonged upwards and inwards, and impinges against the outer surface of the ilium, even when the femur is perpendicular, thus rendering abduction impossible. The angle made between the shaft of the femur and a line passing up along the upper border of the head and neck would appear to be about 60°, and is equal on the two sides.

Another X ray picture is exhibited, which was taken three years ago. In this condition the head of the bone is not nearly so much depressed, being only half an inch below the top of the great trochanter on either side, and there would appear to be a short thick neck to the femur. The angle made by the neck with the centre of the shaft of the femur would appear to have been 82° three years ago.

XXXIX.—*A Case of Left Traumatic Coxa Vara due to an Extra-capsular Fracture of the Neck of the Femur in a Boy æt.* 12. By T. H. Openshaw, C.M.G. *Exhibited March* 23, 1906.

F. S., æt. 12. On Christmas night he slipped on a stone and fell upon the great trochanter. He felt acute pain and was unable to stand. He was carried home and stayed in bed more or less for a fortnight. He then limped about for a week and came up to the hospital, where he was radiographed. The X ray showed a fracture of the femur, so he was admitted into the London Hospital, under my care, on January 15, 1906.

On admission the left leg was shortened one inch, and the left great trochanter was half an inch above Nelaton's line. Bryant's triangle was half an inch shorter than on the other side. There was some thickening about the great trochanter, but there was no evidence of old bruising.

From January 15 to March 7 a splint was applied to the leg, abducted at an angle of 45°. Since March 7 the leg has been in plaster-of-Paris.

The X ray shows a fracture at the outer extremity of the neck of the femur. There appears to have been no marked impaction. The upper edge of the head is level with the top of the great trochanter, and the angle formed by the neck with the shaft of the femur is 95°. The head of the bone is well shaped and normal as regards its epiphysial surface.

This case points to the possibility of many of the cases of coxa vara being traumatic in origin.

XL.—*Case of* (?) *von Recklinghausen's Disease.* By G. A. Sutherland, M.D. *Exhibited April* 27, 1906.

E. S., male, æt. 5. Parents Jews. Nothing in the family history save that his mother and maternal grandmother have spots of pigment on the body similar to those of patient.

Fig. 25.—Case of ? von Recklinghausen's disease.

At the age of six months a swelling the size of a bean was noticed on the right temple, and the right cheek and eye

appeared to be growing out of proportion to those on the left side. All these swellings have greatly increased, more rapidly so during the past few months. The child has suffered from rickets, and many bony deformities are present as the result.

Special features.—A swelling over the right frontal bone, firm and nodular. Right upper eyelid much hypertrophied and hanging over the eye; lower lid slightly hypertrophied. Right eye enlarged and apparently proptosed. Right cheek enlarged and contains nodular thickenings in its substance. Inside the mouth the tissues around the upper and lower jaws seem fuller than those on the left side. Pigmentation in varying shades of brown is present over the frontal swelling, the right upper eyelid, the trunk, the axillæ, and the groins. The extremities are practically free from pigmentation. Skiagrams show great enlargement of the orbit on the right side.

Negative features.—No evidence of visceral disease, save a trace of albumen in the urine. No pain or tenderness, nor evidence of central nervous disease.

XLI.—"*Spontaneous*" *Fracture in the Tarsus in a Woman with Argyll Robertson Pupils.* By F. Parkes Weber, M.D. *Exhibited April* 27, 1906.

THE patient is a married woman, æt. 45. About twelve months ago the right foot became swollen and painful. On admission to the hospital, March 14, 1906, there was great swelling of the right foot, especially of the dorsum, and bony crepitus could be felt. A Röntgen-ray photograph showed that a portion of the head of the astragalus, or of the scaphoid bone (Pl. XII), was displaced. On examination of the patient it was found that there were Argyll-Robertson pupils on both sides, the right pupil being the largest. Nothing of importance was discovered in the thorax or abdomen. The knee-jerks were present. Some evidence of indulgence in alcoholic drinks was obtained. No definite history of syphilis was, however, forthcoming, though the patient had had five miscarriages. Under rest in bed there has been great improvement in the condition of the

PLATE XII.

Illustrating Dr. Parkes Weber's Case of "Spontaneous" Fracture in the Tarsus in a Woman with Argyll-Robertson Pupils.

Bale and Danielsson, Ltd.

Digitized by Google

foot, but mercurial inunction has likewise been employed, followed by the internal use of iodide of potassium. Further examination has shown absence of Romberg's sign and absence of any ophthalmoscopic change. No tendo-Achillis reflex has, however, been obtained. (A Röntgen-ray photograph, kindly taken by Dr. G. H. Graham shortly after the case was exhibited, showed that it was the scaphoid bone, and not the head of the astragalus, which was at fault.)

XLII.—*Case of Ringworm Cured by the Exposure of X Rays.* By G. PERNET. *Exhibited April* 27, 1906.

MR. GEORGE PERNET showed a case of ringworm of the scalp treated by one sitting of the X rays, to show the good results. The boy, æt. 7, was first seen in October, 1905, with a patch of ringworm occupying the greater part of the occiput. On October 19, 1905, he had one exposure of the X rays, according to the Sabouraud-Noiré method (platino-cyanide of barium pastille). This was followed by the falling out of the stumps and hairs on parts exposed, followed by growth. The results had been excellent, the hair having grown well. No disease could be now made out on the part rayed.

XLIII. — *Lymphangiectodes.* By G. PERNET. *Exhibited April* 27, 1906.

MR. GEORGE PERNET showed a case of lymphangiectodes (lymphangioma circumscriptum) occurring in a young woman, æt. 26. The disease had commenced at the age of five months. When first seen by the exhibitor there were nine or ten groups of deep-seated vesicles occupying the right side of the chest from the neighbourhood of the

posterior axillary fold downwards and forwards, but not reaching as far as the right nipple line. The lowest and largest group was situated on a deeper-seated mass (lymph-angiectatic pachydermia of Rindfleisch), and some hæmorrhage had occurred into the vesicle-like lesions. The lesions were not so obviously marked as they were when first seen. The other children in the family were quite free. All, including the patient, were quite healthy. The majority of the cases hitherto described were of English nationality.

XLIV.—*A Case of Post-Auricular Fistula.* By W. H. Battle. *Exhibited April* 27, 1906.

THE patient, a girl æt. 11, was admitted to St. Thomas's Hospital on April 19, 1906, and is still under treatment.

There is a minute opening in the fold behind the right ear, half an inch above the level of the lobule, which only admits a small probe; from this there is an intermittent distillation of a clear fluid in sufficient quantity to necessitate the wearing of an absorbent dressing. There is no redness to indicate the orifice, which it is difficult to find when there is no flow of the fluid. The parotid gland is normal, and there is a normal flow of saliva into the mouth. The flow is not increased during meals, but is increased when an acid-drop is given or when the patient sucks a slice of lemon. The opening is in a small, hardly perceptible, linear cicatrix.

There is a history dating back to the time when she was a year old; at that time it is said that an abscess behind the ear was opened by a medical man, but no further particulars can be obtained. Sometimes the discharge has apparently ceased for a day or two, but recommences without any discomfort.

The general health is good.

Addendum.—The sinus was excised and the wound sutured, with complete success. Nothing abnormal was found at the operation.

XLV.—*Extensive Ulceration invading the Upper Jaw on both sides, with Partial Destruction of Alveolar Margin, and without Involvement of the Cheek.* By William Hy. Battle. *Exhibited April* 27, 1906.

A MAN, æt. 38, admitted to St. Thomas's Hospital, on April 24, 1906. Eighteen months ago the patient had some pain just between the nose and the left malar bone. There was some swelling. He went to a dentist, who gave him some stuff to rub over the place as the teeth were sound. The pain was not relieved, so he had the left lateral incisor tooth drawn. The dentist showed him the tooth, and told him it was quite sound, and said also that he should not have had it removed. About two months later there was a discharge from the socket of the tooth removed. He again went to the dentist asking him to pull out the canine tooth, but he refused, and gave him a mouth wash. The discharge continued, and the opening of the socket became larger, whilst the canine became loose, so he pulled it out himself; a piece of bone came away later. The opening continued to get larger, and for four months he has noticed enlarged glands in the neck. The disease then began to spread to the other side of the jaw, and the right premolar came out.

There is no history of carcinoma in the family. He has never had syphilis, whilst the teeth in the upper jaw have been good.

At the present time the man looks fairly well, but presents some puffiness of his cheeks on both sides, with slight tenderness on pressure. Inside the mouth on the left side the lateral incisor and canine have gone, and the central incisor is exposed in nearly all its length by the ulceration. Here there is a larger cavity replacing part of the alveolar border of the jaw, and extending into the antrum. The margin of the ulceration is somewhat indurated, but the bony alveolus is irregularly destroyed so that the palate can be readily moved up and down by slight pressure. Behind this cavity there is increased thickening of the alveolus and some of the teeth are loose, the sockets having been destroyed; towards the middle line the mucous membrane of the mouth under the lip is not destroyed, but beyond that there is a large destruction of the mucous membrane and alveolus beneath, making a cavity which is surrounded with a border

of ulceration and opens into the antrum. There is some swelling, ulceration, and tenderness on the lower jaw of the left side. From all the areas of ulceration there is a fœtid yellow discharge. The glands in the left submaxillary region are large but not tender. Enlarged glands can also be felt on the right side and in various parts of the neck.

His general condition is very fair, there being no evidence of other disease. It is probably an example of "boring," epithelioma of unusual extent, and slowness of growth.

The case may form the subject of another communication to the Society.

XLVI.—*A Patient after Operation for Perforation of a Second Simple Ulcer of the Jejunum into the General Peritoneal Cavity.* By WILLIAM HY. BATTLE. *Exhibited April* 27, 1906.

K. C., a single woman, æt 30, was admitted to St. Thomas's Hospital on March 14, 1906, for symptoms which she herself diagnosed as due to "perforation." She had not been feeling very well for a fortnight, but there had been nothing definite. There was, however, some pain in the abdomen on the 12th, which she could not localise. At 9 a.m. on the morning of admission there was a sudden increase of pain, which was now in the upper part of the abdomen, and she vomited.

At 3 p.m. she was lying on her back, with eyes slightly sunken, but not at all anxious-looking. Her pulse was 85 and temperature 100·6° F.

The abdomen was moving fairly on respiration. On examination it was tender, especially to the left of the umbilicus, and still more so near the lower end of the scar representing the site of the previous operation for a perforated intestinal ulcer, done in May, 1905. In that region the muscular rigidity was most marked, and there was distinct swelling. There was impaired resonance towards the left flank. No visible peristalsis. The liver dulness was not changed.

Incision was made through the left rectus sheath and the muscle displaced inwards. A thin, purulent fluid was

present on opening the peritoneum; and a coil of distended small intestine of a dull red colour, having some flakes of lymph, on its surface, was immediately under the opening. Two or three patches of yellow lymph were especially evident on the line of junction of the stomach and small intestine; one of these, of rounded shape, covered the ulcer, which had perforated, and the probe passed directly through it into the gut. It was about ⅛ inch below the line of junction, on the intestine, and about the size of a crow-quill. The tissues around it were indurated. Part of the edge was cut off for microscopical examination.

A transverse suture was put in to bring the edges together, and this was infolded with a row of Lembert sutures, all of silk. The pelvis was cleansed from purulent fluid and lymph through a second incision. After this both of the openings were closed without drainage. She left the hospital on April 12, having made a very satisfactory recovery.

Microscopical examination of the edge of the ulcer showed only an acute inflammation.

It is of interest to note that there were no adhesions found at this operation, also that there is now no hernial protrusion of any of the scars.

The previous history of this case is as follows: She was admitted to St. Thomas's Hospital in March, 1903, for perforated gastric ulcer. This ulcer was situated in the anterior aspect of the stomach, near the pylorus, and was surrounded by a good deal of thickening. It was sutured, the peritoneum cleansed, and a drainage-tube left in the lower wound.

Anterior gastro-enterostomy was performed on April 9, 1904, for pyloric stenosis.

On May 6, 1905, she underwent operation for perforation of a simple ulcer of the jejunum; this had given into the general peritoneal cavity. It was a circular, clean-cut ulcer, situated about 1½ inch from the line of junction of the bowel with the stomach. The ulcer was sutured, the peritoneum cleansed, and the two wounds through which this was done closed without drainage.

XLVII.—*Deformity of the Ulna, with Dislocation of the Head of the Radius associated with Multiple Osteomata.* By William Hy. Battle. *Exhibited April* 27, 1906.

A GIRL, æt. 15, admitted to St. Thomas's Hospital February 13, and discharged March 11, 1905.

Hard swellings were noticed over the elbow and wrist joints by the mother two years before admission. A year ago a similar swelling was noticed near the left knee; since that time several others have developed.

Hard osteomata of small size are found on nearly all the long bones near their terminal epiphyses: Ulna (R., lower end); radius (R., upper end); humerus (R., upper end); inner extremity of each second rib. Humerus (L., upper end) lower end of radius, L.; tibiæ (upper ends); femora (lower end); fibula (L., upper end).

The right forearm is deformed, and flexion limited to a right angle.

The ulna is shorter than that of the other side, right measuring six and a half inches, the left measuring nine inches; the radius (R.) measuring seven and a half inches, the radius (L.) measuring nine inches.

The shaft of the radius is bowed outwards, and the head of the bone displaced forwards and outwards.

February 24.—Excision of head of radius at level of lower part of neck. Articular surface shallow and somewhat irregular. There was a marked bony prominence growing from the anterior surface of the neck, and the circle of the capitellum was irregularly enlarged. The result has been to restore full mobility to the joint.

XLVIII.—*Extreme Obesity with Precocious Puberty in a Girl æt.* 3. By Leonard Guthrie, M.D. *Exhibited April* 27, 1906.

THE child has always been rather plump, but has been growing rapidly fatter during the past six months. Height 2 ft. 9½ in. Weight 37½ lbs. She has grown an

FIG. 26.—Extreme obesity in a girl æt. 3.

inch and increased 6 lbs. in weight in three months. The fat is fairly evenly distributed, and also exists in pads or rolls round the neck and about the chest and flanks. The features look small, and the temporal regions are masked owing to masses of fat in the cheeks.

Measurements.—Round neck, 12½ in.; chest, 25¼ in.; abdomen, 26½ in.; upper arm, 8 in.; lower arm, 7½ in.; thigh, 13¾ in.; calf, 8¼ in.

The breasts are beginning to develop, and hair has appeared on the pubes during the last three months.

Assimilation is poor, and the heart-sounds are weak. The pulse is usually intermittent and irregular, and averages 120 to 130 per minute.

Temperature is usually subnormal—97° to 98°.

Urine is normal.

Intelligence is good.

XLIX.—*Muscular Atrophy in a Child (case for Diagnosis).* By A. E. Garrod, M.D. *Exhibited April 27, 1906.*

THE patient is a girl, æt. 11, who exhibits somewhat extensive muscular atrophy and a condition of the limbs of the left side which is said to date from a paralytic attack at the age of one year, attributed to a fall. There is some affection of the facial muscles—fibrillary twitching around the left angle of the mouth, and a tendency for the right side of the mouth to be drawn down when the teeth are shown. The orbiculares oculorum are weak, and the left eye cannot be shut alone. In the attempt to whistle the right side of the mouth is not pursed up. The tongue is protruded straight. There is atrophy of the lower portions of both pectoral muscles and of the deltoids. The most extreme wasting is in the first dorsal interossei of both hands, which do not react at all either to the faradic or galvanic current. No other of the wasted muscles show any reaction of degeneration. There is some scoliosis and deformity of the thorax. The superficial reflexes are brisk. The right knee-jerk is rather more lively than the left. Babinski's sign is

obtained in the left foot. The left triceps jerk is well obtained. The left arm is small, and its muscles are generally wasted. There is conspicuous atrophy of the thumb muscles and interossei—*main en griffe.* The forearm is held in a position of extreme supination, and cannot be pronated. The patient cannot raise the left arm above the level of the shoulder. The left leg is an inch and a quarter shorter than the right, and there is *pes cavus.* The wasting is most pronounced in the muscles of the thigh.

L.—*A Case of Angeio-Neurotic Œdema.* By A. E. Garrod, M.D. *Exhibited April* 27, 1906.

THE patient is a young woman, æt. 20. At the age of fourteen she began to have recurrent attacks of acute circumscribed œdema of the right cheek. The attacks recurred at quite irregular intervals, which varied in length from three weeks to several months. They were more frequent in damp weather. They had no relation to the catamenial periods. The patch of œdema was always in the same position, on the right cheek. In some of the more severe attacks constitutional symptoms were present, such as shivering at the onset and "pains all over." There have been no articular troubles. The œdematous patches are not the seat of any burning sensation or itching, and there is no history of urticarial eruptions or erythema. Polyuria has been noticed to accompany the attacks. Three months ago a severe attack began in the usual situation, but the œdema extended to the nose, both eyelids, and the forehead. This attack also differed from all previous ones in the fact that, instead of subsiding in three days, the œdema has persisted up to the present time, and has not been influenced by treatment. The patient's urine yields a cloud of albumen with the heat-test, but there is no œdema elsewhere than in the face.

LI.—*Paralysis of Left Sixth and Paresis of Left Seventh Nerves.* By LEONARD GUTHRIE, M.D. *Exhibited April* 27, 1906.

PATIENT is a girl, æt. 3. About six weeks ago she was noticed to squint and to turn her head to the right side. She began to limp, and did not care to walk.

On admission to Paddington Green Children's Hospital, April 19, 1906, her condition was as at present, except that weakness of the left side of the face has become more marked.

Present condition.—A well-nourished child. The head is almost constantly inclined towards the right shoulder, her eyes twisting in the same direction, downwards, and to the right. When she looks towards the left side there is marked internal strabismus of left eye, but the right moves normally inwards. The left external rectus is paralysed, but no other ocular muscle is affected. Pupils are equal, reaction to light and accommodation normal. The left optic disc is hazy, but there is no optic neuritis. The whole of the left side of the face is paretic. The left eye cannot be closed, and the left side of the mouth moves less than the right when the child cries. Beneath the left zygoma there is a prominent swelling about the size of a five-shilling piece, slightly tender, ill defined and elastic, or indistinctly fluctuating on pressure. There is a pea-sized tuberculous nodule on the back of the right hand, said to have existed for three to four months. Mentally the child is dull and apathetic, never speaks, cries in a half-hearted way if examined, or spontaneously, but does not seem to be in pain.

Gait is slow, rather shuffling, and unsteady.

Knee-jerks are active.

Ankle-clonus absent.

Diagnosis.—Probably tuberculous disease of bone in malar region, involving left facial nerve externally and left sixth nerve internally. The deviation of the head is probably adopted to avoid diplopia.

LII.—*Fracture of the Neck of the Femur.* By C. J. Symonds, M.S.

NOTE on the later history of a man, named D. G. W., exhibited on April 22, 1904 (*Clin. Soc. Trans.*, vol. xxxvii, p. 257, 1904), with spontaneous fracture of the neck of the femur. The patient was admitted into Bethlem Hospital on March 31, 1905, as he had recently become very irritable, suspicious, and had threatened violence. On admission the pupils did not react to light. The knee-jerks were absent. There was no marked disorder of speech. He was looked upon as a case of tabes and general paralysis. He died on July 24, 1905. This later history, for which I am indebted to Dr. Craig, bears out the suggestion made when the man was exhibited that the condition of the joint was a neuropathic one.

INDEX.

PAGE

ABRAHAMS (Bertram, M.B.), case of sudden paralysis of the third cranial nerve 227, 236
——— case of adiposis dolorosa 237
——— sporadic case of Friedreich's disease (by J. G. Gibb, introduced by Bertram Abrahams, M.B.) 239
Abscess of appendix, with profuse hæmorrhages; recovery (J. D. Malcolm) 108
Adiposis dolorosa, case of (B. Abrahams, M.B.) 237
Alveolar margin, partial destruction of, in case of extensive ulceration invading upper jaw on both sides (W. H. Battle) 249
Amalgamation of London medical societies, resolution carried in favour of, at Special General Meeting li
Anastomosis (colo-colic) after complete removal of multilocular cystic tumour of pancreas (J. D. Malcolm) 175
Angeio-neurotic œdema, case of (A. E. Garrod, M.D.) 255
Angioma (plexiform) of hand and arm (H. M. Rigby) 230
Aorta (abdominal), thrombosis of (F. H. Hawkins, M.D.) . . 185
Appendicitis, due to *Oxyuris vermicularis*, two cases (H. W. Carson) 102
Appendix (abscess of), with profuse hæmorrhages; recovery (J. D. Malcolm) 108
Argyll-Robertson pupils in case of "spontaneous" fracture in tarsus (F. Parkes Weber, M.D.) 246
Arm and hand, plexiform angioma of (H. M. Rigby) 230
Artery (pulmonary), displacement of thrombus in main trunk of, apparently causing pulmonary embolism (C. R. Box, M.D.) . 189
Ascites, fixation of omentum for; case shown four years after (W. G. Spencer) 239
Atony (acute) of stomach and intestines (acute dilatation) connected with pneumonia and pleuro-pericarditis (F. Parkes Weber, M.D.) 205
Atrophy (muscular) in child: case for diagnosis (A. E. Garrod, M.D) 254

PAGE

BARKER (Arthur E.), Treitz's hernia complicating gastro-enterostomy 136
BATTLE (William Henry), a case of post-auricular fistula . . 248
——— extensive ulceration invading the upper jaw on both sides, with partial destruction of alveolar margin and without involvement of the cheek 249
——— a patient after operation for perforation of a second simple ulcer of the jejunum into the general peritoneal cavity . . 250
——— deformity of the ulna, with dislocation of the head of the radius, associated with multiple osteomata 252
BEEVOR (C. E., M.D.), perforating ulcers and joint changes, with only slight sensory changes 231
BERRY (James), congenital aperture in the centre of the palate . 222
Bile-duct (common), large cyst of (F. Eve) 144
Bladder (diseases of), diagnosis by cystoscope (D. Newman, M.D.) 1
——— tuberculosis in diverticulum of, found in inguinal hernia (E. M. Corner and C. W. Rowntree) 21
BOX (Charles R., M.D.), a series of cases in which pulmonary embolism appeared to be due to displacement of a thrombus in the main trunk of the pulmonary artery 189
Bradycardia, with obstruction of inferior vena cava in case of cardiac syphiloma; after-history and post-mortem record (C. W. Chapman, M.D.) 26
BUCKNALL (Rupert), a case of bilateral deformity of neck of the femur. 228
BUSCH, (J. P. ZUM, M.D.), mediastinal sarcoma which disappeared after treatment by the Röntgen rays 232
BUZZARD (E. Farquhar, M.D.), and CUNNING (Joseph), a case of post-traumatic hæmorrhage from the superior longitudinal sinus without fracture of the skull; operation and recovery . 123

Cæcum (volvulus of), case of (J. Sherren) 100
Calcareous, mortar-like fluid in pleura (S. West, M.D.). . . . 42
Cancer of stomach, operations for: review of fifty-nine cases (B. G. A. Moynihan). 84
Carcinoma of thyroid gland (A. E. Hudson, M.D.). 164
CARR (J. Walter, M.D.), a case of amyotrophic lateral sclerosis . 224
CARSON (H. W.), two cases of appendicitis due to oxyuris vermicularis 102
CHAPMAN (Charles W., M.D.), the after-history and post-mortem record of a case of cardiac syphiloma, with bradycardia and obstruction of the inferior vena cava 26

PAGE
Charcot's disease of thumb (P. M. Heath) 225
Cheek not involved in extensive ulceration invading upper jaw, with partial destruction of alveolar margin (W. H. Battle) . 249
Childhood: extreme obesity with precocious puberty in (L. G. Guthrie, M.D.) 252
——— muscular atrophy in (A. E. Garrod, M.D) 254
CLARKE (J. Jackson), the present position of the treatment of congenital dislocation of the hip-joint, illustrated by an account of the results in two series, each of ten consecutive cases 53
Colo-colic anastomosis after complete removal of multilocular cystic tumour of pancreas (J. D. Malcolm) 175
Colotomy (transverse), *versus* iliac colotomy: notes of three cases (L. H. McGavin) 69
Congenital absence of fibula and malformation of head of femur (congenital coxa vara) simulating congenital dislocation of hip (T. H. Openshaw, C.M.G.) 241
——— aperture in centre of palate (J. Berry) 222
——— malformations (associated) including transposition of viscera (A. E. Garrod, M.D., and F. Langmead, M.D.) . . 131
CORNER (Edred M.), cases of recovery, without spinal symptoms, after severe injury to the neck 212
——— and PINCHES (H. Irving), further cases of torsion of the omentum 79
——— and ROWNTREE (Cecil W.), a case of tuberculosis in a diverticulum of the bladder found in an inguinal hernia . . 21
Council: list of Officers and Council (1906—1907) xix
——— Report of the Council (1906) li
Coxa vara (congenital), with congenital absence of fibula, simulating congenital dislocation of hip (T. H. Openshaw, C.M.G.) 241
——— (ricketic, double) (T. H. Openshaw, C.M.G.) . . . 243
——— (traumatic, left), due to extra-capsular fracture of neck of femur (T. H. Openshaw, C.M.G.) 244
CUNNING (Joseph) and BUZZARD (E. Farquhar, M.D.), a case of post-traumatic hæmorrhage from the superior longitudinal sinus without fracture of the skull: operation and recovery . 123
Cyst (large) of common bile-duct (F. Eve) 144
——— see also *Pseudo-cyst.*
Cystic tumour (multilocular) of pancreas; complete removal (J. D. Malcolm) 175
——— of spermatic cord (C. S. Wallace). 157
Cystoscope in diagnoses of disease of bladder and kidneys (D. Newman, M.D.). 1

PAGE
Dermoid (mediastinal) (G. E. O. Williams) 210
Diabetes insipidus (traumatic), relation to glycosuria (H. French, M.D., and C. B. Ticehurst) 117
Diagnosis, case for: muscular atrophy in a child (A. E. Garrod, M.D.) 254
Dilatation of stomach, unusual case following hour-glass contraction (J. E. Spicer) 127
——— (acute) of stomach and intestines (acute atony) connected with pneumonia and pleuro-pericarditis (F. Parkes Weber, M.D.) 205
Dislocation (congenital, of hip-joint) simulated by case of congenital absence of fibula and malformation of head of femur (congenital coxa vara) (T. H. Openshaw, C.M.G.) . . . 241
——— ——— ——— treatment: present position (J. Jackson Clarke) 53
——— of metatarsus (C. A. R. Nitch) 237 (J. J. Douglas, M.D.). 238
——— of head of radius, with deformity of ulna, associated with multiple osteomata (W. H. Battle) 252
Diverticulum of bladder found in inguinal hernia, tuberculosis in (E. M. Corner and C. W. Rowntree) 21
Douglas (John J., M.D.), dislocation of metatarsus . . . 238
Dudgeon (Leonard S.), carcinoma of the thyroid gland, by A. C. Hudson, M.D. (introduced by Mr. L. S. Dudgeon) . 164
Duodenal hernia: see *Hernia* (duodenal).

Ear: case of post-auricular fistula (W. H. Battle). . . . 248
Embolism (pulmonary), apparently due to displacement of thrombus in main trunk of pulmonary artery: series of cases (C. R. Box, M.D.) 189
Epithelioma; conversion of cases into epithelioma, originally lupus, after repeated surgical and prolonged X-ray treatment (W. G. Spencer) 215
——— of lip (L. H. McGavin) 216
Eve (Frederic), large cyst of common bile-duct 144
Evisceration and irrigation successful in treatment of case of perforated gastric ulcer (E. W. Roughton) 173
Eyelid: rodent ulcer of scalp, face, and inner canthus of eyelid, treated by X rays (L. H. McGavin) 217

Face, scalp, and inner canthus of eyelid, rodent ulcer of; treated by X rays (L. H. McGavin) 217
Femur (head of), malformation: see *Coxa vara*, congenital.
——— (neck of), bilateral deformity of (R. Bucknall) . . . 228

PAGE
Femur (neck of), fracture, extra-capsular (T. H. Openshaw, C.M.G.) 244
——— ——— fracture of (C. J. Symonds) 257
Fibula (congenital absence of) with malformation of head of femur simulating congenital dislocation of hip (T. H. Openshaw, C.M.G.) 241
Fistula (post-auricular), case of (W. H. Battle) 248
Forehead: osteo-sarcoma of frontal bone (T. H. Kellock) . . 228
Fracture of neck of femur (C. J. Symonds) 257
——— ——— (extra-capsular) causing coxa vara (T. H. Openshaw, C.M.G.) 244
——— (spontaneous) in tarsus in woman with Argyll Robertson pupils (F. Parkes Weber, M.D.) 246
FRENCH (Herbert, M.D.) and TICEHURST (C. B.), a note upon the relation of traumatic diabetes insipidus to glycosuria . . 117
Friedreich's disease (sporadic) (J. G. Gibb) 239
Frontal bone: osteo-sarcoma of (R. Bucknall) 228

GARROD (A. E., M.D.), a case of relapsing tetany associated with dilatation of the sigmoid flexure, by F. Langmead, M.D. (introduced by A. E. Garrod, M.D.) 48
——— peculiar pigmentation of skin in an infant. . . . 216
——— muscular atrophy in a child (case for diagnosis) . . 254
——— a case of angeio-neurotic œdema 255
——— and LANGMEAD (F., M.D.), a case of associated congenital malformation, including transposition of viscera . . . 131
Gastric ulcer (perforated) treated by evisceration and irrigation; recovery (E. W. Roughton) 173
Gastro-enterostomy complicated by Treitz's hernia (A. E. Barker) 136
Gastro-intestinal disorder associated with tetany, apparently cured by use of thyroid substance (H. T. Mant and H. Batty Shaw, M.D.) 229
Gastro-jejunostomy, three cases of (F. C. Wallis) 157
GIBB (J. G.), sporadic case of Friedreich's disease (introduced by Bertram Abrahams, M.B.) 239
Glycosuria: relation of traumatic diabetes insipidus to (H. French, M.D., and C. B. Ticehurst) 117
GOODALL (E. W., M.D.), a case of typhoid fever with peritonitis but no perforation in which laparotomy was performed . 55
GUTHRIE (Leonard G., M.D.), extreme obesity with precocious puberty in a girl æt. 3 252
——— paralysis of left sixth and paresis of left seventh nerves . 256

PAGE

Hæmorrhage (post-traumatic) from superior longitudinal sinus without fracture of skull (E. F. Buzzard, M.D., and J. Cunning) 123
Hæmorrhages (profuse) in case of appendix abscess (J. D. Malcolm) 108
Hand and arm, plexiform angioma of (H. M. Rigby) . . . 230
HAWKINS (Francis H., M.D.), case of suppurative pylephlebitis associated with suppurating mesenteric gland . . . 30
——— case of thrombosis of the abdominal aorta 185
Heart (syphiloma of), case with bradycardia and obstruction of inferior vena cava; after-history and post-mortem record (C. W. Chapman, M.D.) 26
HEATH (P. Maynard), Charcot's disease of the thumb . . . 225
Hemiplegia (functional?) disseminated sclerosis in boy, æt. $9\frac{8}{12}$ (A. F. Voelcker, M.D.) 241
Hernia (duodenal, left) strangulated, case of (J. Sherren) . . 98
——— ——— (right) reduction; death in seven days, due apparently to gut re-entering sac (E. Percy Paton) . . 139
——— (inguinal) tuberculosis in diverticulum of bladder found in (E. M. Corner and C. W. Rowntree) 21
——— (Treitz's) complicating gastro-enterostomy (A. E. Barker) 136
HERRINGHAM (W. P., M.D.), a case of transverse myelitis with loss of knee-jerks; recovery 225
Hip-joint (dislocation, congenital) simulated by case of congenital absence of fibula and malformation of head of femur (congenital coxa vara) (T. H. Openshaw, C.M.G.) 241
——— ——— ——— treatment; present position (J. Jackson Clarke) 53
Hour-glass contraction followed by unusual dilatation of stomach (J. E. Spicer) 127
HUDSON (A. C., M.D.), carcinoma of the thyroid gland (introduced by Mr. L. S. Dudgeon) 164

Iliac colotomy: see *Colotomy* (iliac).
Infant, peculiar pigmentation of skin in (A. E. Garrod, M.D.) . 216
——— (Japanese), showing congenital pigmentation of Mongolians (G. A. Sutherland, M.D.) 214
Insane, general paralysis of, in a boy æt. 16 (?) (J. R. Lunn) . 219
Intestine (small), stricture of, causing acute intestinal obstruction (J. Sherren) 96
——— dilatation, acute, of stomach and intestines connected with pneumonia and pleuro-pericarditis (F. Parkes Weber, M.D.) 205

PAGE

Irrigation: evisceration and irrigation successful in treatment of case of perforated gastric ulcer (E. W. Roughton) . . . 173

Japanese infant, showing congenital pigmentation of Mongolians (G. A. Sutherland, M.D.) 214
Jaw (upper) invaded on both sides by extensive ulceration; partial destruction of alveolar margin; cheek not involved (W. H. Battle) 249
Jejunum (ulcer of), perforation of second simple ulcer into general peritoneal cavity; operation; patient exhibited (W. H. Battle) 250
Joints: perforating ulcers and joint changes with only slight sensory changes (C. E. Beevor, M.D.) 231
——— see also *Hip-joint.*

Kellock (Thomas H.), a case of traumatic pancreatic pseudo-cyst 63
——— case of osteo-sarcoma of frontal bone 228
Kidd (Percy, M.D.), an unusual case of dilatation of the stomach following hour-glass contraction (by John Evan Spicer, M.B., introduced by Percy Kidd, M D.) 127
Kidney (diseases of), diagnosis by cystoscope (D. Newman, M.D.). 1
Knee-jerks, loss of, in transverse myelitis (W. P. Herringham, M.D.) 225

Laminectomy for traumatic paraplegia (L. H. McGavin) . . 221
Langmead (F., M.D.), on a case of relapsing tetany associated with dilatation of the sigmoid flexure (introduced by A. E. Garrod, M.D.) 48
——— and Garrod (A. E., M.D.), a case of associated congenital malformations, including transposition of viscera . . . 131
Laparotomy for peritonitis occurring without perforation in typhoid fever (E. W. Goodall, M.D.) 55, (W. G. Spencer) . 59
Leukæmia, spleno-medullary, (A. F. Voelcker, M.D.) . . . 240
Lip, epithelioma of (L. H. McGavin) 216
Lipomas, multiple (H. D. Rolleston, M.D.) 218
Longitudinal sinus: post-traumatic hæmorrhage from, without fracture of skull; operation; recovery (E. F. Buzzard, M.D., and J. Cunning) 123
Lunn (John R.), case of general paralysis of the insane in a boy æt. 16 (?) 219
——— a case of myasthenia gravis? 219
——— a case of molluscum fibrosum 220
Lupus (cases of) becoming epithelioma after repeated surgical and prolonged X-ray treatment (W. G. Spencer) . . . 215
Lymphangiectodes, case of (G. Pernet) 247

PAGE

McGAVIN (Lawrie H,), transverse *versus* iliac colostomy, with notes of three cases 69
——— epithelioma of the lip in a man æt. 44 216
——— rodent ulcer of the scalp, face, and inner canthus of the eyelid; treated by application of X rays. 217
——— a case of laminectomy for traumatic paraplegia . . 221
MALCOLM (John David), a case of appendix abscess with profuse hæmorrhages; recovery 108
——— a case of complete removal of multilocular cystic tumour of the pancreas, colo-colic anastomosis sixteen days later; recovery 175
Malformations (congenital, associated) including transposition of viscera (A. E. Garrod, M.D., and F. Langmead, M.D.) . . 131
MANT (H. T.) and SHAW (H. Batty, M.D.), tetany of seven months' duration associated with gastro-intestinal disorders in a girl æt. 9 apparently cured by the use of thyroid substance. . 229
Mediastinum (dermoid of) (G. E. O. Williams) 210
——— (sarcoma of) disappearing after treatment by Röntgen rays (J. P. zum Busch, M.D.) 232
Meeting (Special General): see *Special* General Meeting . . li
Members of the Society, Honorary xxi
——— Honorary, Foreign xxii
——— Ordinary . . . . . xxiii–l
Mesenteric gland (suppurating), suppurative pylephlebitis associated with (F. H. Hawkins, M.D.) 30
Metatarsus, dislocation of (J. J. Douglas, M.D.) 238
——— ——— (C. A. R. Nitch) 237
Molluscum fibrosum, case of (J. R. Lunn) 220
Mongolians, Japanese infant showing congenital pigmentation of (G. A. Sutherland, M.D.) 214
MOON (R. O., M.D.), Stokes-Adams' disease 214
Mortar-like, calcareous fluid in pleura (S. West, M.D.) . . . 42
MOYNIHAN (B. G. A.), a review of fifty-nine cases of cancer of the stomach treated by operation 84
Muscles (atrophy of) in child: case for diagnosis (A. E. Garrod, M.D.). 254
Myasthenia gravis?, case of (J. R. Lunn) 219
Myelæmia (spleno-medullary leukæmia) (A. F. Voelcker, M.D.) . 240
Myelitis (transverse) with loss of knee-jerks (W. P. Herringham, M.D.). 225

Nævus (cavernous) of tongue (Hugh M. Rigby) 230

PAGE

Neck (injuries): cases of recovery, without spinal symptoms, after severe injury to (E. M. Corner) 212
Nerve (left sixth), paralysis of, with paresis of left seventh (L. G. Guthrie, M.D.) 256
——— (third cranial), sudden paralysis of (B. Abrahams, M.B.) 227, 236
NEWMAN (David, M.D.), the cystoscope in diagnoses of diseases of the bladder and kidneys; lesions illustrated by an opaque projector 1
NITCH (Cyril A. R.), dislocation of metatarsus 237
Nose: submucous resection of deviations and spurs in the nasal septum (StClair Thomson, M.D.) 211

Obesity (extreme), with precocious puberty in a girl æt. 3 (L. G. Guthrie, M.D.) 252
Obstruction (intestinal, acute) due to stricture of small intestine (J. Sherren) 96
Œdema (angeio-neurotic), case of (A. E. Garrod, M.D.). . . 255
Omentum (torsion of), further cases (H. Irving Pinches and E. M. Corner) 79
——— (fixation of) for ascites; case shown four years after (W. G. Spencer). 239
OPENSHAW (T. H., C. M. G.), a case of congenital absence of the fibula and malformation of the head of the femur (congenital coxa vara) simulating congenital dislocation of the hip . . 238
——— a case of double coxa vara (ricketic) in a boy æt. 12 . . 243
——— a case of left traumatic coxa vara due to an extra-capsular fracture of the neck of the femur in a boy æt. 12 . . . 244
Osteomata (multiple), associated with deformity of ulna and dislocation of head of radius (W. H. Battle). 252
Osteo-sarcoma of frontal bone (T. H. Kellock) 228
Oxyuris vermicularis causing appendicitis in two cases (H. W. Carson) 102

Palate, congenital aperture in centre of (J. Berry). 222
Pancreas, pseudo-cyst of, traumatic (T. H. Kellock) 63
——— tumour of, cystic, multilocular; complete removal; colo-colic anastomosis; recovery (J. D. Malcolm) 175
Paralysis of left sixth and paresis of left seventh nerve (L. G. Guthrie, M.D.) 256
——— (sudden) of third cranial nerve (B. Abrahams, M.B.). 227, 236
——— (general) of insane in boy æt. 16 (?) (J. R. Lunn) . . 219

PAGE
Paraplegia (traumatic), laminectomy for (L. H. McGavin) . . 221
Paresis of left seventh and paralysis of left sixth nerve (L. G. Guthrie, M.D.) 256
PATON (E. Percy), a case of right duodenal hernia in which the hernia was reduced, but death followed in seven days, due apparently to gut re-entering the sac 139
Perforation (intestinal) absent in cases of typhoid fever with peritonitis (E. W. Goodall, M.D.), 55 (W. G. Spencer) . . . 59
——— of second simple ulcer of jejunum into general peritoneal cavity; operation; patient exhibited (W. H. Battle) . . 250
Pericarditis: see *Pleuro-pericarditis.*
Periodic respiration (S. West, M.D.) 46
Peritonitis occurring without perforation in typhoid fever (E. W. Goodall, M.D.) 55
PERNET (George), case of ringworm cured by the exposure of X rays 247
——— lymphangiectodes 247
Pigmentation (congenital) of Mongolians, Japanese infant showing (G. A. Sutherland, M.D.) 214
——— (peculiar) of skin in an infant (A. E. Garrod, M.D.) . . 216
PINCHES (H. Irving) and CORNER (Edred M.), further cases of torsion of the omentum 79
Pleura: calcareous, mortar-like fluid in (S. West, M.D.). . . 42
Pleuro-pericarditis: acute dilatation of stomach and intestines connected with pneumonia and pleuro-pericarditis (F. Parkes Weber, M.D.) 205
Pneumonia: acute dilatation of stomach and intestines connected with pneumonia and pleuro-pericarditis (F. Parkes Weber, M.D.). 205
Post-auricular fistula, case of (W. H. Battle) 248
Post-traumatic hæmorrhage from superior longitudinal sinus without fracture of skull (E. F. Buzzard, M.D., and J. Cunning) 123
Presidents of the Society since its formation, list of . . . xx
Pseudo-cyst (traumatic) of pancreas (T. H. Kellock) . . . 63
Puberty (precocious) with extreme obesity in a girl æt. 3 (L. G. Guthrie, M.D.) 252
Pupils: see *Argyll Robertson* pupils.
Pylephlebitis (suppurative) associated with suppurating mesenteric gland (F. H. Hawkins, M.D.) 30

Rachitis, case of double coxa vara due to (T. H. Openshaw, C.M.G.) 243

PAGE

Radius: dislocation of head of, with deformity of ulna, associated with multiple osteomata (W. H. Battle) 252
von Recklinghausen's disease, ? case of (G. A. Sutherland, M.D.) 245
Respiration (periodic) (S. West, M.D.) 46
RIGBY (Hugh M.), plexiform angioma of the hand and arm . . 230
——— cavernous nævus of the tongue 230
Ringworm, treatment by exposure of X rays; recovery (G. Pernet) 247
Rodent ulcer of scalp, face, and inner canthus of eyelid treated by X rays (L. McGavin) 217
Roentgen rays: cases of lupus after repeated surgical and prolonged X-ray treatment becoming epithelioma (W. G. Spencer). 215
——— exposure of, successful in case of ringworm (G. Pernet) . 247
——— in treatment of mediastinal sarcoma (J. P. zum Busch, M.D.) 232
——— ——— of rodent ulcer of scalp, face, and inner canthus of eyelid (L. H. McGavin) 217
ROLLESTON (H. D., M.D.), multiple lipomas 218
ROUGHTON (E. W.), case of perforated gastric ulcer treated by evisceration and irrigation; recovery 173
ROWNTREE (Cecil W.) and CORNER (Edred M.), a case of tuberculosis in a diverticulum of the bladder found in an inguinal hernia 21

Sarcoma (mediastinal), which disappeared after treatment by Röntgen rays (J. P. zum Busch) 232
Scalp, face, and inner canthus of eyelid, rodent ulcer of, treated by X rays (L. H. McGavin) 217
Sclerosis (amyotrophic lateral) (J. W. Carr, M.D.). 224
? Sclerosis (disseminated): case of functional hemiplegia in boy æt. $9\frac{8}{12}$ (A. F. Voelcker, M.D.) 241
Sensory changes, slight, in case of perforating ulcers, with joint changes (C. E. Beevor, M.D.) 231
Septum (nasal), submucous resection of deviations and spurs in (StClair Thomson, M.D.) 211
Shaking head or spasmus nutans (C. H. Thompson, M.D.) . . 223
SHAW (H. Batty, M.D.), and MANT (H. T.), tetany of seven months' duration, associated with gastro-intestinal disorder in a girl æt. 9, apparently cured by the use of thyroid substance. . 229
SHERREN (James), stricture of the small intestine, causing acute intestinal obstruction 96

PAGE

SHERREN (James), a case of strangulated left duodenal hernia . 98
——— a case of volvulus of the cæcum 100
Sigmoid flexure (dilatation of), relapsing tetany associated with (F. Langmead, M.D.). 48
SIMPSON (Graham), a successful case of splenectomy for rupture of the spleen, with remarks on the diagnosis and treatment of this accident 33
Skin, peculiar pigmentation of, in an infant (A. E. Garrod, M.D.). 216
Skull, bony tumour of (H. G. Turney, M.D.) 235
Spasmus nutans or shaking head (C. H. Thompson, M.D.) . . 223
Special General Meeting, resolution carried at, in favour of amalgamation of London medical societies li
SPENCER (Walter G.), septic peritonitis occurring early in the course of typhoid fever apart from perforation (with a temperature-chart) 59
——— cases of lupus becoming epithelioma after repeated surgical and prolonged X ray treatment 215
——— case four years after fixation of omentum for ascites . . 239
Spermatic cord, cystic tumour of (C. S. Wallace) 157
SPICER (John Evan), an unusual case of dilatation of the stomach following hour-glass contraction (introduced by Percy Kidd, M.D.) 127
Spinal symptoms, cases of recovery without, after severe injury to neck (E. M. Corner) 212
Spleen (rupture of): diagnosis and treatment (G. Simpson) . . 33
Splenectomy: successful case for rupture of spleen (G. Simpson) . 33
Spleno-medullary leukæmia (myelæmia) (A. F. Voelcker, M.D.) . 240
Spurs and deviations in nasal septum, submucous resection of (StClair Thomson, M.D.) 211
Stokes-Adams' disease (R. O. Moon, M.D.) 214
Stomach (cancer of), operation for; review of 59 cases (B. G. A. Moynihan). 84
——— (dilatation of): unusual case following hour-glass contraction (J. E. Spicer) 127
——— dilatation, acute, of stomach and intestines connected with pneumonia and pleuro-pericarditis (F. Parkes Weber, M.D.). 205
Stricture of small intestine causing acute intestinal obstruction (J. Sherren) 96
Submucous resection of deviations and spurs in the nasal septum (StClair Thomson, M.D.) 211
Suppurative pylephlebitis associated with suppurating mesenteric gland (F. H. Hawkins, M.D.) 30

PAGE

SUTHERLAND (G. A., M.D.), a Japanese infant, showing the congenital pigmentation of Mongolians. 214
——— case of (?) von Recklinghausen's disease 245
SYMONDS (C. J.), fracture of the neck of the femur 257
Syphiloma (cardiac): case with bradycardia and obstruction of inferior vena cava; after-history and *post-mortem* record (C. W. Chapman, M.D.) 26

Tarsus: "spontaneous" fracture in tarsus in woman with Argyll Robertson pupils (F. Parkes Weber, M.D.) 246
Tetany of seven months' duration associated with gastro-intestinal disorder apparently cured by use of thyroid substance (H. T. Mant and H. Batty Shaw, M.D.) 229
——— (relapsing) associated with dilatation of sigmoid flexure (F. Langmead, M.D.) 48
THOMPSON (C. H., M.D.), case of shaking head or spasmus nutans 223
THOMSON (StClair, M.D.), three cases of submucous excision of deviations and spurs in the nasal septum 211
Thrombosis of abdominal aorta (F. H. Hawkins, M.D.) . . 185
Thrombus (displacement of) in main trunk of pulmonary artery apparently causing pulmonary embolism (C. R. Box, M.D.) . 189
Thumb, Charcot's disease of (P. Maynard Heath) 222
Thyroid gland, carcinoma of (A. C. Hudson, M.D.) 164
Thyroid substance, apparently curing tetany associated with gastro-intestinal disorder (H. T. Mant and H. Batty Shaw, M.D.) 229
TICEHURST (C. B.) and FRENCH (Herbert, M.D.), a note upon the relation of traumatic diabetes insipidus to glycosuria . 117
Tongue, cavernous nævus of (H. M. Rigby) 230
Torsion of omentum, further cases (H. Irving Pinches and E. M. Corner) 79
Traumatic diabetes insipidus, relation to glycosuria (H. French, M.D., and C. B. Ticehurst) 117
——— paraplegia, laminectomy for (L. H. McGavin) . . . 221
——— pseudo-cyst of pancreas (T. H. Kellock) 63
Treasurer's Statement of Receipts and Payments (1905–6) . . lii
Treitz's hernia: see *Hernia* (Treitz's).
Tuberculosis in diverticulum of bladder found in inguinal hernia (E. M. Corner and C. W. Rowntree) 21
Tumour (bony) of skull (H. G. Turney, M.D.) 235
——— (cystic) of spermatic cord (C. S. Wallace) 157
——— ——— multilocular) of pancreas (J. D. Malcolm) . . 175